Chapter 17

SUPERFICIAL FUNGAL SKIN DISEASES

JAMES E. FITZPATRICK, M.D.*

INTRODUCTION

MILITARY HISTORY AND EPIDEMIOLOGY

DERMATOPHYTOSIS
- Clinical Features
- Diagnosis
- Treatment

CANDIDOSIS
- Clinical Features
- Diagnosis
- Treatment

PITYROSPORUM INFECTIONS
- Clinical Features
- Diagnosis
- Treatment

MISCELLANEOUS FUNGAL INFECTIONS

SUMMARY

Colonel, Medical Corps, U.S. Army; Chief, Dermatology Service, Fitzsimons Army Medical Center, Aurora, Colorado 80045-5001

INTRODUCTION

In years past, *fungi* (including molds) were classified as a subdivision of the plant kingdom. Taxonomists have recently acknowledged that fungi lack important features of plants (eg, chlorophyll and differentiation into roots, stems, and leaves) and therefore merit inclusion in the new kingdom, Mycota. This large and diverse kingdom comprises more than 100,000 recognized species. Of this large group, only about 300 species have been identified as human pathogens; however, more than three fourths of these pathogens infect primarily the skin or subcutaneous tissues.

Fungi can be characterized as aerobic, heterophilic (ie, they require exogenous carbon sources), eukaryotic (ie, the nucleus is organized, with associated subcellular structures), achlorophyllous organisms that reproduce by sexual or asexual or both means. Their size and form are highly variable: they can be unicellular and microscopic (eg, yeast) or multicellular and large (eg, mushrooms). The cellular membranes of fungi contain ergosterol and zymosterol, in contrast to mammalian cellular membranes, which possess cholesterol as their primary sterol. This is an important distinction because many of the drugs used to treat fungi (eg, imidazoles and allylamines) primarily inhibit ergosterol synthesis, and thus minimally affect the human host.

Fungal infections can be divided into four broad groups: superficial, localized subcutaneous, systemic, and opportunistic. The superficial fungal infections, which are the subject of this chapter, include those that attack the epidermis, mucosa, nails, and hair. While *dermatophytes* are the most common cause of superficial infections of the skin and its appendages, many *nondermatophytes* can also produce superficial infections (Exhibit 17-1). By convention, dermatophytes are defined as fungi that can utilize keratin as a substrate for growth, while nondermatophytes use other substrates (eg, lipids).[1] This distinction is somewhat artificial, however, as the nutritional requirements have not been clearly established for all species.

EXHIBIT 17-1

FUNGI CAUSING SUPERFICIAL CUTANEOUS INFECTIONS

Dermatophytes
- *Epidermophyton floccosum*
- *Microsporum* species
- *Trichophyton* species

Nondermatophytes
- *Candida* species
- *Pityrosporum orbiculare* (*Malassezia furfur*)
- *Exophiala werneckii*
- *Piedraia hortae*
- *Trichosporon beigelii*
- *Hendersonula toruloidea*
- *Scopulariopsis brevicaulis*

Superficial fungal infections are most commonly acquired from other humans (the anthropophilic species) but may also be acquired from soil (the geophilic species) and animals (the zoophilic species). This point is important for medical officers to remember because soldiers in combat are more likely to be exposed to and become infected with fungi that inhabit the soil and infest wild animals.

Although most superficial fungal diseases are trivial, when they infect military personnel the morbidity associated with these infections and their potential effects on military campaigns cannot be overemphasized.[1]

MILITARY HISTORY AND EPIDEMIOLOGY

Historically, superficial fungal infections have produced minimal disease in temperate climates such as seen in European theaters of combat. The most severe outbreaks are generally associated with tropical climates and exposure to new strains of fungi.

The medical report on skin diseases encountered during World War I in the British Royal Army states that only 25 of 8,313 (0.3%) cases admitted to a single general hospital for skin diseases over an 8-mo period were for "ringworm."[2] This figure is surprisingly low and invites speculation that some cases might have been misdiagnosed as inflammatory skin conditions.

The U.S. Army Medical Department's official history of medicine during World War II[3] reported data for the continental United States as well as for different combat theaters. For example, only 6% of soldiers seen for skin disease at Fort Lee, Virginia, were seen for superficial fungal infections. As might be expected, the incidence of these infections was not strikingly different for the European theater of operations, but warmer climates were associated with higher attack rates. Of combat soldiers seen for skin disease in the Mediterranean theater, up to 22% had diseases that were attributable to dermatophytic infections. As expected, rear-echelon troops experienced a much lower rate of infection. In a study of the British Royal Army in Southeast Asia, investigators methodically examined the skin of both European and Southeast Asian troops stationed in the Far East. They noted that 34% of European soldiers had a tinea infection, while only 7% of the Southeast Asian troops had similar infections.[4] Besides the high attack rate, the European soldiers demonstrated widely disseminated or "florid" disease when compared to the types of dermatophytic infections normally seen in the United Kingdom.

The Vietnam conflict provides the best data on the impact of superficial fungal infections on military operations in a tropical climate. Skin diseases were the most common cause of outpatient visits during the war, accounting for 12.2% of visits, and superficial fungal infections were the most common skin disease. In one dermatology clinic, superficial fungal infections accounted for 12.3% of visits; the most common types were dermatophytosis, pityriasis versicolor, and candidosis.[5] The effect on combat troops in the forward areas was even more dramatic: of 142 soldiers in the Mekong Delta who were studied as they came in for their noonday meals, 86 had "significant" dermatophytosis—an incidence of 65%.[6] Lieutenant Colonel Alfred M. Allen, in his seminal book on the skin diseases seen during the Vietnam conflict, states:

> Superficial fungal infections were the most common and troublesome of all the dermatologic conditions that occurred among U.S. forces in Vietnam. Hardly anyone escaped some form of mycotic skin infection during his tour of duty in Vietnam, and a large majority of ground combat troops in wet, lowland areas developed extensive inflammatory lesions that led to high rates of disability.[5(p59)]

Although most superficial fungal infections merely produced discomfort and large numbers of outpatient visits, significant numbers of soldiers were hospitalized for dermatophytosis or its secondary complications. During a 1-year period, the 17th Field Hospital in Saigon reported 25 admissions related to dermatophytosis; this accounted for 7% of all admissions for skin conditions. Most cases were successfully managed in Vietnam; even so, dermatophytosis caused 127 soldiers to be medically evacuated to the continental United States from 1965 to 1970.[5]

Accurate figures regarding the current incidence of superficial cutaneous fungal infections in soldiers stationed in the Zone of Interior during peacetime are not available. They would be expected to parallel those of the civilian population when corrected for age, sex, and geographical location. In the best study done to date, investigators examined and cultured 152 healthy air force recruits in Texas and demonstrated that 12.5% were infected with dermatophytes. In general, the degree of infection was not as severe as that were seen in Vietnam.[7]

DERMATOPHYTOSIS

Dermatophytic infections can be organized and studied either according to their etiology (Exhibit 17-2) or their clinical presentation (Table 17-1). Because the etiology is usually important only in epidemiological studies, this chapter is organized by clinical presentation. The field of dermatology has, unfortunately, used different Latin names to designate infections by the clinical appearance and site of involvement. The plethora of terms produced is confusing to patients and physicians alike, but the names are too ingrained in the medical literature to change.

Clinical Features

The clinical presentation of dermatophyte infections depends on several factors including the site of infection, the species of fungus, and the host's response. Because dermatophytes utilize keratin for a substrate, they infect areas of the body with abundant keratin such as the stratum corneum of the skin, hair, and nails. With rare exceptions, dermatophytes are confined to tissue with keratin and will not invade living tissue. Some species have an affinity for the keratin of hair follicles (eg,

EXHIBIT 17-2

IMPORTANT DERMATOPHYTOSIS-PRODUCING SPECIES

Genus *Epidermophyton*
- *E floccosum*

Genus *Microsporum*
- *M audouinii*
- *M canis*
- *M ferrugineum*
- *M gypseum*
- *M nanum*

Genus *Trichophyton*
- *T concentricum*
- *T mentagrophytes*
- *T rubrum*
- *T schoenleinii*
- *T tonsurans*
- *T verrucosum*

Trichophyton tonsurans), while other species have an affinity for the keratin of skin and nails (eg, *Trichophyton rubrum*). This explains the frequent limitation of infections to one site.

The host's response to infection is an important determinant of the clinical presentation. Patients with intense host responses to fungal infections produce inflammatory lesions that may be erythematous or even vesiculobullous, while hosts who have muted responses will produce scaly lesions with minimal scaling.

Tinea Capitis

Tinea capitis is primarily a disease of children, with the peak incidence occurring between the ages of 2 and 9 years. In one large study done in Chicago, 95% of culture-proven patients were under 15 years of age.[8] However, no age group is exempt: patients as old as 64 years were included in this study. Recent evidence[9] suggests that an asymptomatic carrier state may be more common in adults than previously appreciated. Tinea capitis is an uncommon problem in servicemen even under wartime conditions, but military physicians frequently diagnose and treat this condition in dependent children.

The most common organisms producing tinea capitis vary in different geographical regions. In the United States, the most common organisms are the fungi *Trichophyton tonsurans* followed by *Microsporum canis*. Prior to World War II, *Microsporum audouinii* was the most common cause of tinea capitis, but this fungus has almost disappeared in the United States. (The author has seen only one case of tinea capitis produced by this organism during the last 15 y.) *Trichophyton tonsurans* and *Microsporum audouinii* are anthropophilic fungi that are transmitted directly or indirectly from person to person; *Microsporum canis* is a zoophilic organism that is often acquired from dogs or cats.

The clinical presentation of tinea capitis may broadly be divided into noninflammatory and inflammatory states; the latter is slightly more common. In the most common noninflammatory pattern, patients present with patchy, white scales that may resemble seborrheic dermatitis (Figure 17-1). As a rule, a diagnosis of "seborrheic dermatitis" in a prepubescent child is tinea capitis until proven otherwise. Close examination will often reveal the characteristic hairs broken just above the level of the skin. Occasional patients also may demonstrate dermatophytic infection of other cutaneous sites. In other patients, broken hairs may predominate, producing diffuse or patchy alopecia that may resemble alopecia areata. Occasional patients may present with "black-dot ringworm," in which areas of alopecia demonstrate numerous broken, black,

TABLE 17-1

CLINICAL PRESENTATIONS OF DERMATOPHYTOSES

Infection	Clinical Site
Tinea capitis	Scalp
Tinea favosa	Scalp
Kerion	Scalp, hair
Majocchi granuloma	Hair
Tinea faciei	Face
Tinea barbae	Beard
Tinea corporis	Glabrous skin
Tinea cruris	Groin
Tinea manuum (manus)	Hand
Tinea pedis	Feet
Tinea unguium	Nails

Fig. 17-1. A child presented with tinea capitis due to *Microsporum audouinii*, which manifested as diffuse scaling with occasional broken hairs. The child acquired the infection while the family was stationed in Turkey.

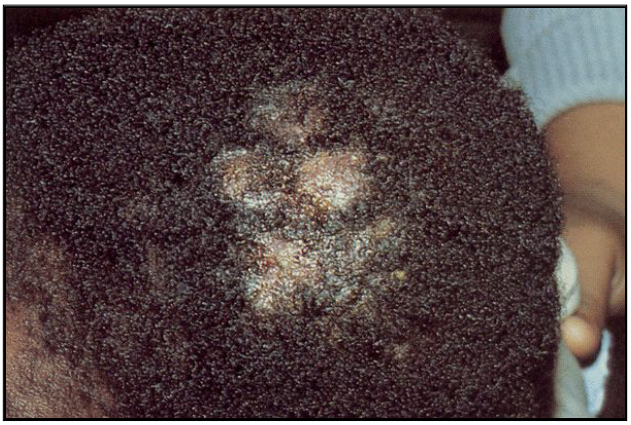

Fig. 17-3. Alopecia and scalp abscesses typical of kerion. Clinicians can easily confuse these with bacterial abscesses.

hair shafts that resemble comedones (Figure 17-2). In the United States, this pattern is almost pathognomonic of *Trichophyton tonsurans* infection, although in other geographical areas, *Trichophyton violaceum* also may produce a similar pattern.

Inflammatory tinea capitis is due to a heightened host cell-mediated immune response, virulent strains, or a combination of these two factors. Milder cases present as acute folliculitis with minimal induration of the surrounding tissues, while severe cases present as inflammatory, indurated plaques containing perifollicular abscesses (Figure 17-3). This last pattern is termed a *kerion*. Clinically, it may be confused with bacterial pyodermas, and it is not unusual for patients to be initially treated with oral antibiotics directed against *Staphylococcus aureus*, as secondary impetigo is common (Figure 17-4). Lymphadenopathy, particularly of the posterior cervical triangle, is frequently present and may further suggest bacterial infection. While most patients do not demonstrate systemic symptoms, severe kerions may be associated with high fevers and malaise.

Tinea favosa (also called tinea favus) is a rare variant of tinea capitis produced by *T schoenleinii*. This variant is rare in North America, although small outbreaks have been reported in Quebec and Kentucky.[10] Clinically, tinea favosa is characterized

Fig. 17-2. Alopecia and numerous broken hairs (black-dot ringworm) characteristic of infection with *Trichophyton tonsurans*.

Fig. 17-4. Kerion with secondary bacterial infection on the scalp of this young patient. The thick crust and edema are characteristic.

Fig. 17-5. Deep, follicular pustules of tinea barbae. These lesions result from inflammation at the site of the the organism : the follicular epithelium.

by an inflammatory alopecia demonstrating cup-shaped, honey-colored crusts called *scutula*, which are composed of masses of hyphae and serum.

Tinea capitis is a benign disease if quickly diagnosed and properly treated. Patients with noninflammatory forms and folliculitis will not demonstrate significant permanent hair loss. In patients with the kerion pattern of infection, however, approximately 50% will eventually recover normal hair density, approximately 25% will demonstrate focal hair loss that is cosmetically acceptable, and approximately 25% will demonstrate cosmetically significant permanent hair loss.

Tinea Barbae

Tinea barbae is the term reserved for fungal infection of the bearded areas of the face and is thus limited to postpubertal males. Most patients with tinea barbae are from rural areas and acquire it from close contact with animals such as horses or cows. The most common organisms are zoophilic strains of *T mentagrophytes* or *T verrucosum*. In years past, it was called "barber's itch" because the disease was commonly acquired from infected hair-cutting instruments used in barber shops. Tinea barbae was not unusual during the Vietnam conflict, but it posed considerable diagnostic and management problems for physicians because it was frequently misdiagnosed as abscesses, granulomas, or allergic contact dermatitis. Attempts at treatment by surgical drainage resulted in excessive scarring.

Patients with tinea barbae present with severe, deep, pustular folliculitis of the beard area (Figure 17-5). It is typically unilateral. Large, indurated plaques resembling kerion may be present in the most severe cases. As is true with kerions, the inflammatory and pustular nature of this condition frequently suggests a bacterial etiology and early misdiagnoses are common.

Tinea Corporis

Tinea corporis was a major problem for U.S. troops during the Vietnam conflict, particularly those assigned to combat units exposed to wet terrain. In the United States, the most common organism recovered is *T rubrum*; however, during the Vietnam conflict, the most common isolated species recovered from lesions of tinea corporis and tinea cruris was a zoophilic strain of *T mentagrophytes* that accounted for 73% of fungal infections in combat servicemen.[11] Epidemiological studies demonstrated that the most likely source was native rats. Interestingly, native Vietnamese troops and civilians were not recorded as having infections with this strain. The predominant organism identified from native Vietnamese was *T rubrum*. These data suggest that the American troops had not previously been exposed to this strain, and were thus immunologically susceptible to severe infections, while the native Vietnamese had developed immunity. This situation could recur in future conflicts.

In domestic anthropophilic infections, the sites of predilection are the neck, trunk, and buttocks, although any site may be involved. Most patients complain of pruritus although occasional patients are asymptomatic. The primary lesion is an annu-

Fig. 17-6. Primary lesion of tinea corporis demonstrating annular morphology and trailing scale.

Fig. 17-7. Extensive tinea corporis in an infantry soldier acquired at Fort Benning, Georgia.

lar, sharply circumscribed, erythematous ring with variable white scale that is most pronounced at the trailing edge of the expanding ring (Figure 17-6). The areas within the centers of the annular lesions demonstrate variable clearing with some lesions demonstrating residual scale, hypopigmentation, or hyperpigmentation. Less commonly, multiple consecutive rings produce a lesion that resembles a target. The numbers and sizes of the lesions are variable; some patients may demonstrate extensive involvement (Figure 17-7). Zoophilic strains acquired during combat in Vietnam showed a predilection for areas covered by wet clothing that could not be easily removed during combat, especially the buttocks and waist. Zoophilic strains tend to produce more-inflammed lesions and frequently show follicular involvement and secondary bacterial infections.

Tinea Faciei. Tinea faciei is a regional variant of tinea corporis that involves the face but does not affect the beard. Clinically, the primary lesions are often circinate and well defined, as they are in other forms of tinea corporis, but ill-defined erythematous lesions with indistinct borders is a clinical variant (tinea incognito) that seems to occur with great frequency.

Majocchi Granuloma. Majocchi granuloma is a variant of tinea corporis that is clinically similar to kerion of the scalp. The most common organisms are *T rubrum* and *T mentagrophytes*. The most common location is the leg, followed by the arm. Clinically, patients present with boggy, indurated papules and plaques that may drain purulent material through the follicular orifices (Figure 17-8). More-typical annular lesions suggesting the correct diagnoses may or may not be present.[12] The patients may demonstrate systemic symptoms and fever suggesting a systemic infection. From a histological standpoint, the name is a misnomer because the primary histological process is that of follicular neutrophilic abscesses, although variable granulomatous inflammation is present in mature lesions.

Tinea Imbricata. Tinea imbricata is a variant seen in the South Pacific and some regions of South America. The etiologic agent is *T concentricum*. This

Fig. 17-8. This patient's extensive Majocchi granuloma was acquired in the Panama Canal Zone. The patient had fever and malaise and required hospitalization for diagnosis and treatment.

Fig. 17-9. Chronic tinea cruris demonstrating characteristic annular border.

Fig. 17-10. Scaly, noninflammatory tinea pedis with concentric rings radiating from interdigital space.

form of infection is generally restricted to native populations and it has not been a significant problem even when American soldiers have operated in endemic areas. Clinically, it is characterized by extensive concentric rings of scale that involve extensive areas of the body and produce a "geographical" pattern that resembles the relief scale of a map.

Tinea Cruris

Tinea cruris (ie, jock itch) is almost exclusively limited to men, although women may, rarely, demonstrate a transient infection. This is probably the most common superficial fungal infection seen in young men. During the Vietnam conflict, it was the single most common dermatophytic infection: 33% of all U.S. combat troops developed tinea cruris.[11] In domestic infections, the most common causative organisms are *T rubrum*, *T mentagrophytes*, and *E floccosum*. *Epidermophyton floccosum* is highly infectious and has a high attack rate when men are housed together in military barracks, penal institutions, or dormitories, or on athletic teams. In a study of Colombian soldiers, investigators reported that *E floccosum* accounted for 82% and 78% of cases of tinea cruris in two separate groups of soldiers.[13] During the Vietnam conflict, the most common organisms were zoophilic strains of *T mentagrophytes*, followed by *E floccosum*.[11] In addition to heat and humidity, the wearing of tight briefs appears to be a predisposing factor in acquiring and maintaining tinea cruris.

Clinically, the disease may be unilateral or bilateral. Tinea cruris is often highly pruritic, and severe cases may produce pain (due to friction) on ambulation. The lesions typically start in a crural fold between the scrotum and upper thigh as an erythematous papule that demonstrates a typical, erythematous, annular configuration as it spreads to the upper thigh (Figure 17-9). More-severe lesions demonstrate vesicles, pustules, or crusting. Clinical involvement of the scrotum is uncommon.

Tinea Pedis

Tinea pedis is the term applied to dermatophytic infections of the feet. In the United States, this is the most common form of superficial fungal infection. The most common organism in domestically acquired infections is *T rubrum*, followed by *T mentagrophytes* and *E floccosum*. During the Vietnam conflict, the most common organism was, again, a zoophilic strain of *T mentagrophytes*.[6]

Clinically, domestically acquired tinea pedis usually presents as either toe web infections or demonstrates diffuse involvement of the soles. Pruritus may at times be intense. The interdigital form is usually produced by an anthropophilic strain of *T mentagrophytes* var *interdigitale*, while diffuse involvement of the soles (ie, the "moccasin sandal" form) is more commonly produced by *T rubrum*. The typical, interdigital infection demonstrates scale between the toes on the plantar side, most typically seen around the fourth toe (Figure 17-10). Variable erythema or even vesicles may also be present. Secondary bacterial overgrowth is typically present in those lesions that demonstrate macerated, whitish, hyperkeratotic toe webs associated with a foul odor (Figure 17-11). Some authorities use the term *dermatophytosis simplex* for the former condition and *dermatophytosis complex* for the latter variant.[14] The

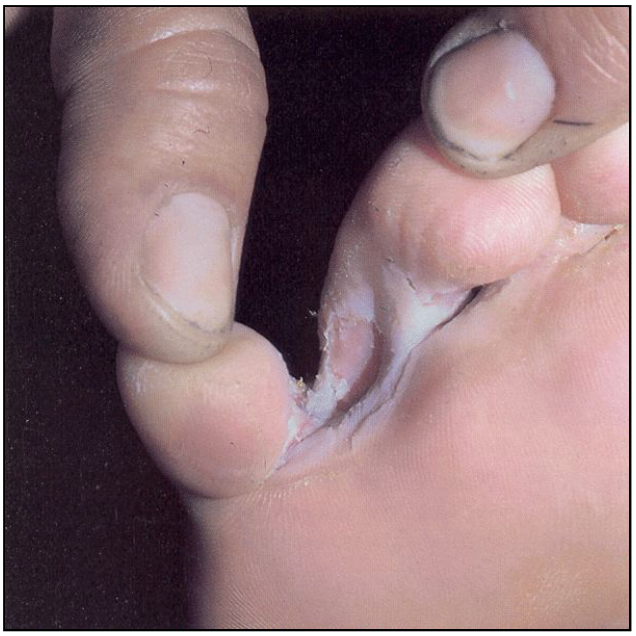

Fig. 17-11. Macerated, hyperkeratotic tinea pedis. Macerated tinea pedis may become severe enough to inhibit a soldier's combat effectiveness.

moccasin-sandal pattern is characterized by diffuse hyperkeratosis and scaling of the entire plantar surface. This variant is often asymptomatic and many patients assume that they have dry feet. In severe cases that extend to the instep or over the dorsal surface, inflammation or vesiculobullous lesions may occur (Figure 17-12). Bullous tinea pedis is most likely to occur on the instep of patients with a strong hypersensitivity to fungal antigens; however, any area of the foot may develop blisters. During the Vietnam conflict, in addition to toe web and plantar surface infection, severe infections of the dorsal surfaces of the feet and ankles were often present under the wet boots and made marching uncomfortable or impossible. Secondary bacterial pyodermas or cellulitis often complicated these infections.[5] Nail involvement is present in a high percentage of patients with diffuse hyperkeratosis, and less commonly in patients with interdigital infection.

Tinea Manuum

Tinea manuum (also called tinea manus) is the term applied to dermatophytic infections of the hand. Tinea manuum is frequently associated with tinea pedis, but it is much less common. The most common organism is *T rubrum*, followed by *T mentagrophytes*. The effect of tinea manuum on military campaigns has been insignificant because of its low prevalence and minimal morbidity.

Fig. 17-12. Severe, bullous tinea pedis of the instep initially diagnosed and treated as allergic contact dermatitis.

Tinea manuum commonly presents as diffuse scaling of the palms similar to the moccasin-sandal appearance of tinea pedis (Figure 17-13); variable erythema and vesicles may be present in patients with pronounced hypersensitivity. Most cases of tinea manuum are unilateral and are associated with bilateral infection of the feet, producing the "two-feet-one-hand" syndrome. This presentation is virtually diagnostic of dermatophytic infection. In cases difficult to differentiate from other inflammatory dermatoses, the presence of associated nail involvement may provide a valuable clinical clue.

Fig. 17-13. Tinea manuum demonstrating diffuse hyperkeratosis of the left palm. The patient had similar "moccasin sandal" lesions of both feet.

Tinea Unguium

Tinea unguium is the most precise term for dermatophytic infections of the nail; the more commonly used term onychomycosis encompasses all fungal infections of the nail, including nondermatophytes. Onychomycosis is the most common cause of nail diseases presenting to physicians for treatment.[15] Dermatophytes are responsible for 27% to 66% of all cases of onychomycosis—depending on the survey.

As in tinea pedis, tinea unguium is most commonly caused by anthropophilic strains of *T rubrum* and *T mentagrophytes*, with the former accounting for approximately 80% of infections.[15] Most cases are associated with tinea pedis or tinea manuum and are believed to arise from local extension of these infections under the nail plate. Tinea unguium is not common in active-duty personnel but appears to be much more common in elderly persons. Infection of the toenails is more common than infection of the fingernails, reflecting the higher prevalence of tinea pedis. Usually the infected nail is asymptomatic, but occasionally the nails may become painful because of trauma or poorly fitting shoes.

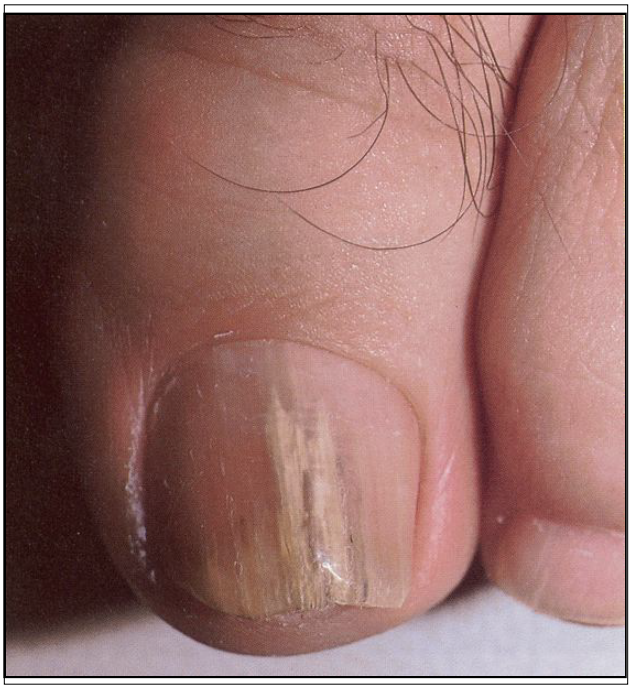

Fig. 17-14. Patients commonly present with tinea unguium demonstrating subungual hyperkeratosis.

Fig. 17-15. Tinea unguium demonstrating subungual hyperkeratosis and onycholysis. This is asymptomatic, as the surrounding skin is not affected.

Four clinical variants of tinea unguium have been defined: distal subungual hyperkeratosis, lateral onychomycosis, proximal onychomycosis, and leukonychia mycotica. Distal subungual hyperkeratosis is the most frequently encountered clinical presentation. One or more nails demonstrate subungual hyperkeratosis manifesting as a yellowish white or yellowish gray focal thickening of the nail that starts at the distal end and progresses proximally (Figure 17-14). Ultimately, the entire nail may be thickened and crumbly, or variable onycholysis may occur (Figure 17-15). Lateral onychomycosis is clinically similar except that it starts at the lateral edge of the nail. Proximal onychomycosis is a very uncommon variant that may be more common in patients with acquired

Fig. 17-16. White, opaque macular lesions of leukonychia mycotica.

immunodeficiency syndrome. Leukonychia mycotica is a somewhat uncommon variant in which the nail is invaded from its dorsal surface. Clinically, this manifests as white, opaque macules on the nail plate (Figure 17-16).[15]

Diagnosis

The diagnosis of dermatophytic infections is usually easy but even the most astute clinician may miss atypical variants. Establishing the diagnosis hinges on the demonstration of the organism by microscopical examination of skin scrapings, culture, or biopsy material.

The following 10 clinical presentations are all suggestive of dermatophytosis and the appropriate investigative studies should be carried out:

1. children with "seborrheic dermatitis" (ie, scaly scalps),
2. children with hair loss,
3. children with pyodermas of the scalp,
4. any lesion that is scaly and annular,
5. any lesion that is red and annular,
6. any bullous lesion of the hands or feet,
7. unexplained follicular abscesses, especially of the legs,
8. dermatitis of the groin,
9. dermatitis or scale of the toe webs, and
10. "dry" feet or one "dry" hand.

It should be emphasized that these are only guidelines; atypical variants may be missed even if these principles are followed. Once a dermatophytic infection is suspected, the diagnostic test of choice is the direct microscopical examination of the suspected site: skin, hair, or nails. Skin specimens are best obtained by wetting the surface with an alcohol wipe or water and scraping the advancing edge of a lesion with a number 15 scalpel blade. Some dermatologists do not wet the skin; however, this method is inferior because the specimen does not adhere to the blade and the resulting sample is smaller and may be lost in transport. The specimen is then smeared on a glass slide and one or two drops of 10% to 20% potassium hydroxide is placed on the specimen. The slide is gently heated and examined under a microscope for the presence of hyphal elements. The hyphae of dermatophytes are linear, branched, demonstrate regular walls, and often demonstrate a subtle greenish hue (Figure 17-17). If dimethyl sulfoxide is included in the potassium hydroxide, then the heating step is not required. A number of other stains and methods are available

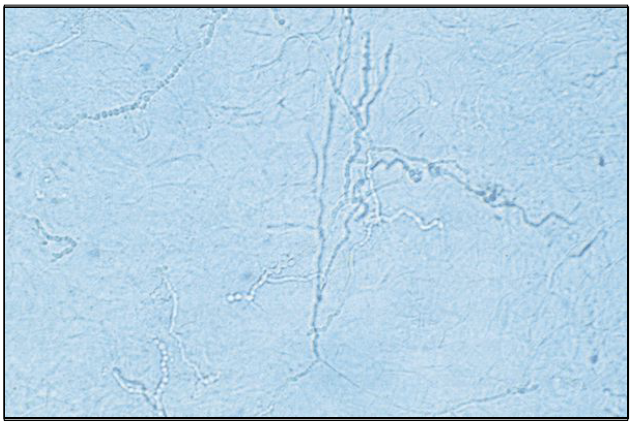

Fig. 17-17. This positive potassium hydroxide examination of glabrous skin demonstrates the characteristic branched hyphae of a dermatophyte. However, the species cannot be differentiated on the basis of potassium hydroxide preparations.

but potassium hydroxide examination remains the standard. In cases of suspected tinea capitis, the best results can be obtained when broken hairs can be plucked and examined using potassium hydroxide (Figure 17-18). Nails are inherently much more difficult to sample because the viable hyphae are often only at the proximal advancing edge. Initially, the proximal subungual debris should be scraped or the distal nail should be cut off for potassium hydroxide examination. If this examination is negative, the advancing edge can be sampled by carefully drilling a small hole with a large-bore

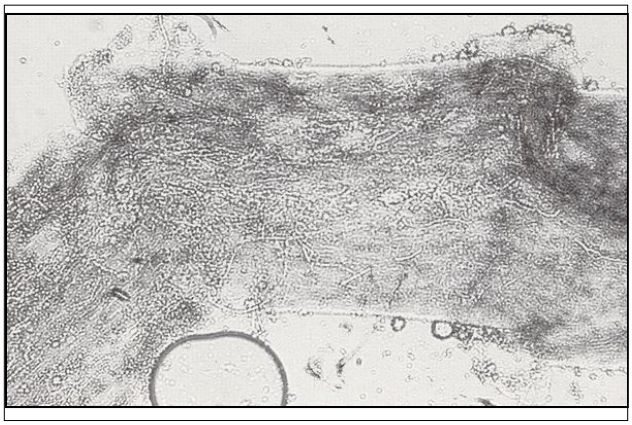

Fig. 17-18. This positive potassium hydroxide examination of infected hair demonstrates hyphae and arthrospores in a patient with tinea capitis due to *Trichophyton tonsurans* (original magnification 100X).

needle. Occasionally, other fungi, including *Candida albicans*, *Scopulariopsis brevicaulis*, *Hendersonula toruloidea*, *Aspergillus* species, *Alternaria tenuis*, *Cephalosporium* species, and *Scytalidium hyalinum* may produce onychomycosis.[15] These infections can be excluded only by culture.

In most studies, direct microscopical examination is much more sensitive than culture, but this depends on the experience of the examiner. In one study of 220 patients' dermatophytic infections, 97% were positive by direct potassium hydroxide examination and 48% were positive by culture. Positive cultures were obtained in only 2.7% of potassium hydroxide–negative specimens.[16] Similar results have been shown in several other studies.[17,18]

Cultural confirmation is often used by physicians who lack confidence in their direct microscopical examinations. Most dermatologists use cultures to exclude dermatophytic infections when the diagnosis is still suspected despite repeated negative potassium hydroxide examinations. Dermatophyte test medium is the most frequently used cultural medium. The sample is obtained in a fashion identical with that used for potassium hydroxide examinations and inoculated directly onto the culture medium. Dermatophytes usually grow within 7 days and turn the yellowish-orange medium a bright red color. If the medium turns red later than 1 week, then the color change was most likely caused by a contaminant. Dermatophyte test medium is not reliable for speciation, and if this is deemed necessary, the colony can be transferred to Sabouraud's agar. Alternatives to dermatophyte test medium for initial isolation include Sabouraud's agar (Figure 17-19) or Sabouraud's agar with antibiotics (Mycosel, manufactured by Baltimore Biologica Co., Baltimore, Maryland.)

In cases of suspected tinea capitis, a Wood's lamp is useful in cases of fluorescent dermatophytes, which includes *M canis*, *M audouinii*, *M ferrugineum*, and *T schoenleinii*. The former three organisms will demonstrate a bluish-white fluorescence of infected hairs, while *T schoenleinii* will demonstrate a dull bluish-white fluorescence. A negative Wood's light examination does not exclude tinea capitis, however, because *T tonsurans*, the most common offender, does not fluoresce.

In rare cases, a biopsy may be required to establish the diagnosis. This most commonly occurs in kerions or Majocchi granuloma, when the organisms may be difficult to demonstrate using less invasive techniques. The organisms are often difficult to visualize using standard hematoxylin-eosin stains; special stains such as periodic acid-Schiff with diastase or Gomori's methenamine silver stain are often required (Figures 17-20 through 17-22).

Treatment

The options available for the treatment of dermatophytic infections are numerous and confusing (Exhibit 17-3). In many clinical situations, the optimal therapy has not been established, and military physicians rely on anecdotal information and local availability of antimycotic agents. Treatment most

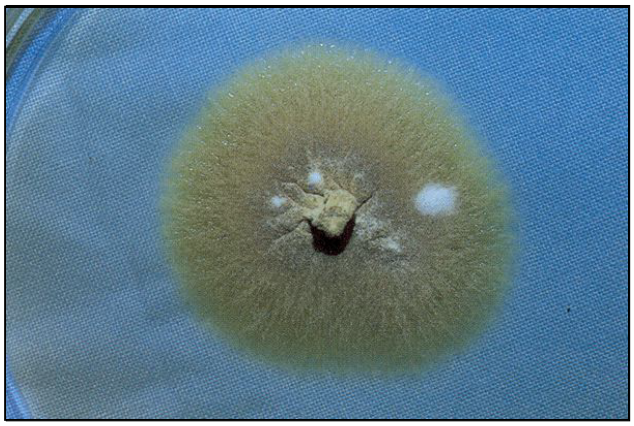

Fig. 17-19. Positive culture on Sabouraud's agar for *Epidermophyton floccosum*, a common cause of tinea cruris. Sabouraud's agar is the medium most commonly used for the culture and identification of dermatophytes.

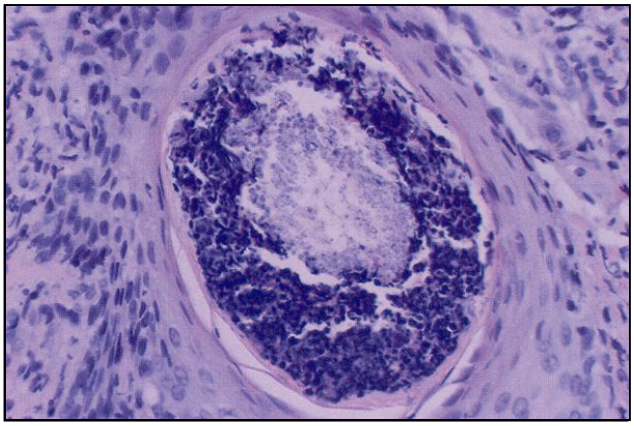

Fig. 17-20. This specimen from a biopsy of tinea capitis demonstrates marked invasion and destruction of the hair shaft (hematoxylin-eosin stain, original magnification 200X).

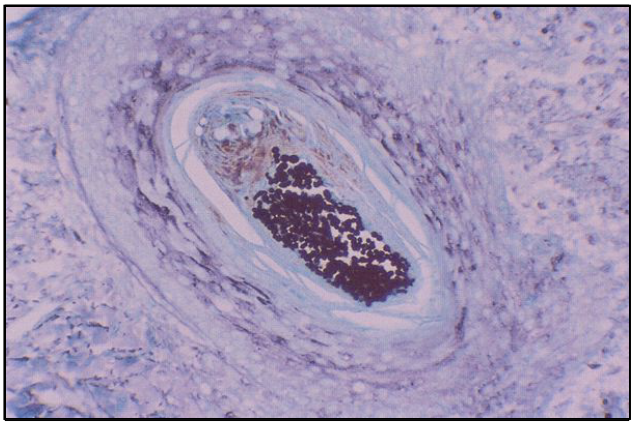

Fig. 17-21. This specimen from a biopsy of tinea capitis demonstrates improved visualization of fungal elements with special stains (Gomori's methenamine silver stain, original magnification 100X).

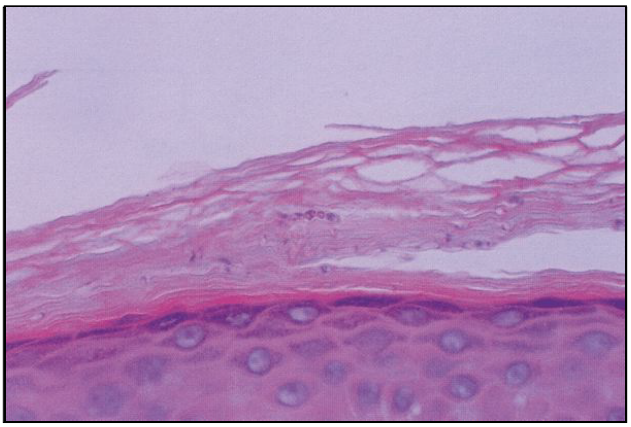

Fig. 17-22. This specimen from a biopsy of tinea corporis demonstrates both horizontal and cross sections of hyphae (hematoxylin-eosin stain, original magnification 200X).

commonly involves the use of specific antifungal agents, although nonspecific measures are often used to augment the primary therapy (Figure 17-23).

The treatment of choice for tinea capitis and other infections that invade hair follicles (eg, tinea barbae or Majocchi granuloma) is oral griseofulvin. Griseofulvin is available in both microsize and ultramicrosize forms, with the latter being absorbed from the gut approximately twice as efficiently. The dosages discussed in this chapter are for the ultramicrosize griseofulvin. If microsize griseofulvin is used, the listed dosage should be doubled. The optimal dosage of ultramicrosize griseofulvin for the treatment of tinea capitis in children has not been established. The accepted doses vary—depending on the authority cited—from 3.3 mg/kg to 5.0 mg/kg/d, given in a single daily dose. Adults should be treated with a total daily dose of 330 to 750 mg/d, depending on the severity of infection and tolerance to griseofulvin. Divided daily doses produce higher plasma levels and should be used if compliance is not a problem.[19] Treatment should continue for a minimum of 2 months, or 2 weeks past the last negative culture. Twice-weekly shampooing with 2% selenium sulfide is reported to be a useful adjunctive agent in the treatment of tinea capitis in children because it is sporicidal and may decrease the chances for spreading the infection to other individuals.[20] Ideally, other members of the family, especially children, should be examined as concurrent infection is not infrequent. Kerions require, in addition to antifungal therapy, intralesional triamcinolone acetonide at a strength of 5 to 10 mg/mL for limited lesions. Extensive lesions require the addition of oral prednisone at a dose of 1 to 2 mg/kg/d for 2 to 4 weeks.

The treatment of tinea corporis depends on the extent of involvement. Limited cases are best treated by twice-daily applications of a broad-spectrum antifungal cream (eg, one of the imidazoles, ciclopirox olamine, or naftifine). Inflamed and scaly areas should be treated for 2 weeks past the point of

EXHIBIT 17-3

ANTIMYCOTIC DRUGS

Topical
- Imidazoles
  - Clotrimazole
  - Econazole
  - Ketoconazole
  - Miconazole
  - Oxiconazole
  - Sulconazole
- Allylamines
  - Naftifine
- Hydroxypyridones
  - Ciclopirox olamine

Oral
- Griseofulvin
- Ketoconazole

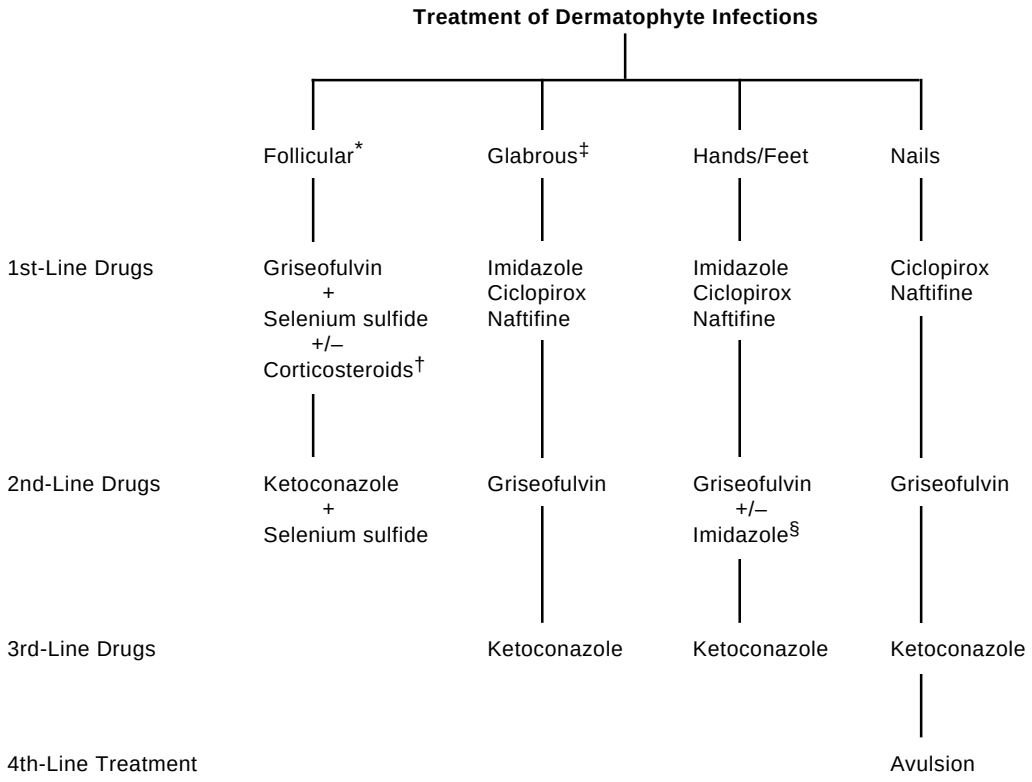

*Follicular denotes tinea capitis, follicular tinea barbae, or Majocchi granuloma
†Intralesional triamcinolone acetonide for limited lesions and oral prednisone for extensive lesions
‡Extensive cases should be treated with griseofulvin
§Griseofulvin plus topical imidazole for interdigital tinea pedis

Fig. 17-23. Algorithm for simplified, optimal treatment for dermatophyte infections.

resolution. Extensive or resistant cases should be treated with oral ultramicrosize griseofulvin (330–750 mg/d) for 4 weeks or 2 weeks past the point of total resolution. Griseofulvin-resistant cases should be treated with 200 mg of oral ketoconazole taken in a single morning dose. If the patient has not demonstrated a response at 1 month, the dose should be increased to 400 mg/d.[21]

The treatment of choice of tinea cruris is twice-daily applications of a broad-spectrum antimycotic agent (eg, an imidazole, ciclopirox olamine, or naftifine). Although good comparative irritancy studies of the various preparations have not been done, many of the topical preparations produce irritant reactions in this area, particularly in humid climates. In a study of 117 Colombian soldiers with tinea corporis and cruris, researchers report that sulconazole nitrate cream applied once daily was as effective as clotrimazole applied twice daily.[13] However, none of the sulconazole nitrate–treated patients experienced irritant reactions, while 15% of the clotrimazole-treated patients developed erosive irritant reactions. Until further, similar studies become available, sulconazole nitrate cream should be considered the topical imidazole of choice for tinea cruris in combat conditions, based on its ease of use and lack of irritancy. In resistant cases or in patients unable to tolerate topical antifungal drugs, oral ultramicrosize griseofulvin should be given in a dose of 330 to 750 mg/d for a minimum of 4 weeks, or 2 weeks past the point of total resolution. Topical haloprogin is no longer recommended for the treatment of tinea cruris because, when compared to the less-irritating imidazoles, its rate of irritation is high and its response rate is low.[22] Switching from briefs to boxer shorts is a helpful, nonspecific measure.

Tinea manuum and tinea pedis may initially be treated with topical, broad-spectrum, antimycotic agents. Infections of the toe web spaces sometimes

respond to topical antimycotic therapy alone within 4 to 6 weeks. At least one study has demonstrated that a synergistic effect can be achieved by combining a topical imidazole with oral griseofulvin.[23] Infections presenting as diffuse hyperkeratosis are associated with *T rubrum* infection and are notoriously more difficult to eradicate, often requiring 3 or more months of topical therapy; even then, the cure rate may be as low as 18%. Oral ultramicrosize griseofulvin in a dose of 330 to 750 mg/d for 3 months is probably the drug of choice in the diffuse plantar hyperkeratotic variant. The addition of a topical imidazole does not appear to produce higher cure rates. Oral ketoconazole in an oral dose of 200 to 400 mg/d should be reserved for cases of tinea manuum and pedis that are resistant to griseofulvin. Erosive or macerated interdigital tinea pedis often reflects dense colonization with resident bacteria or Gram-negative organisms. In these cases, the addition of a twice-daily application of 30% aluminum chloride or Castellani's paint (ie, carbol-fuchsin paint) may prove helpful.[24]

Tinea unguium remains the most resistant of dermatophytic infections, and many cases are essentially not curable using current therapies. In general, tinea unguium of the fingernails is more sensitive to therapy than toenails and should be treated more aggressively. Topical antifungal agents are rarely curative except in leukonychia mycotica and in occasional cases affecting fingernails.

Although good studies are not available, topical ciclopirox olamine applied to the nails twice daily is recommended over the other topical antifungal agents because its penetration of keratin is excellent.[25] Pharmacokinetic studies have also shown that naftifine penetrates the nail plate, and cures have been reported in up to 42% of patients treated with twice-daily applications of naftifine gel.[26] Additional, long-term studies will be needed to confirm these results. The efficacy of topical antimycotic agents is improved if the infected keratin is removed by mechanical means such as filing, clipping, or paring. Oral griseofulvin is the treatment of choice when systemic antifungal therapy is used, although the long-term cure rates are low. In the author's experience, 12 months of 750 mg of oral ultramicrosize griseofulvin results in a 10% cure rate in toenails and a 60% cure rate in fingernails. While initial studies suggested that oral ketoconazole in a dose of 200 to 400 mg/d was highly effective against tinea unguium, a short-term cure rate of only 26% was found, with 40% of patients relapsing within 6 months.[27] Removal of infected nails by either surgical avulsion or urea ointment is time-consuming and often associated with recurrence of infection when the nail regrows. Avulsion is indicated when nails become symptomatic or impede the wearing of shoes.[28]

CANDIDOSIS

In recent years, *candidosis* has been suggested as the preferred term to describe infections that occur as the result of mucocutaneous or systemic infection by *Candida* organisms, replacing the terms *candidiasis* and *moniliasis*. (However, candidiasis is ingrained in the medical literature and is still used by many authorities). Although other species may produce disease, particularly in immunocompromised individuals, *C albicans* is the most common pathogen (Exhibit 17-4). During the Vietnam conflict, *C albicans* accounted for most infections, although occasional isolates of *C tropicalis* were recovered.[5]

Candida organisms are usually harmless flora of the skin, mucous membranes, or gastrointestinal tract; under normal circumstances they do not produce clinical disease. *Candida* species may become opportunistic pathogens under a variety of circumstances including preexisting dermatitis, maceration, diabetes mellitus, antibiotic therapy, or immunosuppression. Unlike the dermatophytes, *Candida* organisms do not utilize keratin as a substrate for growth but prefer areas with high concentrations of

EXHIBIT 17-4

PATHOGENIC *CANDIDA* SPECIES

Candida albicans
C tropicalis
*C guillermondii**
*C krusei**
*C pseudotropicalis**
*C stelloidea**

*Rare pathogens

EXHIBIT 17-5

CLINICAL MANIFESTATIONS OF CANDIDOSIS

Cutaneous Disease
- Intertrigo
- Erosio interdigitalis blastomycetica
- Paronychia
- Onychomycosis
- Chronic mucocutaneous candidiasis

Mucosal Disease
- Thrush
- Perlèche
- Balanitis
- Vulvovaginitis

Systemic Disease*

*Not discussed in this chapter

serum or glucose. This accounts for their predilection to invade living tissue and the relatively uncommon invasion of nails and hair. Although candidosis and candidiasis are terms that encompass all infections, numerous other terms are used to describe the diverse manifestations (Exhibit 17-5). Mucocutaneous candidosis is of interest to military medicine; systemic candidosis is not discussed in this chapter.

Candidosis was not listed as a significant problem in the military campaigns of World War I[2] or World War II,[3] but was a major problem during the Vietnam conflict.[5] It is difficult to imagine that candidosis was not a problem in tropical areas during the Pacific Campaign in World War II, and it is most likely that the disease was unreported or misdiagnosed. During the Vietnam conflict, candidosis of the skin and mucosa was estimated to be the third-most-common cause of skin disease.[6] In one survey, *C albicans* was isolated from 10% of soldiers in the Mekong Delta. These isolations were frequently associated with dermatophytic infections, suggesting that candidosis was often a secondary infection. As in the case of dermatophytosis, candidosis was more prevalent in combat troops than in support troops. An exception to this was support troops in extremely hot and humid environments (eg, cooks and boiler-room workers).[5] The most common sites of infection were the toe web spaces and the groin.

Clinical Features

Intertrigo

The most common form of candidal infection experienced by military personnel is intertrigo (ie, infections of intertriginous areas). The most common intertriginous areas affected are the groin, followed by the toe web spaces, inframammary crease, and axillae. *Candida albicans* prefers high humidity and a damaged stratum corneum for growth. These two requirements are frequently fulfilled during military campaigns, particularly in tropical climates where clothes and boots are often soaked and the stratum corneum is damaged by other infections or friction.

Symptoms of candidal intertrigo include pruritus and burning. Candidosis is more likely to be painful than dermatophytosis, presumably due to invasion of viable tissue and a brisk host response. In the groin and axilla, patients with candidal intertrigo present with confluent, very erythematous lesions that demonstrate satellite lesions at the periphery (Figure 17-24). Small pustules are frequently present and central clearing—as seen in dermatophytic infections—is distinctly rare. Toe web infections demonstrate severe maceration associated with irregular plaques of white acanthosis. The surface of the denuded areas is fiery red and raw.

Erosio interdigitalis blastomycetica is a peculiar, erosive, hyperkeratotic form of candidal intertrigo

Fig. 17-24. Candidosis of the groin demonstrating marked erythema, satellite lesions, and scrotal involvement; all features are suggestive of candidosis.

Fig. 17-25. Erosio interdigitalis blastomycetica demonstrating characteristic whitish hyperkeratosis. This patient also had diabetes mellitus, a common predisposing factor.

that affects the interdigital spaces, particularly between the third and fourth fingers (Figure 17-25). This clinical variant is seen in patients whose hands are immersed repeatedly in water. Experimental studies suggest that erosio interdigitalis blastomycetica is a synergistic infection of *C albicans* and one or more Gram-negative rods.[29]

Paronychia and Onychomycosis

Candidal paronychia and onychomycosis are often present simultaneously. The role of *Candida* organisms in producing paronychia is controversial, as other fungi and bacteria may also be recovered. Paronychia is strongly associated with persons whose hands are repeatedly immersed in water (eg, cooks). The author personally developed paronychia while working as a bartender; the problem resolved spontaneously following a change in occupation. Clinically, candidal paronychia appear as erythematous, edematous lesions affecting the periungual tissues around one or more fingers. Occasionally, small amounts of purulent material may be expressed from beneath the proximal nail.

Candidal onychomycosis most commonly occurs in association with paronychia. It is generally regarded as a secondary process that occurs due to inflammation of the nail matrix. Clinically, it presents as nail dystrophy with horizontal or vertical furrows. Occasionally, *Candida* organisms may be recovered from the subungual spaces beneath onycholytic nails. It is unclear whether this represents infection or merely colonization of a moist habitat.

Chronic mucocutaneous candidosis is a rare, progressive form of infection that occurs in persons with inherited or sporadic defects in cell-mediated immunity. This is a heterogeneous disorder with anywhere from four to seven subtypes depending on the classification system used. Some cases may be associated with endocrinopathies or thymomas. In most cases, onset occurs during childhood, with cutaneous or mucosal infection that is resistant to normal therapies. Eventually, the lesions progress and produce diffuse oral thrush, perlèche, and involvement of virtually any cutaneous surface including nails, in which the entire thickness of the nail plate may be invaded and destroyed (Figure 17-26).

Except for chronic mucocutaneous candidosis, *Candida* organisms can affect glabrous skin only when occluded. This most commonly occurs in infants wearing occlusive diapers (Figure 17-27). While candidosis is only one of many causes of diaper dermatitis, a correct diagnosis is important because it affects treatment. The primary lesions are usually sharply demarcated areas of erythema that are confluent in folds that are associated with satellite erythematous papules or pustules. In adults, similar lesions may occur under dressings (Figure 17-28) and in immobilized hospital patients (Figure 17-29).

Fig. 17-26. Chronic mucocutaneous candidiasis demonstrating onychomycosis, paronychia, and marked hyperketosis.

Fig. 17-27. Marked diaper dermatitis secondary to candidosis. Note satellite lesions. Photograph: Courtesy of Bruce Kornfeld, MD, Fort Collins, Colo.

Fig. 17-29. Marked candidosis can be seen in this immobilized airborne soldier, who fractured both legs during a training jump.

Candidal vaginitis is a very common infection; it is usually seen by gynecologists and will not be discussed here. However, extension of infection to the vulva (vulvovaginitis) may occur, particularly when the patient is pregnant, diabetic, immunocompromised, or taking antibiotics. The most common symptoms are pruritus or burning. The findings include a vaginal discharge, erythema of the introitus and vulva, and characteristic satellite lesions on the vulva. Similar lesions may occur in men, particularly uncircumcised men, who may present with erythematous papules, diffuse erythema (Figure 17-30), or even superficial erosions (Figure 17-31).

Fig. 17-28. Candidosis is limited to the occluded site beneath the tape. The local heat and moisture afforded by occlusion predispose to fungal infections.

Candidosis is the most common fungal infection of the oral mucosa.[30] The most common oral mucosal presentations are perlèche and thrush. Oral candidosis most commonly affects newborns, the elderly, and patients who have diabetes or are immunocompromised. The presence of oral candidosis in a young soldier should precipitate a search for diabetes mellitus and infection with the human immunodeficiency virus. Perlèche (ie, infection of the angles at the corners of the mouth) is usually but not invariably associated with thrush. Clinically, patients present with cracks or fissures at both corners of the mouth; these are associated with an adherent, white exudate (Figure 17-32). The hallmark of thrush is the presence of white patches anywhere within the oral mucosa. These areas are composed of white, creamy-to-almost-

Fig. 17-30. This patient with candidal balanitis presented with diffuse erythema and edema.

Fig. 17-31. A soldier stationed in Korea presented with candidal balanitis manifesting as superficial erosions. This patient had been incorrectly diagnosed with and treated for chancroid and genital herpes.

Fig. 17-32. This patient with perlèche presented with bilateral fissures associated with white exudate.

cheesy exudates that are adherent but easily removed. The underlying mucosa is brightly erythematous. Involvement of the tongue results in intense erythema and loss of papillae.

Diagnosis

The diagnosis of candidosis is usually suspected based on the clinical presentation. In intertriginous areas or areas under occlusion, the presence of sharply demarcated erythema associated with small, brightly erythematous, satellite lesions is candidosis until proven otherwise. Similarly, leukoplakia of the oral mucosa that is easily removed with scraping is most likely candidosis.

The diagnosis is established by demonstrating the organism either microscopically or by culture.

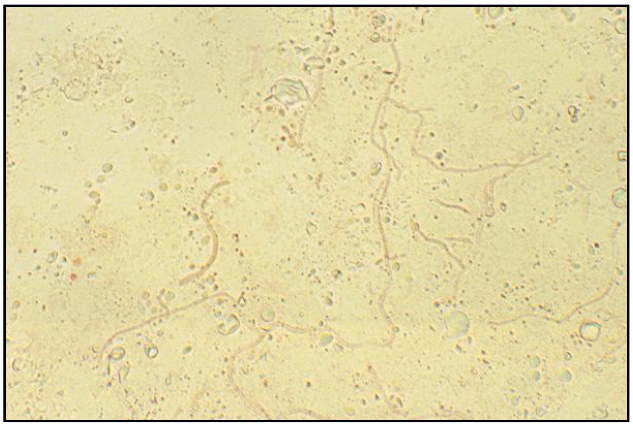

Fig. 17-33. Positive potassium hydroxide examination of thrush demonstrating pseudohyphae and yeast forms.

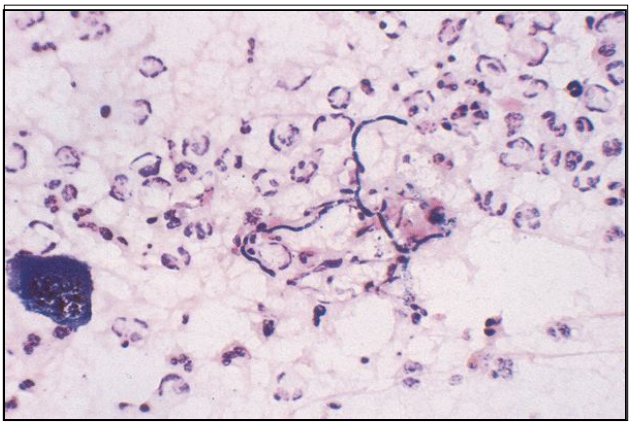

Fig. 17-34. Positive Gram's stain of a pustular lesion of candidosis demonstrating neutrophils and pseudohyphae.

Using potassium hydroxide examination on cutaneous surfaces, the yeast and pseudohyphae of candidosis are generally more difficult to find than dermatophytes: the viable pseudohyphae often penetrate deeper than the stratum corneum and samples are often too superficial. Scrapings of mucosal surfaces are more often positive (Figure 17-33). Gram's stain is particularly useful on pustular lesions that could be either bacterial or fungal because it will stain both bacteria and *Candida* organisms (Figure 17-34). Scrapings also may be cultured on either Sabouraud's or on a *Candida*-specific medium such as Nickerson's. On Sabouraud's medium, the colonies are white or cream-colored and produce a yeastlike odor (Figure 17-35) On Nickerson's medium, the colonies produced are dark. Speciation of *C albicans* can be confirmed by the demonstration of chlamydospores on cornmeal agar or the production of germ tubes in the presence of serum. On rare occasions, candidosis is not suspected and the diagnosis is made on biopsy specimens. Histologically, hyphal and yeastlike structures are seen in the stratum corneum and upper stratum spinosum. Neutrophils are more commonly associated with candidosis than dermatophytosis; this may manifest as subcorneal blisters or focal neutrophilic spongiosis (Figure 17-36).

Treatment

Infection with *C albicans* responds to the antimycotic drugs typically used against dermatophytes—except tolnaftate and griseofulvin. Intertrigo, including erosio interdigitalis blastomycetica, is best treated by twice-daily applications of topical imidazoles, ciclopirox olamine, or naftifine. If the lesions are inflammatory or painful, sulconazole or nystatin are probably preferred due to their lack of irritancy. Nystatin, formerly the antifungal of choice for candidosis, has largely been replaced by the imidazoles due to the emergence of both primary and secondary resistant strains of *Candida* species.[31] Amphotericin B lotion or cream is also effective but is not recommended because of its cost. Nonspecific measures such as reducing moisture and maceration with a hair dryer and

Fig. 17-35. Positive culture for *Candida albicans* on Sabouraud's agar demonstrating a typical white, yeasty colony. Definitive identification usually requires subculture on cornmeal agar.

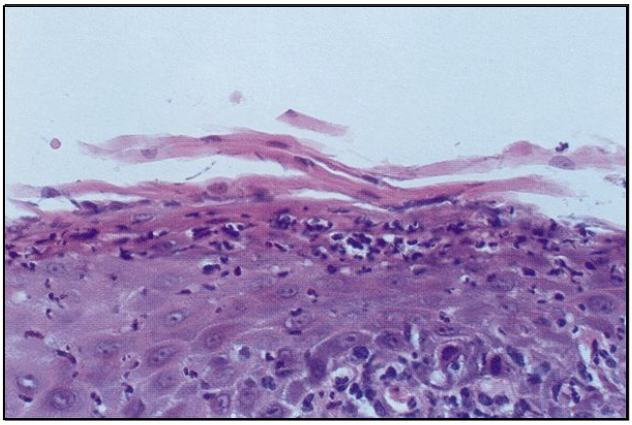

Fig. 17-36. This specimen from a biopsy of cutaneous candidosis demonstrates neutrophilic spongiosis and pseudohyphae, which are clearly seen between two fragments of keratin (hematoxylin-eosin stain, original magnification 400X).

weight reduction are also helpful. Paradoxically, very painful inflammatory lesions can be relieved with water or Burrow's solution compresses three or four times per day.

Candidal paronychia and onychomycosis can usually be improved by simply having the patient discontinue wet work if feasible, or using cotton-lined gloves if water exposure is inevitable. Women also should be advised to discontinue the practice of pushing back the cuticle to allow it to reattach to the dorsum of the nail plate. A 3% to 4% solution of thymol in alcohol applied three times daily to the paronychial area is an extremely beneficial first-line therapy. Resistant cases can be treated with topical imidazoles, ciclopirox olamine, nystatin, or naftifine, applied twice daily. Therapy should be continued 2 weeks past the point of clinical resolution.

Thrush is best treated with nystatin oral suspension in a dose of 5 mL (500,000 units) held in the mouth for several minutes and then swallowed. This treatment is repeated four times daily for 7 to 10 days. An alternative approach is dissolving clotrimazole troches in the mouth five times daily for 2 weeks.[32] Gentian violet (0.5% to 1%) may be applied to affected areas two or three times daily in resistant cases, but is infrequently used because of the inevitable purplish discoloration. Perlèche readily responds to the twice-daily application of a topical imidazole, ciclopirox olamine, nystatin, or naftifine cream.

The first-line treatment of vulvovaginitis is one of the imidazole products made for use in this area including clotrimazole, miconazole, and butoconazole. These treatments have largely replaced nystatin, which is slightly less effective. Recurrent cases may respond to oral ketoconazole in a dose of 400 mg/d for 2 weeks for control.

PITYROSPORUM INFECTIONS

Pityriasis versicolor is the correct term for superficial infections of the epidermis produced by the yeast *Pityrosporum orbiculare*. Many authorities continue to use the term tinea versicolor, although "tinea" is incorrect: it denotes infection with a dermatophyte that uses keratin for a substrate. *Pityrosporum* species require lipids for growth and thus are not dermatophytes. The taxonomy is also confusing in that *P orbiculare* is the taxonomic term most commonly used for the yeast phase of the fungus, while Malassezia furfur is the term sometimes used for the pathogenic hyphal phase. Some authorities do not make this distinction and one term or the other is used without explanation. However, Malassezia furfur is a confusing term and should not be used. From a taxonomic and mycological standpoint, *P orbiculare* is preferred.[33]

Pityrosporum species may also produce a characteristic folliculitis (formerly called Malassezia folliculitis). The organism responsible for pityrosporum folliculitis is probably *P orbiculare*, although good cultural studies are lacking. Some authorities have stated that *P ovale* is the etiologic agent; however, recent morphologic, physiological, and immunological studies suggest that this species is identical with *P orbiculare*.[34]

Pityrosporum organisms may occasionally produce systemic infections in the immunocompromised host, particularly when intravenous lipids are administered. This manifestation is beyond the scope of this chapter and will not be discussed.

Clinical Features

Pityriasis Versicolor

Pityriasis versicolor is a trivial cutaneous infection. It has had minimal impact on military campaigns and is infrequently discussed in the medical histories of previous wars. The importance of pityriasis versicolor on the military is related only to the cost of treatment and time lost from work. During World War II, a dermatology clinic in Camp Lee, Virginia, reported that pityriasis versicolor accounted for 2.4% of visits.[3] During the Vietnam conflict, it frequently caused outpatient visits, often because soldiers feared that it was a manifestation of a sexually transmitted disease. Pityriasis versicolor accounted for 2.7% of visits at one dermatology clinic, making it the tenth-most-common dermatologic complaint.[5]

Pityriasis versicolor is more common in warm, humid climates, where it may affect up to 50% of individuals in some areas of the world.[35] The incidence is higher in persons such as cooks who work in hot, humid places (Figure 17-37). Many patients do not even regard it as a disease and it is frequently diagnosed during examination for other diseases. Pityriasis versicolor often affects multiple members of the same family, suggesting a genetic susceptibility to infection. It is possible that this familial clustering of infections may be due to more virulent strains, although this has not been investigated.

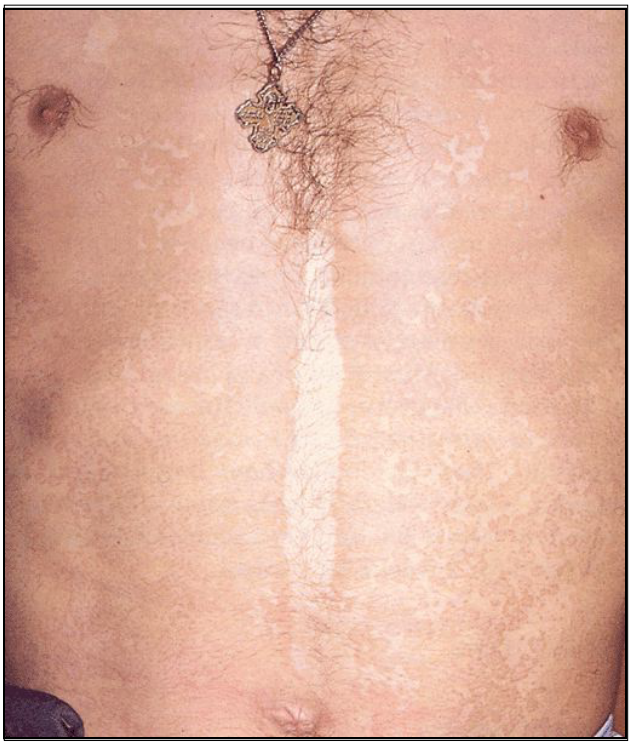

Fig. 17-37. This patient, a cook in the U.S. military, has extensive pityriasis versicolor involving almost his entire trunk.

Fig. 17-38. Characteristic fawn-colored macules of pityriasis versicolor are present on the abdomen of this young man.

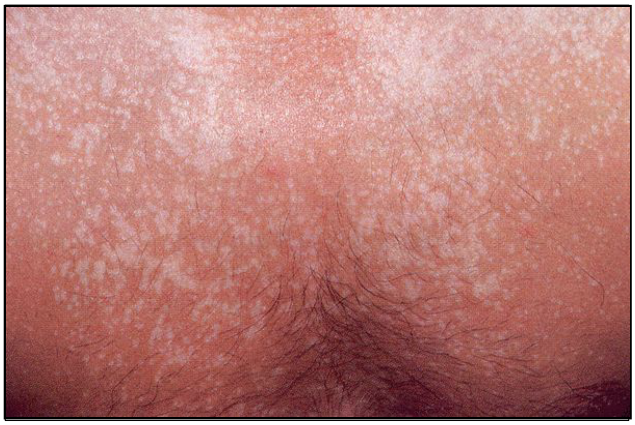

Fig. 17-39. Hypopigmented lesions of pityriasis versicolor.

Pityriasis versicolor is usually asymptomatic, although occasional patients may complain of a burning sensation or mild pruritus. The primary lesions are usually tan or fawn-colored macules that may coalesce into large patches that almost replace the entire skin. Close inspection reveals a fine, branny scale that covers the entire macule or patch (Figure 17-38). Annular lesions are distinctly uncommon, although occasional lesions may be perifollicular. Inflammation is usually absent. The affected areas usually display a truncal distribution, although extension to acral areas may occur. Less commonly, the primary lesions are hypopigmented, which apparently is due to the yeast's production of biochemical products that interfere with melanin synthesis and packaging. This decrease in pigmentation is more noticeable when the patients attempt to develop a tan (Figure 17-39).

Pityrosporum Folliculitis

The prevalence of pityrosporum folliculitis infection in military combat personnel is unknown because only in recent years has this infection been defined and accepted as a valid disease process.[36] Given the benign nature of this disease, it is unlikely to have affected military campaigns.

Pityrosporum folliculitis most commonly affects young and middle-aged persons and has a predilection for women. Although most patients are healthy, this infection may be more common in immunocompromised hosts.

The lesions of pityrosporum folliculitis are intensely pruritic; this is often the primary reason that patients seek medical treatment. The pruritus may be aggravated by intense sweating or showers. The

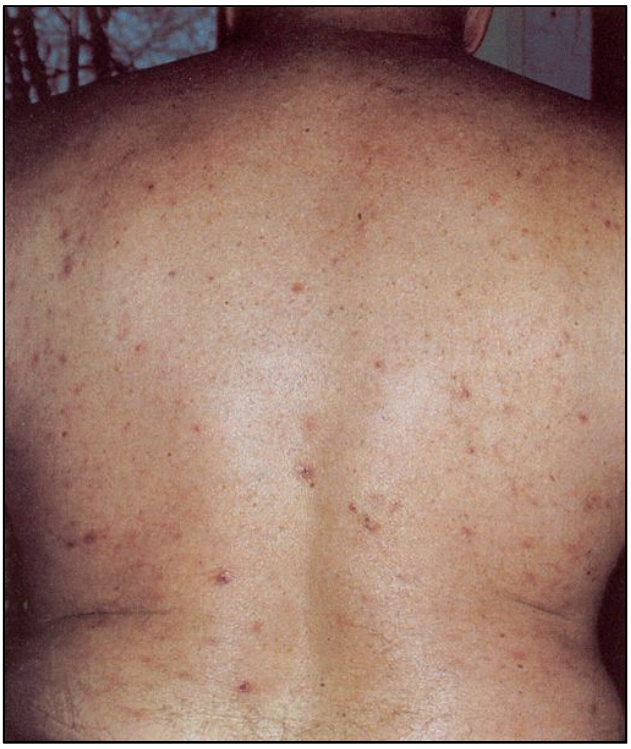

Fig. 17-40. Extensive pityrosporum folliculitis of the back. The clinical picture can closely mimic acne vulgaris.

primary lesions are discrete, follicular papules and pustules, typically 2 to 4 mm in diameter, and most commonly located on the upper back, arms, and chest (Figure 17-40). Lesions occasionally develop on acral areas such as the face, arms, and legs. Variable erythema, excoriations, and wheal-and-flare reactions also may be present.

Other Pityrosporum Infections

The role of *Pityrosporum* yeast in the pathogenesis of seborrheic dermatitis is controversial. The presence of high concentrations of yeast in lesions of seborrheic dermatitis, combined with a frequent response to topical imidazole treatment, support the notion of a potential role. However, the not-infrequent failure of imidazoles to improve seborrheic dermatitis and the presence of high concentrations of yeast in clinically normal patients who have no demonstrable seborrheic dermatitis both suggest that *Pityrosporum* organisms may play a secondary role. Further studies are needed to define the role of *Pityrosporum* in the pathogenesis of seborrheic dermatitis.

Diagnosis

The diagnosis of pityriasis versicolor can usually be made based on the clinical presentation alone. The finding of asymptomatic, branny or whitish scales that are located primarily on the trunk is pityriasis versicolor until proven otherwise. Atypical cases may be diagnosed by microscopical examination of skin scrapings that are treated with potassium hydroxide; the examination is performed exactly like that for dermatophytic infections. Because the organism is located superficially in the stratum corneum, many physicians prefer to obtain specimens by touching lesions with clear cellophane tape. A drop or two of potassium hydroxide is placed on a slide and the tape is then placed sticky-side down over the potassium hydroxide. This technique is more rapid and less traumatic than the skin-scraping method. Alternatively, instead of potassium hydroxide, a 0.5% to 1% solution of toluidine blue may be used because the yeast preferentially take up this dye. The diagnosis is made by finding short, straight hyphae associated with clusters of round, budding yeast, often referred to as "spaghetti and meatballs" (Figure 17-41). In contrast to dermatophytic infections, the organisms are so abundant in pityriasis versicolor that a negative result obtained from a properly performed examination excludes this diagnosis.

Atypical lesions are sometimes biopsied. The biopsies demonstrate a somewhat normal epidermis with a mild, superficial, perivascular, lymphocytic dermatitis associated with mild hyperkeratosis

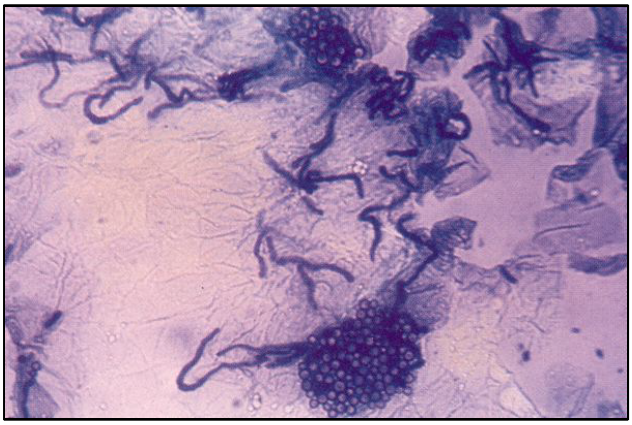

Fig. 17-41. This toluidine blue tape preparation demonstrates the yeast and short hyphae that are characteristic of pityriasis versicolor (original magnification 200X).

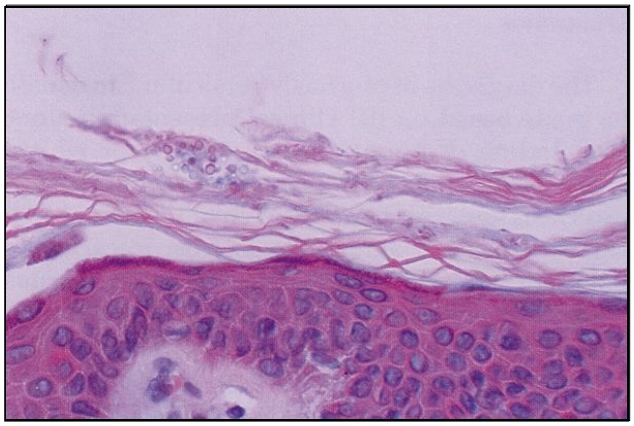

Fig. 17-42. This biopsy of pityriasis versicolor demonstrates the characteristic yeast and short hyphae (hematoxylin-eosin stain, original magnification 200X).

that may demonstrate a basket-weave (ie, slightly compact) appearance. The organisms are found in the stratum corneum and are often found in greater numbers near hair follicles (Figure 17-42). Occasionally, the organisms are difficult to visualize with hematoxylin-eosin stain, and special stains such as Gomori's methenamine silver or periodic acid-Schiff stain may be required to demonstrate them. Cultures are only required when a diagnosis of pityrosporum septicemia is suspected. Routine dermatologic media such as Sabouraud's or dermatophyte test medium do not support growth; the medical mycology technician must be informed that infection with *Pityrosporum* organisms is suspected so that a lipid source can be added to the medium.

Pityrosporum folliculitis is diagnosed based on the clinical presentation combined with a biopsy showing folliculitis and *Pityrosporum* yeast. The clinical features most suggestive of pityrosporum folliculitis are the characteristic distribution and associated pruritus. Microscopically, the organ-

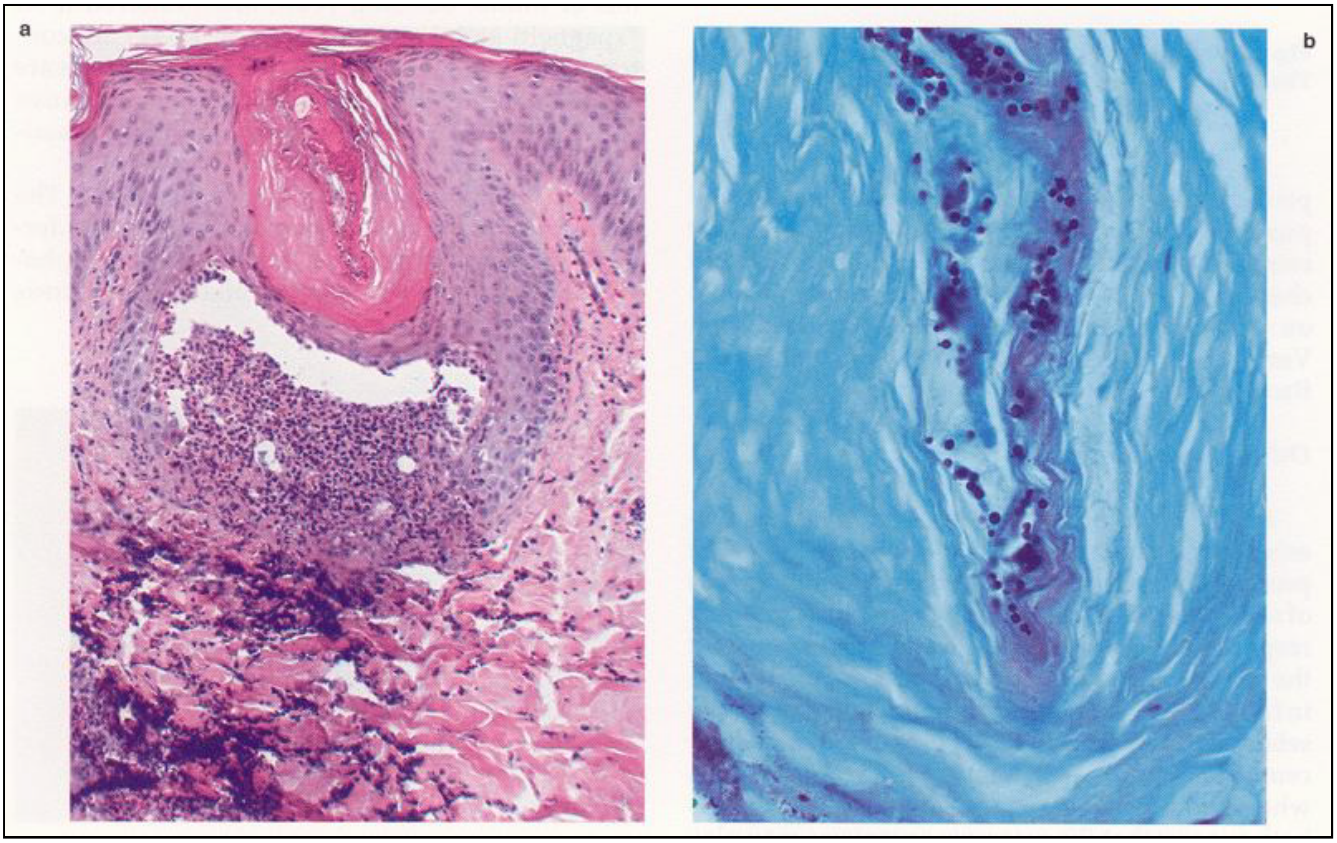

Fig. 17-43. (**a**) This biopsy of pityrosporum folliculitis demonstrates acute folliculitis (hematoxylin-eosin stain, original magnification 100X). (**b**) The same tissue, stained with periodic acid–Schiff stain and digested with diastase (original magnification 200X), demonstrates budding yeast. The organisms are difficult to visualize with routine hematoxylin-eosin stains.

isms are always in the yeast phase and the short hyphae seen in pityriasis versicolor are absent. Special stains are frequently necessary to visualize the yeast, as they can be difficult to locate in the presence of severe inflammation (Figure 17-43).

Treatment

Numerous treatments are reported to be effective for pityriasis versicolor; however, many topical therapies have a high rate of clinical relapse. Patients with focal or limited disease may be treated with topical antifungal agents (ie, an imidazole, ciclopirox olamine, naftifine, or tolnaftate) applied twice daily for 2 weeks. The cure rates achieved with these regimens are in the range of 80% to 90%.[37] However, these agents are relatively expensive and have a high relapse rate. Patients with extensive disease are most commonly treated with either selenium sulfide suspension applied daily for 10 to 30 minutes for 7 to 14 days or a zinc pyrithione shampoo applied daily for 5 minutes for 14 days. These regimens are inexpensive and have high cure rates; however, both regimens are associated with severe irritant reactions if the patient leaves the product on the skin for extended periods of time. As in the case of the topical imidazoles, relapses are common. Other effective topical agents include propylene glycol, sodium hyposulfite, sodium thiosulfate combined with salicylic acid, salicylic acid preparations, and retinoic acid cream.

Oral ketoconazole is the most effective treatment of pityriasis versicolor. In addition to a high cure rate, it is associated with a much lower relapse rate. However, the development of idiosyncratic acute hepatitis reactions has prevented oral ketoconazole from replacing topical therapies as the first-line drug. Initial studies used 200 to 400 mg/d of oral ketoconazole for up to 4 weeks and reported high response rates. More-recent research has reported that a single, 400-mg dose cured 100% of patients, and that recurrences could be prevented by repeating this treatment on a monthly basis.[38] The author currently utilizes an intermediate dose of 200 mg/d for 7 days and does not use a prophylactic dose. Comparative studies are clearly needed to define the optimal dose.

The treatment options for pityrosporum folliculitis are almost the same as for pityriasis versicolor. Topical therapy with selenium sulfide lotion, 50% propylene glycol in water, and econazole cream have been reported equally efficacious when used for 3 to 4 weeks; however, if intermittent therapy was not continued, folliculitis frequently recurred.[36] Oral ketoconazole in a dose of 200 mg/d for 4 weeks is also effective, but the relapse rate approaches 100% and; therefore; it is not recommended for first-line therapy.[39]

MISCELLANEOUS FUNGAL INFECTIONS

Tinea Nigra

Tinea nigra is an uncommon superficial dermatomycosis produced by the dimorphic fungus *Exophiala werneckii* (formerly *Cladosporium werneckii*). *Exophiala werneckii* is a dematiaceous fungus that is commonly found in the soil and decaying vegetation. Tinea nigra is most commonly reported from subtropical and tropical climates, although occasional cases are acquired in the United States. This asymptomatic, rare infection is not important from a military standpoint. Other than the cosmetic appearance, it is only important in that it may be confused with acral lentiginous melanoma.[40]

Clinically, tinea nigra is characterized by asymptomatic gray, tan, brown, or black macular lesions on the palms or plantar surfaces, although, rarely, other sites are infected (Figure 17-44). The lesions are usually unilateral, although bilateral infection has been reported. Spontaneous resolution usually does not occur.[41]

The diagnosis is usually suspected based on clinical examination alone. The diagnosis can be confirmed by the demonstration of olivaceous, tortuous, septate hyphae associated with variable numbers of arthrospores on potassium hydroxide examinations of skin scrapings (Figure 17-45). The diagnosis also can be established by culturing skin scrapings on Sabouraud's medium at room temperature. Typical colonies are initially white or gray with a smooth surface but quickly turn olive or black with a downy edge. Occasionally, lesions are biopsied to rule out acral lentiginous melanoma. Histopathological examination reveals variable hyperkeratosis associated with hyphal elements that are located primarily in the upper stratum corneum. A superficial, perivascular, lymphocytic infiltrate is variably present.

Scraping the affected stratum corneum off with a surgical blade or abrasive cosmetic pad, followed by applying a topical imidazole or ciclopirox olamine, has been recommended as the treatment of

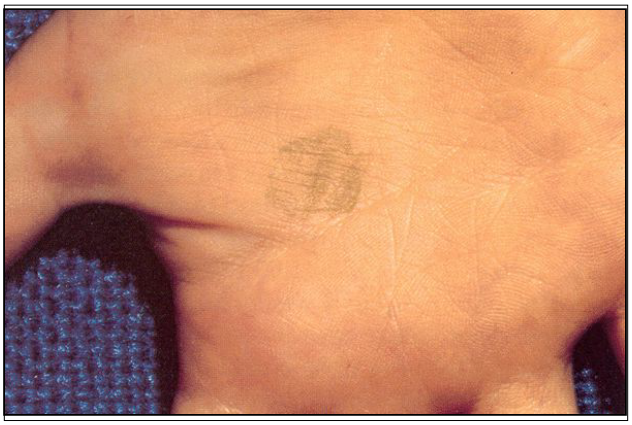

Fig. 17-44. A grayish-green macular lesion of tinea nigra can be seen on the palm of this 4-year-old child.

Fig. 17-45. This positive potassium hydroxide preparation of tinea nigra, taken from the palm depicted in Fig. 17-44, demonstrates the olivaceous, tortuous septate hyphae.

choice.[41] Other effective treatments include epidermal stripping, keratolytic agents, and thiabendazole. Oral griseofulvin does not appear to be an effective therapy.

Black Piedra

Black piedra is a rare infection of terminal hairs produced by the dematiaceous fungus, *Piedraia hortae*. Black piedra is endemic in South America, although it has also been described in other tropical regions such as Africa and Asia. Familial infestations affecting multiple generations have been observed in endemic areas.[42] The disease is inconsequential in terms of its effect on military personnel.

The primary lesions are small, hard, ovoid, adherent, brown-to-black nodules that affect the scalp hairs. Black piedra produces broken hairs and does not spread to other terminal hairs; this is in contrast to the presentation of white piedra (discussed below).

The diagnosis can be suspected on the clinical presentation alone. The diagnosis can be firmly established by microscopical examination of the concretions, which demonstrate intertwined masses of brown hyphae surrounding an oval ascus that contains eight ascospores. Cultures on Sabouraud's agar demonstrate small, brown-to-black, adherent colonies.

The treatment of choice is removing infected hairs by either shaving or plucking. Recurrences are common in endemic areas.

White Piedra

White piedra (also called trichosporosis) is an infection of the terminal hair shafts caused by *Trichosporon beigelii* (formerly called *T cutaneum*). *Trichosporon beigelii* is a ubiquitous, yeastlike fungus that has been isolated from soil, air, stagnant water, and sewage. White piedra is endemic to tropical areas and formerly was thought to be uncommon in the United States. However, in a prospective study, researchers were able to isolate *T beigelii* in 40% of young men and 14% of young women in Houston, Texas.[43] These data suggest that white piedra is far more common than was formerly appreciated. Although cases have been reported in military personnel in San Antonio, Texas,[44] white piedra has not been reported to affect previous military campaigns.

Clinically, the primary lesions are typically white, although light-gray, red, brown, or greenish variants have also been observed. The concretions vary from distinct, ovoid nodules to coalescent concretions that totally coat the hair shaft. The nodules are softer and more easily removed than those seen in black piedra. The affected hairs are often straighter than the unaffected hairs. Cuticular invasion may occasionally produce broken hairs. The most commonly affected areas are the scalp, beard, moustache, and genital regions; less commonly affected areas are the eyelashes, eyebrows, and axillae. Rare manifestations of white piedra include onychomycosis and systemic dissemination in immunocompromised patients.

The diagnosis of white piedra may be suspected on the clinical appearance; however, trichomycosis caused by *Cornebacterium tenuis* may be clinically similar. A distinctive, dull-yellowish fluorescence is present under Wood's light examination; this may be a helpful diagnostic finding.[39] The

diagnosis can be confirmed by either a potassium hydroxide–glass-slide mount of an affected hair, which will demonstrate concretions composed of hyaline spores, or culture on Sabouraud's dextrose agar at room temperature. Dermatophyte test medium and other media that contain cycloheximide should not be used for isolation because cycloheximide will inhibit growth. The characteristic colonies are cream-colored, piled-up, and may demonstrate radial grooves.

The treatment of choice is shaving the affected hairs and applying a topical antifungal agent such as an imidazole or 10% glutaraldehyde.

SUMMARY

Soldiers suffer from superficial cutaneous infections during both peace and war. During peacetime, the infections are mild and rarely produce significant morbidity; however, during wartime conditions, soldiers are exposed to more virulent strains of zoophilic and geophilic dermatophytes that are likely to induce an intense host response. When superficial fungal infections are combined with poor hygiene and hot, humid climates, combat units can be expected to suffer significant morbidity and loss of effective fighting strength—as was observed in the Asian theater during World War II and during the Vietnam conflict.

Medical officers, who may have to treat superficial fungal infections under field conditions, need to be familiar with the myriad of clinical manifestations. This is particularly important because adequate diagnostic equipment such as cultures, microscopes, and potassium hydroxide solution may not be readily accessible. Frequently, diagnosis and treatment must be initiated based on the clinical presentation.

The treatment options for the management of cutaneous fungal infections is becoming increasingly complex as new oral and topical antifungal agents are developed and released. Medical officers need to acquaint themselves not only with standard therapies but also with alternative therapies for resistant cases.

REFERENCES

1. Matsumoto T, Ajello L. Current taxonomic concepts pertaining to the dermatophytes and related fungi. *Int J Dermatol*. 1987;26:491–499.

2. Macpherson WG, Horrocks WH, Beveridge WWO, eds. Skin diseases. In: *Medical Services: Hygiene of the War*. London, England: His Majesty's Stationery Office; 1923: 68–72.

3. Pillsbury DM, Livingood CS. Dermatology. In: Havens WP Jr. *Infectious Diseases and General Medicine*. Vol 3. In: Anderson RS, ed. *Internal Medicine in World War II*. Washington, DC: US Government Printing Office; 1968: 568–607.

4. Sanderson PH, Sloper JC. Skin disease in the British Army in SE Asia. Part 2. Tinea corporis: Clinical and pathological aspects, with particular reference to the relationship between *T inderdigitale* and *T mentagrophytes*. *Br J Dermatol*. 1953;65:300–309.

5. Allen AM. Skin Diseases in Vietnam, 1965–72. In: Ognibene AJ, ed. *Internal Medicine in Vietnam*. Vol. 1. Washington, DC: Medical Department, US Army, Office of The Surgeon General, and Center of Military History; 1977.

6. Blank H, Taplin D, Zaias, N. Cutaneous *Trichophyton mentagrophytes* infections in Vietnam. *Arch Dermatol*. 1969;99:135–144.

7. Davis CM, Garcia KL, Riordon JP. Dermatophytes in military recruits. *Arch Dermatol*. 1972;105:558–560.

8. Bronson DM, Desai DR, Barsky S, Foley SM. An epidemic of infection with *Trichophyton tonsurans* revealed in a 20-year survey of fungal infections in Chicago. *J Am Acad Dermatol*. 1983;8:322–330.

9. Babel DE, Baughman SA. Evaluation of the adult carrier state in juvenile tinea capitis caused by *Trichophyton tonsurans*. *J Am Acad Dermatol*. 1989;21:1209–1212.

10. Joly J, Delage G. Auger P, Ricard P. Favus: Twenty cases of indigenous cases in the province of Quebec. *Arch Dermatol*. 1978;114:1647–1648.

11. Allen AM, Taplin D. Epidemic *Trichophyton mentagrophytes* infections in servicemen: Source of infection, role of environment, host factors, and susceptibility. *JAMA*. 1973;226:864–867.

12. Gentry R, Tribelhorn D, Fitzpatrick JE. Atypical dermatophytosis acquired in the tropics. *J Assoc Mil Dermatol*. 1988;14:17–18.

13. Tanenbaum L, Taplin D, Lavelle C, Akers WA, Rosenberg MJ, Carmargo G. Sulconazole nitrate cream 1 percent for treating tinea cruris and corporis. *Cutis*. 1989;44:344–347.

14. Leyden JJ, Kligman AM. Interdigital athlete's foot: The interaction of dermatophytes and resident bacteria. *Arch Dermatol*. 1978;114:1466–1472.

15. André J, Achten G. Onychomycosis. *Int J Dermatol*. 1987;26:481–490.

16. Lefler E, Haim S, Merzbach D. Evaluations of direct microscopic examination versus culture in the diagnosis of superficial fungal infections. *Mykosen*. 1981;24:102–106.

17. Loenenthal K. Seventy per cent ethyl alcohol as skin cleanser for fungus culture. *Arch Dermatol*. 1964;89:725–729.

18. Strauss JS, Kligman A. An experimental study of tinea pedis and onychomycosis of the foot. *Arch Dermatol.* 1957;76:70–79.

19. Lambert DR, Siegle RJ, Camisa C. Griseofulvin and ketoconazole in the treatment of dermatophyte infections. *Int J Dermatol*. 1989;28:300–304.

20. Allen HB, Honig PJ, Leyden JJ, McGinley KJ. Selenium sulfide: Adjunctive therapy for tinea capitis. *Pediatrics*. 1982;69:81–83.

21. Robertson MH, Rich P, Parker F, Hanifin JM. Ketoconazole in griseofulvin-resistant dermatophytosis. *J Am Acad Dermatol*. 1982;6:224–229.

122. VanDersarl JV, Sheppard RH. Clotrimazole vs haloprogin treatment of tinea cruris. *Arch Dermatol*. 1977;113: 1233–1235.

23. Zaias N, Battistini F, Gomez-Urcuyo F, Rojas RF, Ricart R. Treatment of "tinea pedis" with griseofulvin and topical antifungal cream. *Cutis*. 1978;22:196–199.

24. Leyden JJ, Kligman AM. Aluminum chloride in the treatment of symptomatic athlete's foot. *Arch Dermatol.* 1975;111:1004–1010.

25. Qadripur SA, Horn G, Höhler T. Aur localwirksamkeit von ciclopiroxolamine bei nagelmykosen. *Arzneim Forsch*. 1981;31:1369–1372.

26. Klaschka F. Treatment of onychomycosis with naftifine gel. *Mykosen*. 1987;30(suppl 1):119–123.

27. Hersle K, Mobackern H, Moberg S. Long-term ketoconazole treatment of chronic acral dermatophyte infections. *Int J Dermatol*. 1985;24:245–248.

28. South DA, Farber EM. Urea ointment in the nonsurgical avulsion of nail dystrophies—A reappraisal. *Cutis*. 1980;25:609–612.

29. Dreizen S. Oral candidiasis. *Amer J Med*. 1984;77(4D):28–33.

30. Rebora A, Marples RR, Kligman AM. Erosio interdigitalis blastomycetica. *Arch Dermatol*. 1973;108:66–68.

31. Macura AB. Fungal resistance to antimycotic drugs: A growing problem. *Int J Dermatol*. 1991;30:181–184.

32. Kirkpatrick CH, Alling DW. Treatment of chronic oral candidiasis with clotrimazole troches. *N Engl J Med*. 1978;299:1201–1203.

33. Fredriksson T, Faergemann J. Semantics—Tinea versus pityriasis versicolor and *Pityrosporum orbiculare* versus *Malassezia furfur*. Which is proper? *Int J Dermatol*. 1984;23:110–111.

34. Faergemann J, Fredriksson T. Experimental infections in rabbits and humans with *Pityrosporum orbiculare* and *P ovale*. *J Invest Dermatol*. 1981;77:314–318.

35. Pillsbury DM, Hurley HJ. *Dermatology*. Philadelphia, Pa: WB Saunders; 1975: 621.

36. Bäck O, Faergemann J, Hörnqvist R. Pityrosporum folliculitis: A common disease of the young and middle-aged. *J Am Acad Dermatol*. 1985;12:56–61.

37. Quiñones CA. Tinea versicolor: New topical treatments. *Cutis*. 1980;25:386–388.

38. Rausch LJ, Jacobs PH. Tinea versicolor: Treatment and prophylaxis with monthly administration of ketoconazole. *Cutis*. 1984;34:470–471.

39. Ford GP, Ive FA, Midgley G. Pityrosporum folliculitis and ketoconazole. *Br J Dermatol*. 1982;107:691–695.

40. Babel DE, Pelachyk JM, Hurley JP. Tinea nigra masquerading as acral lentiginous melanoma. *J Dermatol Surg Oncol*. 1986;12:502–504.

41. Sayegh-Carreño R, Abramovits-Ackerman W, Girén GP. Therapy of tinea nigra plantaris. *Int J Dermatol*. 1989;28:46–48.

42. Adam BA, Soo-Hoo TS, Chong KC. Black piedra in West Malaysia. *Aust J Dermatol*. 1977;18:45–47.

43. Kalter DC, Tschen JA, Cernoch PL, et al. Genital white piedra: Epidemiology, microbiology, and therapy. *J Am Acad Dermatol.* 1986;14:982–993.

44. Coquilla BH, Kraus EW. Trichosporosis (white piedra): Four cases in the United States. *J Assoc Mil Dermatol*. 1983;9:27–29.