Chapter 20

COMMON SKIN DISEASES

PETER E. O'NEILL, M.D.*

INTRODUCTION

PSORIASIS
- **Clinical Features**
- **Types of Psoriasis**
- **Diagnosis**
- **Treatment**
- **Military Considerations**

LICHEN PLANUS
- **Clinical Features**
- **Pathogenesis**
- **Diagnosis**
- **Treatment**
- **Military Considerations**

ATOPIC DERMATITIS
- **Clinical Features**
- **Natural Course**
- **Complications**
- **Diagnosis**
- **Treatment**
- **Military Considerations**

URTICARIA
- **Clinical Features**
- **Types of Urticaria**
- **Diagnosis**
- **Treatment**
- **Military Considerations**

PSEUDOFOLLICULITIS BARBAE
- **Clinical Features**
- **Pathogenesis**
- **Diagnosis**
- **Treatment**
- **Military Considerations**

CUTANEOUS VIRAL INFECTIONS
- **Herpes Simplex Labialis**
- **Herpes Zoster**
- **Molluscum Contagiosum**
- **Warts**
- **Military Considerations**

SUMMARY

3 Claydon Road, Garden City, New York 11530; Assistant Clinical Professor, State University of New York at Stony Brook, Stony Brook, New York; formerly, Major, Medical Corps, U.S. Air Force; Dermatology Service, Wilford Hall U.S. Air Force. Medical Center, Lackland Air Force Base, Texas 78236

INTRODUCTION

Although common dermatoses are not generally considered to pose a significant threat to the health of an individual, they can become a major problem for an entire armed force. In harsh environments, such as one would encounter on a field of battle, these minor afflictions can become incapacitating, thus rendering an individual unfit for duty. In a large unit, this collective loss of fighting force could seriously impair the effectiveness of the unit as a whole. During the Vietnam conflict, dermatoses were the third-highest cause of hospital admissions for disease, and outpatient dermatology visits were double the number required for any other condition.[1,2] Clearly, skin diseases can have a staggering impact on military operations.

TABLE 20-1

MOST COMMON DIAGNOSES IN NEW PATIENTS SEEN AT DERMATOLOGY CLINIC, 17TH FIELD HOSPITAL, SAIGON, VIETNAM, JULY 1967 (% of total shown)

Diagnosis	No. of Cases	(%)
Pyoderma	47	(10.0)
Miliaria	43	(9.2)
Tinea	43	(9.2)
Verrucae	37	(7.9)
Eczematous dermatitis	26	(5.6)
Candidiasis	22	(4.7)
Infected eczematous dermatitis	20	(4.3)
Acne	18	(3.8)
Tinea versicolor	15	(3.2)
Urticaria	13	(2.8)
Contact dermatitis	11	(2.3)
Plantar warts	11	(2.3)
Alopecia areata	10	(2.1)
Pseudofolliculitis barbae	9	(1.9)
Psoriasis	7	(1.5)
Others	137	(29.2)
Total	469	(100.0)

Adapted from Allen AM. *Skin Diseases in Vietnam, 1965–72*. In: Ognibene AJ, ed. *Internal Medicine in Vietnam*. Vol 1. Washington, DC: Medical Department, US Army, Office of The Surgeon General and Center of Military History; 1977: 38.

TABLE 20-2

PROPORTIONATE DISTRIBUTION OF SKIN DISEASES SEEN IN U.S. DERMATOLOGY CLINIC, 95TH EVACUATION HOSPITAL, DA NANG, VIETNAM, 15 MAY 1970 TO 31 JULY 1971 (14.5 MONTHS) (% of total shown)

Disease	No. of Cases	(%)
Verrucae, all types	729	(15.83)
Acne, all types	466	(10.12)
Dermatophytosis, all types	371	(8.06)
Pseudofolliculitis barbae	289	(6.28)
Penile ulcer [? chancroid]	221	(4.80)
Miliaria	199	(4.32)
Pyoderma, all types	178	(3.87)
Contact dermatitis	167	(3.63)
Urticaria	126	(2.74)
Tinea versicolor	123	(2.67)
Psoriasis	106	(2.30)
Atopic dermatitis	95	(2.06)
Dyshidrosis	95	(2.06)
Alopecia areata	82	(1.78)
Monilia	71	(1.54)
Lichen planus	70	(1.52)
Herpes progenitalis	68	(1.48)
Seborrheic dermatitis	56	(1.22)
Miscellaneous dermatoses and dermatitides	51	(1.11)
Insect bites	48	(1.04)
Molluscum contagiosum	41	(0.89)
Sebaceous cyst	40	(0.87)
Pityriasis rosea	39	(0.85)
Hand and foot eczema	37	(0.80)
Lichen simplex chronicus	35	(0.76)
Syphilis infection, late and early	33	(0.72)
Erythema multiforme	32	(0.69)
Nevi	32	(0.69)
Balanitis	31	(0.67)
Basal cell epithelioma	25	(0.54)
Keloids	24	(0.52)
Corns and calluses	24	(0.52)
Drug eruptions	21	(0.45)
Vitiligo	20	(0.43)
Photoallergy	15	(0.33)
Nummular eczema	14	(0.30)
Pruritus	14	(0.30)
No diagnosis	56	(1.22)
Others	461	(10.02)
Total	4,605	(100.00)

Adapted from Allen AM. *Skin Diseases in Vietnam, 1965–72*. In: Ognibene AJ, ed. *Internal Medicine in Vietnam*. Vol 1. Washington, DC: Medical Department, US Army, Office of The Surgeon General and Center of Military History; 1977: 39.

TABLE 20-3

DERMATOLOGY ADMISSIONS TO A BRITISH GENERAL HOSPITAL DURING WORLD WAR I

	1915		1916						
	Nov	Dec	Jan	Feb	Mar	Apr	May	Jun	Total
Impetigo	122	172	151	161	220	170	147	116	1,259
Scabies	95	770	170	8	25	5	9	23	1,105
Boils	24	59	50	51	42	36	65	48	375
Pediculosis	–	17	62	69	36	3	5	6	198
Psoriasis	11	24	17	17	29	21	36	29	184
Eczema	7	22	18	11	37	22	33	31	181
Seborrhoea	8	12	13	11	40	18	18	11	131
Acne	6	22	19	12	8	6	10	7	90
Dermatitis	7	10	10	11	11	8	8	7	72
Syphilis	8	13	4	3	6	4	17	16	71
Folliculitis	1	11	13	9	8	2	5	1	50
Urticaria	2	4	3	3	2	11	8	1	34
Sycosis	4	2	4	1	3	2	5	7	28
Pityriasis rosea	3	2	2	5	3	2	2	3	22
Erythema	3	7	5	–	4	1	–	1	21
Carbuncle	2	4	3	1	4	2	1	2	19
Herpes zoster	2	2	2	–	3	3	1	–	13
Lupus	–	–	2	–	–	3	2	2	9
Erysipelas	–	–	–	–	1	–	1	2	4
Ecthyma	–	–	1	2	–	–	–	–	3
Lichen planus	–	–	1	1	–	–	1	–	3
Erythema nodosum	–	–	–	–	–	–	–	2	2
Ichthyosis	–	–	1	–	–	–	–	1	2
Sudamina	–	–	–	–	–	–	–	2	2

Adapted from Macpherson WG, Herringham WP, Elliott TR, Balfour A, eds. Medical services. Diseases of the war. In: *History of the Great War*. Vol 2. London, England: His Majesty's Stationery Office; 1923: 68.

One might expect the largest category of dermatologic casualties to be composed of exotic tropical diseases; however, the greatest number of casualties has been related to common skin maladies. Experience from previous battles clearly indicates that common dermatoses are a major source of ineffectiveness and temporary disability among battlefield personnel. Pillsbury and Livingood[3] reported that the entire group of rare dermatoses was of no significance in the total disability from skin diseases in World War II. Statistics available from Vietnam and World War I (Tables 20-1 through 20-3) support a similar conclusion.[3,4] It is apparent from these experiences that many casualties can be averted in the future if more military medical personnel are trained in the recognition and management of some common skin diseases.

Tables 20-1 through 20-3 list a number of skin diseases that were discussed in previous chapters, such as impetigo (Chapter 13, Bacterial Skin Diseases), scabies (Chapter 8, Arthropod and Other Animal Bites), and miliaria (Chapter 3, Skin Diseases Associated with Excessive Heat, Humidity, and Sunlight). This chapter will address common dermatoses that did not fit in the previous chapters of this textbook.

PSORIASIS

Psoriasis is a common, genetically determined, inflammatory skin disease characterized by distinctive lesional morphology and distribution. It affects men and women equally[5] and typically runs a chronic course that is marked by frequent relapses. It occurs worldwide and affects approximately 1% of the population in the United States.[6] Psoriasis can have its onset at any age, but is most likely to appear in early adulthood.[7] Although its exact etiology is unknown, it is clear that psoriatic skin is in a hyperproliferative state with a marked increase in the rate of keratinocyte replication.[8–10]

Fig. 20-1. Psoriasis. (**a**) Large, geographic plaques. Note how lesions suggest the coastline of a map. (**b**) Note symmetry and extensive involvement of lesions. (**c**) Lichenified geographic plaques in obese individual. (**d**) Characteristic silvery scale.

Clinical Features

Psoriasis is a classic example of a papulosquamous disease, characterized by erythematous papules and plaques with a silvery scale. The disorder can vary from a focal disease consisting of localized lesions to a widespread eruption and even a generalized erythroderma with exfoliation.[11,12]

The characteristic early lesion of psoriasis is an erythematous papule with a scale that can be subtle but is usually obvious. Typically, the papules gradually expand and coalesce to form sharply demarcated, symmetrically distributed plaques (Figure 20-1). Frequently, the plaques become surrounded by a thin zone of perilesional blanching, known as a Woronoff ring. This ring is most frequently seen in the early stages of resolution in ultraviolet (UV) light therapy (Figure 20-2). Although some authorities[13] have shown evidence of prostaglandin inhibition to explain this phenomenon, the precise mechanisms involved are likely to be more complex.[14]

Psoriasis can occur at any cutaneous site, although it has a predilection for the scalp, elbows, knees, extensor aspects of the extremities, and the nails. It also frequently involves the penis (Figure 20-3). Oral lesions are unusual in psoriasis; however, some authorities[15–17] believe that the condition known as geographic tongue (Figure 20-4) may actually be a manifestation of psoriasis, because the histological features are identical. Occasionally, only intertriginous areas are involved (inverse psoriasis). When one suspects a diagnosis of psoriasis, it is often helpful to inspect the intergluteal cleft for involvement (Figure 20-5). A typical feature of psoriasis is Köebner's phenomenon, the appearance of lesions in scars or other sites of trauma.[18] The lesions may appear in sites of old, major trauma such as surgical scars or in areas of recent or minimal injury such as an abrasion. The cause of this phenomenon is not known, although recently, speculation has focused on microbial factors.[19]

The scale in psoriasis is typically silvery white and stacked in layers. In this way, the scale is said to be micaceous (slatelike). When the scale is removed with curettage or scraping, pinpoint bleeding may be noted. This is known as the Auspitz sign. It is more common, however, to observe a loose scale that easily flakes off in patients with long-standing lesions. Although traditionally con-

Fig. 20-3. Psoriasis on the penis. Note the paucity of scale.

Fig. 20-2. Woronoff's rings. Note the zones of hypopigmentation outlining the resolving psoriatic plaques in this patient undergoing ultraviolet-B phototherapy.

Fig. 20-4. Annular and arcuate pustular lesions of geographic tongue.

sidered a hallmark of psoriasis, the Auspitz sign's sensitivity and specificity have been questioned by Bernhard, who elicited the sign in several nonpsoriatic, scaling disorders.[20]

When examining a patient with presumed psoriasis, one should always examine the fingernails and toenails, which frequently reveal diagnostic clues (Figure 20-6). Onycholysis—separation of the distal free edge of the nail plate from the nail bed—is a frequent finding. Less common, but more specific, is nail pitting—actual punctate depressions on the surface of the plate. The most specific nail finding, often said to be pathognomonic, is the so-called "oil spot," which describes a yellowish brown, irregular macule beneath the nail plate and represents involvement of the nail bed with psoria-

Fig. 20-5. Annular erythematous plaque with fine surface scale in the intergluteal cleft. This is a common site for psoriasis.

Fig. 20-6. Psoriatic nails. (**a**) Pitting, thickening, and discoloration. (**b**) Pitting, distal onycholysis, and "oil spot." (**c**) Distal onycholysis and "oil spots" in patient with large psoriatic plaques. (**d**) Onycholysis, discoloration, and crumbling of nail plate. Photograph c: Courtesy of Dr. Charles Trapp, MacDill Air Force Base, Fla.

sis. When the nail matrix is involved, severe onychodystrophy can result, with diffuse crumbling and yellowing of the plate. In pustular psoriasis and acrodermatitis continua of Hallopeau, one commonly observes subungual pustules.

Types of Psoriasis

Psoriasis Vulgaris

Psoriasis Vulgaris is the most frequent presentation of psoriasis, consisting of chronic, stable, well-defined plaques that may persist for years. While the plaques can occur on any cutaneous surface, they are most likely to appear in the areas of predilection described above.

Guttate Psoriasis

Guttate psoriasis most commonly occurs in young adults and is usually eruptive in onset. It consists of multiple, small, guttate (raindroplike) lesions over the trunk and proximal extremities (Figure 20-7). Frequently, careful history-taking will reveal an antecedent streptococcal pharyngitis or viral respiratory infection.[21]

Localized Pustular Psoriasis

Localized pustular psoriasis consists of two types: pustular psoriasis of the palms and soles, known as pustulosis palmoplantaris (Figure 20-8), and acrodermatitis continua of Hallopeau. Both forms present with pustules, the former involving the palms and soles, and the latter involving the distal fingers and toes with severe nail dystrophy (Figure 20-9). Both conditions are noted for chronicity and refractoriness to treatment. When severe, either can be disabling. Pustulosis palmoplantaris has been associated with arthritis of the anterior chest wall,[22] cigarette smoking, and thyroid disease.[23]

Generalized Pustular Psoriasis

Generalized pustular (von Zambusch) psoriasis is one of the rarer presentations of psoriasis,[24,25] marked by acute attacks of generalized pustules on erythematous skin and associated with fever, leukocytosis, and systemic toxicity. This disease can be fatal, so hospitalization is mandatory. Several provocative factors are claimed to precipitate attacks, but the most important to consider is the association with steroid withdrawal (ie, systemic and potent topical steroids).[25,26]

Fig. 20-7. Guttate psoriasis. Note scattered distribution of discrete, small, erythematous papules and plaques with scale.

Psoriatic Arthritis

Psoriatic arthritis is an inflammatory, sero-negative arthritis clearly associated with psoriasis (Figure 20-10).[27] It has been neatly classified into five general categories (Table 20-4).[28]

Diagnosis

When chronic, scaling plaques are present on extensor surfaces or on the penis or scalp, the diagnosis is usually obvious. Occasionally, however, psoriasis can mimic other papulosquamous disorders: seborrheic dermatitis, lichen planus, pityriasis rosea, pityriasis rubra pilaris, drug eruptions, or even syphilis. Isolated lesions may be confused with lichen simplex chronicus, nummular dermatitis, cutaneous lupus erythematosus, or mycosis fungoides. When one suspects the diagnosis of psoriasis, it is essential to perform a thorough cutaneous exam looking for clues such as nail involvement, evidence of Köebner's phenomenon, or pinking of the intergluteal cleft. Obtaining a family history can also provide useful information. If doubt still exists, biopsy should be obtained because the histopathological features are fairly distinctive.

Treatment

Numerous modalities are available for the treatment of psoriasis. This fact speaks for the complexity of the disease, the mystery of its pathogenesis, and the limitations of all of the available treatments.

Fig. 20-8. (**a**) Psoriasis of the palms. (**b**) Psoriasis of the soles. (**c**) Pustulosis plantaris. (**d**) Close-up view of (c) to reveal characteristic yellow-brown pustules.

Fig. 20-9. Scaling and crusted lesions with border of peripheral pustules on the distal digits, characteristic of acrodermatitis continua of Hallopeau.

a

b

c

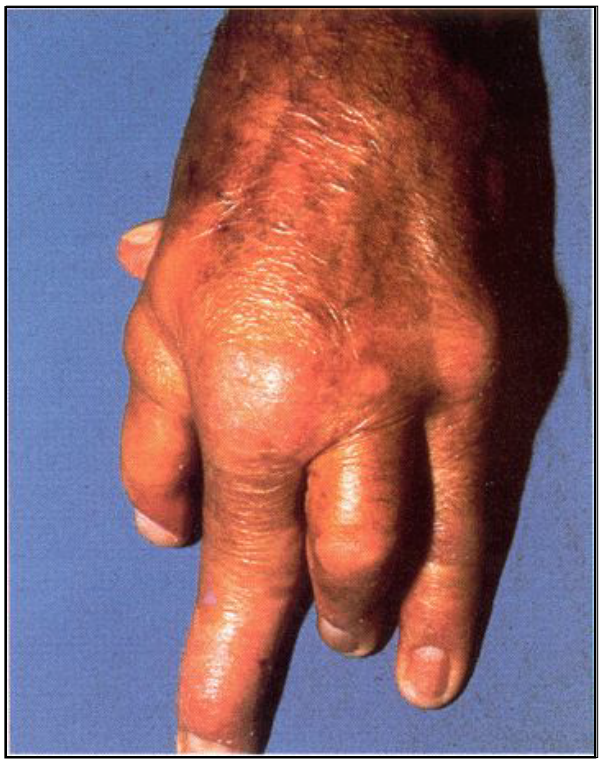

Fig. 20-10. Psoriatic arthritis. (**a**) Proximal interphalangeal joint of finger. (**b**) Toe involvement—"sausage digit." (**c**) Severe involvement of fingers and hand.

TABLE 20-4

ARTHRITIS IN PSORIASIS

Type of Arthritis	Characteristics
Asymmetric involvement of a few joints of the fingers	Affects 70% of patients with psoriatic arthritis; "sausage digit"
Symmetric polyarthritis	Affects 15% of patients with psoriatic arthritis; resembles rheumatoid arthritis (seronegative)
Distal interphalangeal joint involvement	Affects 5% of patients with psoriatic arthritis; "classic" psoriatic arthritis
Arthritis mutilans	Affects 5% of patients with psoriatic arthritis; deforming arthritis with bony destruction, telescoping of digits, and ankylosis
Ankylosing spondylitis	Affects 5% of patients with psoriatic arthritis; may also have peripheral joints involved

Data source: Moll JMH, Wright V. Familial occurrence of psoriatic arthritis. *Ann Rheum Dis*. 1973;22:181.

There clearly is no treatment of choice in the management of psoriasis. Many new modalities have been described recently, such as vitamin D,[29] fish oil,[30] and cyclosporine.[31] At this point, these therapies should be considered investigational. Medical officers are advised to consider first the more traditional, time-honored modalities available.

No treatment is without side effects. The risks for adverse side effects can often be reduced by combination therapy, such as retinoids combined with psoralen and UV-A (PUVA). The advantage of combination therapy is that the cumulative dose of each agent is diminished. Thus, while the beneficial effects may be additive, the adverse effects are usually decreased. Furthermore, when approaching the treatment of psoriasis, one must realize that the aim of treatment should not be to obtain complete clearing. That is often an unrealistic approach in the management of psoriasis. Complete clearing is often unattainable without experiencing significant toxicity. Realistic expectations by the physician as well as the patient are perhaps the most important aspects of therapy.

Topical Corticosteroids

Topical corticosteroids are frequently employed in the management of psoriasis and can be quite beneficial. Due to a potent antiinflammatory effect and inhibition of deoxyribonucleic acid (DNA) synthesis (with a subsequent antiproliferative effect), topical steroids are a logical and effective modality in this disease. Intralesional steroids may be considered for isolated or resistant plaques. The limiting factor for topical corticosteroids is epidermal and dermal atrophy, which can result in marked thinning of the skin and striae formation (Figure 20-11). More importantly, sustained use of potent topical steroids can lead to suppression of the hypothalamic-pituitary-adrenal axis.[32,33] Pulse dosing may permit extended maintenance with potent topical steroids while limiting adverse effects.[34] Another drawback to consider regarding steroid therapy is the development of tachyphylaxis. For these reasons, one is encouraged to consider alternative topical agents for the treatment of psoriasis.

Fig. 20-11. Linear atrophic striae on the back of this patient, who is taking oral steroids.

Anthralin

Anthralin is a synthetic anthrone derivative that reduces mitotic activity and suppresses free radicals. It is widely used in Europe as an integral component of the Ingram regimen, which consists of a daily coal tar bath followed by suberythemogenic UV-B exposure, then the application of dithranol paste of gradually increasing concentration.[5] Although this method is quite effective and safe, it is cumbersome. For this reason, short-contact anthralin treatment plans have been devised,[35] frequently with the addition of coal tar[36,37] to diminish the irritancy of anthralin, which can limit its use. Due to its lack of systemic toxicity, carefully supervised anthralin therapy combined with thorough patient explanation and education is an ideal modality for the treatment of chronic plaque-type psoriasis.

Coal Tar

Coal tar has been widely employed in the treatment of psoriasis for more than a century. It is a complex mixture of over 10,000 substances,[38] which may possess antimitotic activity.[39] Coal tar gained popularity after introduction of a simple method described by Goeckerman in 1925,[40] which consists of continued application of 2% crude coal tar, which is removed with mineral oil once daily for UV-B exposure. The tar is reapplied after bathing.

Coal tar is an extremely safe agent. The most frequent side effect is a tar-induced folliculitis. There have been reports of skin cancers associated with coal tar application[41,42]; however, this is an uncommon event, and such case reports usually involve patients who have been exposed to multiple other skin cancer–inducing agents.

Systemic Methotrexate

Methotrexate, given in weekly oral doses of 5 to 25 mg, is an extremely valuable agent for treating severe psoriasis and psoriatic arthritis that are not adequately controlled by more conventional therapies. It is a folate antagonist that exerts its antiproliferative effect on psoriatic epidermal cells by directly inhibiting DNA synthesis.[43]

Methotrexate is absolutely contraindicated in pregnant or lactating females. Relative contraindications are many, including liver or renal abnormalities, excessive alcohol consumption, and anemia, leukopenia, and thrombocytopenia. Guidelines for appropriate use of methotrexate in psoriasis are published periodically by the Psoriasis Task Force of the American Academy of Dermatology.[44] Medical officers should be thoroughly knowledgeable with these guidelines before considering methotrexate for the treatment of psoriasis. The greatest limitation of methotrexate is its hepatotoxicity. For this reason, newer folate antagonists with perhaps fewer effects on the liver are being investigated.[45]

Systemic Retinoids

The retinoids are synthetic derivatives of vitamin A and vitamin A acid. The effects of vitamin A and vitamin A analogs on the growth and terminal differentiation of epidermal cells and the vitamin's beneficial effect on disorders of keratinization have long been known. Retinoids have been shown to affect growth of epidermal cells by altering keratin synthesis and formation of the cell envelope.[46]

Etretinate (0.5–1.0 mg/kg/d) is the retinoid approved for use in the treatment of psoriasis. It should be considered for initial treatment in the management of pustular psoriasis or erythrodermic psoriasis.[47] It is also beneficial for the patient with extensive plaques and severe involvement recalcitrant to more conventional modalities and has been successful in clearing acrodermatitis continua of Hallopeau.[48]

Etretinate has significant risk for adverse effects including teratogenicity, elevation of serum lipids, liver toxicity, and numerous mucocutaneous side effects. In addition, cases of skeletal hyperostoses have been documented with long-term use.[49] Furthermore, it is known to be stored in adipose tissue for long periods, thus leading to a prolonged half-life (> 100 d).[50] In fact, blood levels are detectable for more than 2 years after discontinuation of therapy. For these reasons, in addition to its potent teratogenicity, etretinate is best avoided in women of child-bearing potential. Alternatives include isotretinoin and, once available, acitretin—the main metabolite of etretinate—which has been shown to be effective in treating psoriasis and has a much shorter half-life (50 h for acitretin vs 120 d for etretinate).[51] Because the side effects of acitretin are similar to those of etretinate, including potent teratogenicity, effective contraception is essential for women and long-term use is discouraged. Because risks are greatly increased with long-term use of retinoids, they are probably best used in combination with other modalities such as phototherapy.

Ultraviolet-B Phototherapy

Natural sunlight has long been known to improve psoriasis. An excellent (and more reliable) substitute is an artificial light source that produces light primarily in the ultraviolet-B (UV-B) range (290–320 nm). This allows for continuous monitoring and metered delivery of UV radiation, thus diminishing the potential for accidental overexposure and burning. Although the mechanism of the therapeutic effect is unknown, UV-B alone or with coal tar is an excellent method for clearing psoriasis and maintaining remission. Its use should be considered early in the course of management.

Psoralen and Ultraviolet-A Phototherapy

Introduced in 1974 by Parrish and Fitzpatrick,[52] PUVA phototherapy has gained worldwide acceptance in the treatment of psoriasis. Patients ingest a specific dose of methoxsalen (consult chart in package insert for precise dosage based on weight), followed in approximately 90 minutes by a carefully metered UV-A (320–400 nm) exposure, which is increased with progressive treatments. Initially, Oxsoralen was the drug employed. This has now been replaced by Oxsoralen-Ultra (methoxsalen, manufactured by ICN Pharmaceuticals, Inc., Costa Mesa, Calif.), a liquid form in a gel capsule that provides more uniform serum drug levels.[53] Patients are treated two to three times per week, and generally respond within 20 to 25 treatments. PUVA can then be continued and gradually tapered to maintain prolonged remission.

PUVA exerts its effect through the production of bifunctional DNA adducts and subsequent inhibition of DNA synthesis and epidermal cell replication.[54] It is an excellent modality for managing severe psoriasis on an outpatient basis. However, it is not without risk. Patients must wear protective eyewear (wraparound UV-A filtering glasses) for 24 hours after ingestion of the drug to prevent cataracts. It has been well documented that PUVA is clearly associated with an increased risk for nonmelanoma skin cancer, particularly squamous cell carcinoma.[55,56] The study by Fitzpatrick and Parrish[55] reveals that the risk of developing squamous cell carcinoma increases with cumulative PUVA exposure. The higher exposure group (> 260 treatments) has a risk that is 12-fold that of the lower exposure group (< 160 treatments) and 100-fold that of the general population.[55] This fact emphasizes the point made previously: the goal of therapy when managing psoriasis should not be 100% clearing. Ninety percent clearing is, generally, much easier to attain and maintain at far less risk, and this is usually quite acceptable to the patient. Clearly, PUVA should not be used unless the patient's psoriasis is severe. While PUVA-induced squamous cell carcinoma has little potential for metastatic spread, all patients receiving PUVA must be carefully monitored to ensure early detection and prevention of disfigurement. All men should shield the genital region during therapy, as this area has proven to be at particular risk for developing PUVA-induced tumors.[57]

PUVA-associated carcinogenesis may possibly be avoided by employing PUVA bath treatments using a trioxsalen solution. This technique has been used extensively in Europe and has been shown to be of equal efficacy[58] to and probably safer than standard PUVA.[58–60] This author has found a similar technique using a solution of Oxsoralen, as described by Coleman et al,[61] to be extremely effective in the management of pustulosis palmoplantaris. All forms of PUVA may be combined with other treatments such as retinoids to obtain superior results while diminishing adverse effects.

Military Considerations

The main point to emphasize to the military physician regarding psoriasis is its tendency towards chronicity and its sometimes unpredictable course. Consider the individual with mild plaque-type psoriasis who is easily controlled with anthralin and intermittent UV-B therapy. That same individual deployed to a northern climate or hostile environment may experience a significant flare-up requiring medical evacuation and preventing mission completion. This author has observed this scenario repeatedly. In World War II, dermatologists found that approximately 20% of psoriatic patients became liabilities and questioned whether troops with significant psoriasis should ever be sent overseas.[62] In U.S. Army medical clinics in Vietnam, psoriasis accounted for up to 6% of outpatient visits.[2] Individuals with psoriasis of even mild severity should be considered for presentation to a medical evaluation board for determination of worldwide qualification.

Another point to consider about psoriasis in the military is a controversial one: the role of antimalarial chemoprophylaxis in inducing exacerbations of psoriasis.[63] This author witnessed one case of a young sailor who experienced a pustular flare-up of his psoriasis while on chloroquin prophylaxis. This required medical evacuation from a

ship and a prolonged hospital course, including an initial stay in the intensive care unit. While this is anecdotal, it illustrates the argument for reconsidering worldwide eligibility for all military members with psoriasis. Kuflik reported on 48 U.S. Army patients with psoriasis on prophylactic chloroquin in Vietnam: 42% of the cases worsened, but only 6% had significant flare-ups.[64]

LICHEN PLANUS

Lichen planus (LP) is an inflammatory skin disease that is often pruritic, with distinctive mucocutaneous findings. In 1969, Erasmus Wilson published a series of 50 cases describing the classic features of LP.[65] The prevalence of LP in the general population is estimated to be 0.13% to 0.34% for cutaneous involvement and 0.19% to 1.5% for oral involvement.[66] In a study of over 670,000 patients in the United States, LP was seen in 0.44%.[67] In a general dentistry clinic, oral LP was seen in 0.6%.[68]

LP predominantly afflicts people in their middle ages, with approximately two thirds of those affected between the ages of 30 and 60.[67] It is worldwide in its distribution with no racial predisposition. Both sexes are affected approximately equally. Familial cases have been reported.[69,70]

Clinical Features

The characteristic lesion of LP is a flat-topped, shiny, polygonal papule that is most often described as violaceous in color. Individual papules range in size from pinpoint to greater than 1 cm and may remain discrete or become confluent. Frequently, one can observe fine, reticulate white streaks on the surface. These streaks, known as Wickham's striae, are most easily seen with the use of mineral oil and

Fig. 20-12. Lichen planus. (**a**) Ankle. Note violaceous, flat papules with reticulated white scale. (**b**) Flexor surface of the wrist, a common location. (**c**) Dorsum of hand. (**d**) Close-up of (a) to demonstrate Wickham's striae.

the aid of a hand-held lens. Köebner's phenomenon is sometimes observed.[18,71]

LP may remain a localized process or have a generalized distribution. When LP becomes generalized it usually does so within the first month of onset and is typically symmetric in its distribution. The majority of cases begin on the extremities, especially the ankles[72] and the flexor aspects of the wrists (Figure 20-12).[73] The ankles and shins are the most common sites for hypertrophic lesions.[74] Other cutaneous sites commonly involved include the lumbar region and the penis; the latter site may have annular or ulcerative lesions (Figure 20-13). Erosive and ulcerative forms of LP can also be found on other mucous membranes as well as on the palms, soles, and arms (Figure 20-14).[75,76]

The natural course of LP is usually spontaneous resolution—93% within 2 years in Samman's study.[77] Among this same series of patients, the rate of relapse was 20%. Typically, marked postinflammatory hyperpigmentation, hypopigmentation, or both will occur as lesions regress.[78]

Nail involvement is seen in 10% of cases.[77] This is most commonly manifested as surface roughness or flaking with longitudinal ridging. Other changes include brownish discoloration, pitting, and thinning of the nail plate with splitting of the free edge. Chronic nail involvement can result in pterygium formation as a result of the growth of the cuticle and subsequent adherence to the nail bed, resulting in permanent loss of the nail plate. Occasionally, the nails may be the only site of involvement.[79,80] These cases normally require histological confirmation for diagnosis. Twenty-nail dystrophy, a disorder of acquired dystrophic nail changes in children, may be a manifestation of LP.[81,82] Several other variants of cutaneous LP exist (Exhibit 20-1).

Fig. 20-13. Annular lichen planus on the penis—a common location. Note violaceous border and central hyperpigmentation.

Fig. 20-14. Annular lichen planus on the arm. Note the central hyperpigmentation and characteristic violaceous border with slight scale.

Involvement of oral mucosa is very common in LP. In Altman and Perry's series of 197 patients, 40% had cutaneous and mucosal involvement, and 25% had oral alone.[83] Oral lesions can be found in up to 71% of LP patients seen in dermatology clinics.[77,83]

Oral LP typically involves buccal mucosa, although other sites can be involved. These include

EXHIBIT 20-1

VARIANTS OF CUTANEOUS LICHEN PLANUS

Hypertrophic lichen planus
Linear lichen planus
Annular lichen planus
Atrophic lichen planus
Lichen planus subtropicus (actinicus)
Bullous lichen planus
Lichen planopilaris
Lichen planus pemphigoides
Lichen planus–lupus erythematosus overlap
Ulcerative lichen planus
Hepatitis-associated lichen planus

Fig. 20-15. Oral lichen planus. (**a**) Characteristic reticulate, white plaque on the buccal mucosa—the most commonly involved site. (**b**) Involvement of the lower lip.

the tongue, gingiva, and vermilion border of the lip (Figure 20-15).[84] Involvement of the palate and sublingual region is rare. Almost always, oral LP occurs bilaterally. The appearance of LP in the oral mucosa can be quite varied. The most common morphology is that of a plaque consisting of slightly elevated, very fine white lines in a reticulate pattern, similar to Wickham's striae. This has been referred to as "Honniton lace." Other forms include a papular variant or a plaquelike form (resembling leukoplakia), an atrophic form (resembling erythroplakia), bullae (rare), and an erosive form.[84] Erosions are often extensive and can result in desquamative gingivitis.[85]

The natural course of oral LP is one of chronicity, with a mean duration of almost 5 years.[72] Oral LP has been shown to persist for more than 25 years.[85] Persistent, erosive, oral LP may have a potential for the development of squamous cell carcinoma, although this is controversial.[86–89] Some authorities[88] consider oral LP to be a premalignant condition.

Pathogenesis

The precise etiology of LP remains unknown despite intensive investigation. Multiple hypotheses support numerous etiologies, including infectious agents, tobacco, betel nuts, psychogenic stress, chemicals, and numerous drugs. Some cases of LP have occurred in patients with diabetes, hepatitis,[89,90] hepatic biliary cirrhosis,[91] hypertension, and urolithiasis. While the exact triggering mechanism for LP remains unknown, recent work strongly implicates T-cell–mediated cytotoxicity as the final common pathway leading to the development of the lesion of LP.[92,93] Norris[94] recently demonstrated marked staining for ICAM-1 (intercellular adhesion molecule-1) of basal cells in skin from lesions of lichen planus. One could propose that this would lead to binding between the basal keratinocytes and T lymphocytes within the dense dermal infiltrate, resulting in the cytotoxic destruction of the keratinocytes.

Diagnosis

Lichen planus has a rather distinctive clinical presentation. Other entities to consider in the differential diagnosis are lichenoid drug eruptions, psoriasis, syphilis, and LP-like keratoses. When the skin lesions suggest a diagnosis of LP, always examine the mouth, which will frequently reveal the characteristic white, reticulate plaques typical of LP. Oral lesions, in the absence of cutaneous findings, may be confused with candida, traumatic erosions, aphthae, leukoplakia, or bullous diseases such as pemphigus vulgaris or erythema multiforme. Biopsy will usually confirm the diagnosis of LP, which has specific histological features. History is the most important feature to distinguish a lichenoid drug eruption from LP.

Treatment

The mainstay of therapy for LP is corticosteroids. In localized forms, potent topical steroids or

steroids applied under occlusion may be beneficial. Large plaques generally respond to intralesional triamcinolone (3–5 mg/mL). Generalized or eruptive LP usually requires systemic steroid therapy. Alternatives to consider are PUVA[95,96]; retinoids[97,98]; and griseofulvin (125–250 mg twice daily), which has been reported to have a cure rate as high as 90%,[99,100] although other reports show it to be completely ineffective.[101] Oral lesions may respond to topical steroids in Orabase (gelatin, pectin; manufactured by Colgate-Hoyt, Canton, Mass.) or aerosolized betamethasone valerate. Recently, two groups[102,103] have reported significant improvement of oral LP using a topical cyclosporine rinse with no systemic adverse effects and little systemic absorption over a 2-month period. However, the cost of cyclosporine may prove prohibitive.

In addition, antihistamines and antipruritic lotions may be useful and should be employed for relief of pruritus.

Military Considerations

Although LP is generally considered to be a benign, self-limited disease, the pruritus that usually accompanies it may interfere with performance of duty. It is important, then, to treat symptomatic patients aggressively to keep them functional.

Of historical significance is the widely reported relationship of atypical LP with the administration of quinacrine for antimalarial prophylaxis in World War II.[104–107] The study by Bazemore et al[104] of 400 patients reveals that long-term therapy with antimalarials is necessary to induce atypical LP, as only 20% of patients developed the disease within 3 months, while 80% developed the disease within 7 months. Many cases were complicated by a secondary pyoderma—usually caused by *Streptococcus pyogenes* and *Staphylococcus aureus*. This most likely was a result of inadequate hygiene in a tropical environment. The eczematous process frequently involved the hands, thus disqualifying many individuals from full military duty. On return to duty, relapse was almost certain, so prompt evacuation became the treatment of choice.[62]

A variant of LP rarely seen in the United States that could potentially be of significance for deployed military personnel is LP subtropicus (actinicus). This is common in the Middle East and consists of annular lesions on sun-exposed surfaces, particularly the face.[108–110] The course is chronic and the condition worsens with sun exposure. Treatment consists of using sun blockers and limiting sun exposure.

ATOPIC DERMATITIS

Atopic dermatitis is an environmentally induced disorder occurring in genetically predisposed individuals. It is characterized by acute episodes of eczematous cutaneous eruptions with characteristic distribution, usually accompanied by xerosis. The disorder may be considered part of the atopic diathesis that also includes allergic rhinitis, conjunctivitis, and asthma. It is prevalent worldwide and is more common among children, particularly of industrialized countries. Its incidence in England is 1.1% to 3.1%.[111,112] In the United States it is 0.7 to 2.4%.[113]

Clinical Features

The clinical features of atopic dermatitis can be classified into major features that are seen in most atopic patients and minor, nonspecific features that are frequently seen in atopic patients (Exhibit 20-2).[114] There is no primary lesion of atopic dermatitis. The lesions are eczematous and marked by erythema, weeping, scaling, crusting, and lichenification (thickening of skin in response to continual rubbing). Often, the lesions may be excoriated or secondarily infected. Atopic dermatitis is recognized by observing these findings in a typical pattern of distribution. In infants and children under 2 years of age, the lesions typically occur on the face (Figure 20-16) and extensor surfaces. Paradoxically, in older children and adults, the characteristic pattern is that of predominantly flexural involvement with sparing of the face (Figure 20-17).

History is extremely helpful in establishing the diagnosis of atopic dermatitis. The age of onset is usually in childhood—60% within the first year of life.[115] Seventy percent of patients will have a history of asthma, hay fever, or both.[114] A family history of atopy is almost always present.

EXHIBIT 20-2

CLINICAL FEATURES OF ATOPIC DERMATITIS

Major Features

- Pruritus
- Flexural lichenification in adults
- Facial and extensor involvement in infants and children
- Chronic or chronically relapsing dermatitis
- Personal or family history of atopy (asthma, allergic rhinitis, atopic dermatitis)

Minor Features

- Xerosis
- Ichthyosis, palmar hyperlinearity, keratosis pilaris
- Immediate (type 1) skin test reactivity
- Elevated serum immunoglobulin E
- Early age of onset
- Tendency toward cutaneous infections (especially with *Staphylococcus aureus* and herpes simplex virus), impaired cell-mediated immunity
- Tendency toward nonspecific hand or foot dermatitis
- Nipple eczema
- Cheilitis
- Recurrent conjunctivitis
- Dennie-Morgan infraorbital fold
- Keratoconus
- Anterior subcapsular cataracts
- Orbital darkening
- Facial pallor, facial dermatitis
- Pityriasis alba
- Anterior neck folds
- Pruritus when sweating
- Intolerance to wool
- Perifollicular accentuation
- Food intolerance
- Course influenced by environment or emotional factors
- White dermographism, delayed blanch

Data source: Hanifin JM. Clinical and basic aspects of atopic dermatitis. In: *Seminars in Dermatology*. New York, NY: Thoieme-Stratton, Inc; 1983: 25–29.

Fig. 20-16. Atopic dermatitis in an infant most commonly involves the face, with perioral sparing.

Natural Course

The natural course of atopic dermatitis is one of repeated episodes of acute flare-ups, followed by a subacute phase of slow resolution.[116] Acute episodes tend to occur in response to psychic or emotional stress. In a study in which more than 500 patients were interviewed, stress was considered the primary precipitating factor.[117] Between flare-ups, patients will often be bothered by generalized xerosis, which often is quite pruritic and creates an intolerance of the skin for exposure to solvents, soaps and other cleansers, and water (in excessive amounts).

Fig. 20-17. Atopic dermatitis in a young adult, with typical involvement of antecubital fossae and marked symmetry.

Hand dermatitis is frequently seen in patients with atopic dermatitis, particularly adults. Approximately 70% will experience it.[118] Careful questioning of adult patients with hand dermatitis will often reveal a prior history of atopic dermatitis.

Complications

Staphylococcal pyoderma is a frequent complication of atopic dermatitis. The skin of nearly all patients with atopic dermatitis is heavily colonized with *S aureus*.[119,120] This is partially explained by the observation that *S aureus* may have specific binding sites for tissue fibronectin and laminin.[121,122] In general, these infections remain superficial, but cases of osteomyelitis have been reported in children with severe atopic dermatitis.[123]

As a result of impaired cellular immune responses,[124] patients with atopic dermatitis sometimes are unable to adequately handle viral or fungal infections of the skin. This increased susceptibility has resulted in widespread cutaneous viral infections such as eczema vaccinatum (vaccinia virus from smallpox vaccine) and Kaposi's varicelliform eruption, which is usually caused by herpes simplex virus (HSV) (Figure 20-18), but has also been seen with coxsackievirus A16. Both produce a similar clinical picture of an acute, widespread, vesiculopustular eruption marked by fever, adenopathy, and prostration. The patients may appear quite ill and some have died.[125,126] Treatment is with intravenous acyclovir (750 mg/m^2/d) and antibiotics for secondary bacterial infection. Other viruses that can cause problems for atopic patients include molluscum contagiosum and human papillomavirus (HPV).

Fig. 20-18. Kaposi's varicelliform eruption from herpes simplex virus in a young adult female with a history of eczema in childhood.

EXHIBIT 20-3

COMMON PRECIPITATING FACTORS IN ATOPIC DERMATITIS

- Excessive exposure to soap, hot water, or chemicals
- Psychic stress
- Overheating (by physical exertion or hot climate)
- Cutaneous infection or infestation (eg, scabies)
- Extremes of temperature (hot or cold)
- Prickly clothes
- Allergic exposure (when relevant)

Diagnosis

Atopic dermatitis is most often confused with contact dermatitis (irritant or allergic), but other dermatoses in the differential diagnosis include seborrheic dermatitis, psoriasis, scabies, nummular dermatitis, and lichen simplex chronicus. Atopic dermatitis is a clinical diagnosis based on the findings of at least three major and three minor criteria (see Exhibit 20-2).

Treatment

When approaching the management of atopic dermatitis, it is useful to keep in mind that this is a disease that is precipitated in genetically predisposed individuals by an environmental stress. The first goal of treatment, therefore, is the elimination of known precipitating factors (Exhibit 20-3).

Topical steroids are a mainstay of therapy in relieving the inflammation of acute episodes and the associated pruritus. Their use should be carefully supervised by the treating physician. Patients must be aware of the risks for dermal atrophy, adrenal suppression, and tachyphylaxis. Because flexural areas are commonly involved, one must be especially alert for possible steroid-induced atrophy. Topical steroids should be applied sparingly and only on inflamed areas. Highly potent topical steroids such as clobetasol propionate applied twice daily may be useful in short courses (less than 2 wk) for treating areas of lichenification, but are best avoided in children. Systemic steroids, while effec-

tive, are not recommended as patients are likely to become dependent on them.

Because xerosis is so often a precipitating factor, hydration of the skin is an essential component of therapy. Emollients such as Eucerin (water, mineral oil; manufactured by Beiersdorf, Norwalk, Conn.), Lac-Hydrin (ammonium lactate, manufactured by Westwood Pharmaceuticals, Buffalo, N.Y.), Moisturel (petrolatum, glycerin; manufactured by Westwood Pharmaceuticals, Buffalo, N.Y.), and 10% urea cream are effective agents that are best applied after bathing. They can be applied to the entire cutaneous surface; topical steroid is applied only to inflamed areas.

Antihistamines such as hydroxyzine (25 mg three times daily), cyproheptadine hydrochloride (4 mg three times daily), and doxepin (75–150 mg/d) can be useful for relieving pruritus. They may be as useful for their associated antiserotonin, anticholinergic, anxiolytic, and sedative effects as for their antihistaminic effect. Topical antipruritic lotions such as Sarna lotion (camphor, menthol, phenol; manufactured by Stiefel, Coral Gables, Fla.) may also be helpful.

Antibiotics are often useful in the management of acute episodes as secondary impetiginization is very common. Erythromycin and dicloxacillin (for both drugs, 250–500 mg twice daily for 10 d) are useful agents and topical mupirocin (applied topically twice daily for 10 d) has been shown to be effective.[19]

Coal tar may be a useful adjunct to therapy. Liquor Carbonis Detergens (coal tar, nonproprietary) can be compounded with a topical steroid such as triamcinolone acetonide. This particular combination can be quite effective.

Phototherapy can be very beneficial in the management of atopic dermatitis. Successful results have been reported with PUVA,[127] UV-B,[128] and a combination of UV-A and UV-B.[129] As these modalities command significant patient cooperation and sophistication, and have long-term risks, they are not recommended for preadolescents. Because PUVA has the greatest long-term risks, it should be reserved for severe, refractory cases.

A time-honored treatment for atopic dermatitis is the Scholtz method developed over 25 years ago.[130] In a modified and simplified form, it consists essentially of

- reducing bathing to a 1-minute shower,
- avoiding soaps (use Cetaphil lotion [manufactured by Owen/Galderma Laboratories, Fort Worth, Tex.] as soap substitute),
- avoiding greasy preparations, and
- applying mild topical steroid solutions (eg, Synalar [fluocinolone acetonide, manufactured by Syntex Laboratories, Palo Alto, Calif.])

In addition, erythromycin (250 mg four times daily) is advocated for any secondary bacterial infections. Vitamin A and desiccated thyroid, although part of Scholtz' original regimen, are not recommended by this author. However, several clinicians have reported excellent results employing the Scholtz method.[131,132]

Usually, however, in managing atopic dermatitis, no one regimen is effective for all patients. Management must be individualized, with particular attention focused on each patient's specific precipitating factors. In most cases, control will be maintained with basic therapy emollients, mild-to-midpotency topical steroids or coal tar products, and antihistamines. Other modalities discussed should be reserved for severe, refractory cases.

Military Considerations

One need only glance at the common precipitating factors (see Exhibit 20-3) to realize that life in the military can be hostile for the individual with atopic dermatitis. It is difficult, if not impossible, to eliminate all of these factors from the military environment. It is not surprising, then, that Sulzberger estimated that atopic dermatitis accounted for 3% to 5% of all disease-related military discharges during World War II.[133] It was the opinion of most dermatologists who served in World War II that it was not prudent to send overseas any man with a history of atopic dermatitis, as these men frequently required prolonged and repeated hospitalization.[62]

Frequently, an individual will appear to have "outgrown" his or her atopic dermatitis and, indeed, will not have experienced an outbreak for several years. It is important to remember, however, two features of the atopic diathesis: a propensity for hand dermatitis, and an impaired cellular immune response. Both factors are negative considerations for a military career.

Hand dermatitis is most likely to result from exposure to chemical irritants. Often, the exposure is occupationally related. Studies have determined that of patients with an occupational dermatitis, 85% have a personal or family history of atopic disease.[134,135] An individual with a history of atopic dermatitis and a propensity for developing hand dermatitis would be disqualified from many mili-

tary occupations in order to avoid duty-related exposure to irritant chemicals.

Impaired cellular immunity renders the atopic patient susceptible to disseminated vaccinia infection (eczema vaccinatum). For this reason, smallpox vaccination becomes dangerous, even if the atopic dermatitis is in remission. Although smallpox vaccination is no longer recommended, the military could require it under special circumstances.

URTICARIA

Urticaria is a common pruritic eruption, marked by characteristic evanescent lesions known as wheals. It affects approximately 15% to 20% of the population at some point during their lifetime.[136] Wheals are, by definition, superficial in nature. When the edematous process spreads to involve the deep dermis and subcutaneous tissue, then it is termed angioedema (Figure 20-19). The edema can involve other organ systems, particularly the cardiopulmonary system and the gastrointestinal tract. Patients can present with urticaria alone (40%), angioedema alone (10%), or urticaria and angioedema combined (50%).[137]

Clinical Features

The clinical hallmark of urticaria is the wheal or hive. It is an elevated, sharply demarcated, pale red or white, dermal flat-topped plaque with no associated epidermal change. Wheals may be bordered by a thin, pale, or red halo (Figure 20-20). Their size varies from a few millimeters to several centimeters and they may be round or oval or coalesce into large, bizarre polycyclic or serpiginous forms. The most characteristic feature of the wheal is its evanescent nature. Although the process can last weeks or even months, individual lesions usually resolve in a matter of hours and rarely persist beyond 24 hours. Wheals are typically quite pruritic and can occur anywhere on the integument.

The occurrence of systemic symptoms is not unusual in urticaria or angioedema. For this reason, a thorough history—including an extensive review of systems—and a physical examination are required. Associated symptoms include arthralgias, headache, hypotension, hoarseness, dyspnea, abdominal pain, nausea, and diarrhea. Because angioedema is a deeper process that more commonly involves mucosal surfaces, it is more likely

Fig. 20-19. Angioedema. Note marked hand swelling in this man who is taking captopril.

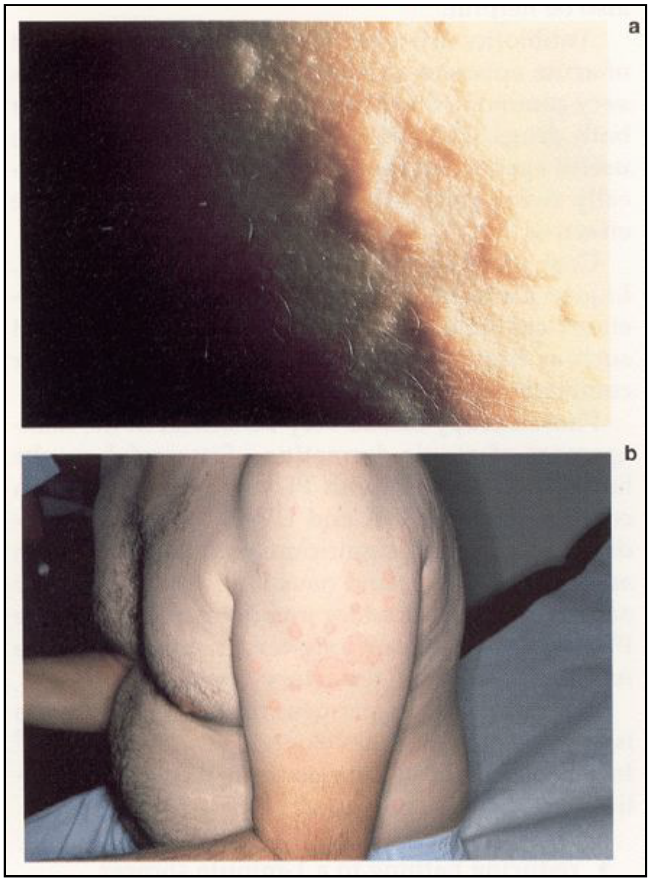

Fig. 20-20. Hives. (**a**) Close-up view of typical pale, edematous wheal with no epidermal change. (**b**) Note peripheral erythematous halo.

to cause these systemic symptoms, which can be life-threatening.

Urticaria has an unpredictable course. The majority of cases are acute and self-limited with spontaneous resolution after a few hours to several days. Many of these patients do not seek medical attention. Urticaria that persists beyond 8 to 12 weeks is arbitrarily classified as chronic urticaria. Approximately 50% of patients are lesion-free in less than 1 year, while 20% may experience recurrent episodes beyond 20 years.[138]

Types of Urticaria

The urticarias can be grouped in a variety of clinical entities. Champion has described some 50 separate classifications.[139,140] Some of the more important types of urticaria are discussed below.

Physical Urticarias

The physical urticarias account for approximately 16% of all urticarias seen in specialty clinics.[139] Over 20 types have been described. Understanding physical urticaria will permit the identification and possible elimination of the etiologic mechanism, thus preventing recurrent episodes.

Dermatographism is the most common of the physical urticarias (Figure 20-21). It is easily reproducible by the firm, brisk stroking of the skin with a blunt-tipped object. The resultant wheal occurs in minutes in the exact location that the pressure was applied. It can be elicited in approximately 1.5% to 4% of healthy individuals.[141]

Fig. 20-21. Wheal and flare appeared after firm stroking of the back. Such physically induced urticarial response (dermatographism) may be seen in otherwise normal individuals.

Fig. 20-22. Pressure urticaria. Wheals occurred when the patient lay on his back for prolonged periods. The circled wheals occurred at the exact location where pressure had been previously applied with a ballpoint pen.

Pressure urticaria is a much less common form, characterized by deep, sometimes painful, wheals that occur at sites exposed to deep pressure for prolonged periods (Figure 20-22)—usually the buttocks or feet. The timing of these wheals is unique in that they occur hours after pressure has been applied and often persist for more than 24 hours. In a study of 44 patients with pressure urticaria, Daves et al[142] determined that the mean onset of whealing was 3.5 hours with a peak at 10 hours, and a mean lesion duration of 36 hours. In their experience, systemic corticosteroids were the only effective treatment. Fifty percent of the patients also exhibited delayed dermatographism. Delayed dermatographism has also been described[143] as an independent entity, distinct from pressure urticaria. In general, however, dermatographism is easily distinguished from pressure urticaria by its immediate onset (minutes versus hours).

Cold urticaria represents from 1% to 7% of all forms of the physical urticarias.[144,145] It occurs in an acquired and a familial form with autosomal dominant inheritance. The primary acquired form is the most common (96%),[146] and the familial form is quite rare.[147] Cold urticaria has been associated with cryoglobulins, cryofibrinogens, cold agglutinins, and paroxysmal hemoglobinuria.[146] Such cases are referred to as secondary acquired cold urticaria. In response to cold stimuli, localized symptoms are produced (erythema, pruritus, wheals), as well as systemic manifestations including respiratory distress, hypotension, and even anaphylaxis. The di-

agnosis is easily confirmed by applying an ice cube to the skin. A wheal will occur several minutes later during the rewarming phase. The ice cube test is negative in the familial type.[147] The duration of cold urticaria is from 3 weeks to over 37 years.[146] Patients are advised to avoid cold climates and rapid decreases in temperature, as may occur in ocean swimming.[148]

Solar urticaria is a rare condition characterized by wheal formation within minutes of sun exposure, sometimes with associated systemic symptoms. Lesions can be induced by light of varying wavelengths from the UV-B range (290–320 nm) to the visible light spectrum (> 400 nm).[149] Although the precise mechanisms of lesion induction are not entirely clear, Leiferman et al[150] have provided convincing evidence for the role of eosinophil degranulation in the pathogenesis. In addition, a circulating photoallergen has been described[151] that is generated by absorption of light energy. Removal of this factor by plasmapheresis has been shown[152] to result in prolonged remission. Tolerance may be induced by PUVA[153] or UV-A alone.[154,155]

Aquagenic urticaria is precipitated by contact with water, regardless of temperature. It is a rare condition that resembles cholinergic urticaria (described below). Shelly and Rawasley[156] reported successful control with ChlorTrimeton (chlorpheneramine maleate, manufactured by Schering Corp., Kenilworth, N.J.), 4 mg four times daily. Aquagenic urticaria is a separate clinical entity from aquagenic pruritus.[157]

Vibratory angioedema is also a rare condition in which localized erythema and edema occur in response to vibration. Autosomal dominance has been described,[158] as well as an acquired form that can be occupationally related.[159] A good therapeutic response to terfenadine (60 mg twice daily) has been reported in at least one case.[160]

Localized heat urticaria, another rare physical urticaria, occurs in response to skin exposure to heat above 43°C. Successful induction of tolerance through graduated incremental exposure under medical supervision has been reported.[161]

Cholinergic Urticaria

In cholinergic urticaria, which accounts for 4% of urticarias,[137] wheals are provoked by heat, emotion, or gustatory stimuli. The lesions produced are characteristically tiny (1–3 mm), markedly pruritic, and persist for roughly 45 minutes to 1 hour. The cutaneous response is felt to be produced by the action of acetylcholine on the mast cell.[136] A new entity of exercise-induced anaphylaxis that is distinguishable from cholinergic urticaria has been described.[162] Cholinergic urticaria is usually easily treated with antihistamines.

Contact Urticaria

Contact urticaria is an uncommon condition that consists of a wheal-and-flare response to a variety of substances applied to the skin, and occurs within 20 to 30 minutes after application. Anaphylaxis can result; it has been described in 12 individuals during surgery, and was caused by their hypersensitivity to natural latex in the surgical glove.[163]

Urticarial Vasculitis

Leukocytoclastic vasculitis presenting as urticaria or angioedema was first recognized at the Mayo Clinic.[164] The cutaneous findings may be identical to common urticaria except that the wheals may be somewhat purpuric, tend to persist for 3 to 5 days, and often heal with residual hyperpigmentation. It is an important entity to recognize because of its frequent association with systemic diseases such as serum sickness, systemic lupus erythematosus, Sjögren's syndrome, and infections such as viral hepatitis type B.[165]

Hereditary Angioedema

Hereditary angioedema is a rare cause of angioedema with its onset in childhood and autosomal dominant inheritance. The episodes of swelling usually recur frequently, are often painful and persistent, and are aggravated by trauma.[140] This form of angioedema occurs without urticaria, so the presence of wheals should exclude the diagnosis. The angioedema is due to a lack of functional C1 esterase inhibitor, an enzyme that controls complement activation. The inhibitor may be diminished in quantity, or may be present but dysfunctional.[166] Daily administration of danazol, an anabolic steroid, may prevent attacks.

Urticaria due to Histamine-Releasing Agents

Many substances (Exhibit 20-4) are capable of causing direct mast cell degranulation with subsequent histamine release. This is not an immune-modulated mechanism. The resultant wheals occur shortly after exposure. Aspirin may exacerbate

EXHIBIT 20-4

AGENTS CAPABLE OF DIRECT HISTAMINE RELEASE

Exhibit 20-4 is not shown because the copyright permission granted to the Borden Institute, TMM, does not allow the Borden Institute to grant permission to other users and/or does not include usage in electronic media. The current user must apply to the publisher named in the figure legend for permission to use this illustration in any type of publication media.

Adapted with permission from Burrell BA, Halpean GM, Huntley AC. Chronic urticaria. *West J Med*. 1990;152:269.

urticaria by altering the production of prostaglandins and leukotrienes, but not by direct histamine release.[140] Contact urticaria can occur via exposure to direct histamine-releasing agents. When evaluating angioedema of the oral mucosa, one should consider the possibility of contact urticaria from cinnamic acid or cinnamaldehyde, which are common ingredients in toothpaste.

Immunoglobulin E–Mediated Urticaria

Although many patients as well as physicians assume that most cases of urticaria are immunoglobulin (Ig) E-mediated, in fact only 3% to 4% actually are.[140] This type of urticaria requires exposure to an allergen, which can occur via inhalation (pollen, spores, animal dander), ingestion (food, food additives, drugs), or injection (Hymenoptera stings, drugs). Of the drugs, penicillin is the most common cause of IgE-mediated urticaria.

Idiopathic Urticaria

Idiopathic urticaria is, by far, the most common category that the physician will see. Many cases that have an obvious cause will be self-evident, so those patients will often not seek medical attention. The process may be multifactorial, so careful history taking is mandatory to try to uncover possible precipitating factors (Exhibit 20-5).

Diagnosis

It is tempting to order multiple screening laboratory tests to rule out the rarer causes of urticaria. Although it may be reasonable to order a few tests, such as a complete blood count or an erythrocyte sedimentation rate, extensive laboratory investigation is often pointless and expensive, and should not be routine. What is important and should be routine is a thorough history and physical examination. The history should be directed at determining whether or not a definable type of urticaria exists that may be related to a physical stimulus, an inhalant, an ingested substance, a systemic disease, an infection, or emotional stress. The information obtained from both the history and the physical will guide any laboratory evaluation. If no specific cause is found, and the symptoms warrant, the patient should be treated empirically.

Treatment

The majority of patients with idiopathic urticaria will respond to antihistamine therapy. H_1-receptor antagonists are the major class of therapeutic agents employed in the management of urticaria. Atarax (hydroxyzine, manufactured by Roerig, New York, N.Y.), 25 mg three times daily, is an excellent first-line therapy and dose may be increased to tolerance, with sedation being its primary dose-limiting effect. It is often useful to add a second H_1 blocker from a different chemical class. Combination with an H_2-receptor blocker such as cimetidine (300 mg four times daily) may also be helpful.[167] Similarly, good results have been obtained with doxepin (75–150 mg/d), an antidepressant with known anti-H_1 and anti-H_2 activity, in the management of chronic idiopathic urticaria.[168]

Because of the problems with sedation from the traditional antihistamines available, much effort went into the development of newer agents with fewer central nervous system (CNS) side effects. Of these second-generation antihistamines, Hismanal (astemizole, manufactured by Janssen Pharmaceuticals, Piscataway, N.J.), 10 mg daily, is the only one currently approved for the treatment of urticaria, but Seldane (terfenadine, manufactured by Marion

EXHIBIT 20-5

CAUSES OF URTICARIA

Foods
- Shellfish
- Eggs
- Milk
- Cheese
- Nuts
- Berries
- Tomatoes
- Chocolate

Food Additives or Contaminants
- Salicylates
- Tartrazine
- Tyramine
- Benzoates
- Hydroxybenzoates
- Sulphites
- Azo dyes
- Penicillin
- Yeasts
- Citric acid

Drugs
- Aspirin
- Penicillins
- Cephalosporins
- Aminoglycosides
- Sulfonamides
- Barbiturates
- Hydralazine
- Phenylbutazone
- Tranquilizers
- Hydantoins
- Quinine
- Angiotensin-converting enzyme inhibitors

Infections
- Chronic bacterial (sinus, dental, urinary tract, etc.)
- Viral (hepatitis, Epstein-Barr, coxsackie)

Systemic Diseases
- Thyroid disease
- Systemic lupus erythematosus
- Malignancies
- Serum sickness

Other
- Candida sensitivity
- Worms/infestations
- Psychological

Data sources: (1) Burrell BA, Halpean GM, Huntley AC. Chronic urticaria. *West J Med*. 1990;152:268–276. (2) Champion RH. Urticaria: Then and now. *Br J Dermatol*. 1988;119:427–436.

Merrell Dow, Kansas City, Mo.), 60 mg twice daily, can also be beneficial.[169]

Military Considerations

Because most cases of urticaria resolve spontaneously in a short period of time, they usually do not become a problem of any special significance in the military. Patients with a physical urticaria could have military occupational exposures that would exacerbate the disease. This obviously poses a potential threat to their health and safety, or to the safety of others, as well as to mission accomplishment. It is hard to imagine a career in the military, particularly in time of war, protected from physical stresses such as heat, cold, pressure, or vibration. Although comprehensive etiologic studies of urticaria and angioedema are not available from World War II, hospital admission statistics do reveal that there were almost 30,000 admissions for urticaria and more than 7,000 for angioedema between 1942 and 1945.[62] In dermatology clinics in Vietnam, urticaria was seen in 1.75% to 2.74% of patients examined.[2]

Another aspect of urticaria that the military physician must consider is the potential harm from the side effects of therapy. As discussed, antihistamines, the mainstay of therapy for urticaria, can have profound CNS side effects—particularly sedation. Again, this could jeopardize individual safety and mission accomplishment. Thus, the physician must address each patient's military occupation and consider imposing temporary duty restrictions. The newer antihistamines, by virtue of their diminished permeability of the blood–brain barrier, will lessen the hazards.

PSEUDOFOLLICULITIS BARBAE

Pseudofolliculitis barbae (PFB) is a condition that occurs in black men in response to shaving. It is common in the military services, where shaving is mandatory, with the prevalence estimated to be 45%[170] to greater than 80%.[171]

Clinical Features

PFB typically manifests as perifollicular, inflammatory papules and papulopustules of the beard area, particularly the anterior portion of the neck and the submandibular region. On close inspection, ingrown hairs are almost always visible (Figure 20-23). In long-standing cases, hyperpigmentation is typical. Severe cases can result in scarring and disfigurement from keloid formation (Figure 20-24).

Acne keloidalis nuchae is a similar condition that occurs on the nape of the neck. It also presents with multiple smooth, flesh-colored papules that are quite firm and may coalesce to form keloids (Figure 20-25). Pustules, cysts, and sinus tracts occasionally form. The condition is aggravated by cutting the hair too close to the skin.

Fig. 20-23. Pseudofolliculitis barbae. (**a**) Typical location on anterior neck. (**b**) Close-up view to show characteristic papules with ingrown hairs.

Pathogenesis

The pathophysiological mechanism responsible for PFB has been clearly elucidated. Essentially, it represents a foreign body reaction[172] that is the result of beard hair penetrating the dermis. The tightly curled and undulating surface of hair in black people has several features that facilitate this process. It is elliptical in shape,[173] so it develops a pointed tip when shaved. Furthermore, the hair initially grows parallel to the skin surface,[174] so that when cut obliquely by shaving, the point is even sharper. Finally, because of its tight curl, the hair has a tendency to grow back toward the epidermis, which is easily penetrated by the pointed hair. The actual penetration of the skin can occur via one of two pathways: through the stratum corneum after growing out from the follicle and arching back toward the skin,[174] or by piercing the follicular wall directly.[175] The latter results from applying tension to the skin during shaving, thus allowing the sharpened tip to retract under the skin when tension is released.

Fig. 20-24. Keloid in an individual with severe pseudofolliculitis barbae.

Fig. 20-25. Acne keloidalis nuchae, recurrent after carbon dioxide laser ablation.

Diagnosis

The clinical presentation of PFB is quite characteristic, so the diagnosis is not a difficult one. It is most often confused with acne vulgaris. The absence of comedones (the primary lesions of acne vulgaris), the restriction of disease activity to the beard area, and the history of onset after close shaving all support the diagnosis. Careful visual inspection with magnification will almost always reveal ingrown hairs in some of the perifollicular papules, confirming the diagnosis of PFB.

Treatment

Usually, the first phase treatment should be to discontinue shaving and allow beard growth for up to 30 days. By this period of time, most of the ingrown hairs will have been pulled free by the growth of the hair shaft in a direction away from the skin surface.

The next step is to resume shaving. However, the individual should never attempt a close shave: this will facilitate retraction of the sharpened hairs below the skin surface with subsequent penetration of the follicular wall and renewal of the entire process. The simplest mechanism that avoids this problem is shaving with electric clippers, which produces a stubble shave appearance. Excellent results have been reported with this technique,[176,177] and it is this author's treatment of choice. Patients must also be taught to inspect the beard hair closely and to attempt to free any ingrown hairs with a pick. Use of a coarse facial sponge, such as Buf-Puf (manufactured by 3M Products, St. Paul, Minn.), is also helpful for accomplishing this.[176,178] At the shaving clinic at Lackland Air Force Base, Texas, this method has been successfully initiated at the time of initial patient presentation, without having to wait the customary 30 days. This allows the patient (usually a basic trainee) to maintain a military appearance and control the problem at the same time.

Shaving can also be accomplished with a manual razor, provided that the proper guidelines are followed (Exhibit 20-6). Careful following of these guidelines is time consuming. With practice, it usually requires about 15 minutes. There are no shortcuts. If an individual is usually rushed in the morning, we often recommend shaving in the evening when he can devote the proper amount of attention that is required.

Successful results have also been reported using electric razors[179] and a foil-guarded manual razor specifically designed for patients with PFB (PFB

EXHIBIT 20-6

SHAVING GUIDELINES FOR PATIENTS WITH PSEUDOFOLLICULITIS BARBAE

1. The beard must be thoroughly hydrated and lubricated; liberal application of shaving cream (foam or gel) will hydrate and soften the beard. Warm, moist heat (hot towel) is also useful.
2. Never pull the skin taut.
3. Never shave over the same area twice; one need shave an area only once, provided the blades are kept sharp by frequent changing (after two shaves).
4. Always shave with the grain of the beard.
5. Carefully inspect the beard area before and after shaving; gently extract the ingrown hairs; avoid plucking.

Shaving System, manufactured by American Safety Razor Co., Staunton, Va.).[180]

Chemical depilatories are also an effective treatment modality.[181,182] Many patients, however, find them irritating. In addition, they are time consuming and they produce a characteristic odor that many patients find bothersome. A minority of patients seem to prefer this mode of treatment.

Keloids may respond to intralesional steroid therapy, which should be instituted early and aggressively to prevent disfigurement. Severe cases have required excision and grafting.[183] The results of surgical therapy are usually disappointing.

Systemic antibiotic therapy is rarely required in the management of PFB, except in those few cases that become secondarily infected. Some authorities claim efficacy for various topical medications such as tretinoin[184] (applied nightly) and clindamycin (applied twice daily).[185] Occasional use of mild topical steroids may also be useful, particularly for relieving any irritation from depilatories.

Patients must be instructed to avoid plucking of hairs as this may cause breakage of the hair shaft within the follicle with subsequent transfollicular dermal penetration and foreign body response.

Military Considerations

To prevent PFB, one need only grow a beard. Unfortunately, this is contrary to military regulations. This simple fact has created much strife. In the past, the lack of a consistent policy regarding shaving requirements and the management of PFB from an administrative as well as medical viewpoint turned a relatively minor medical problem into a major social issue. Racial tension over this led to public demonstrations and even frank mutiny by disgruntled black enlisted members in the 1970s.[171] In 1979, one investigator wrote that "pseudofolliculitis barbae has now become the most significant dermatologic disease in the U.S. Army"[171(p62)] and some military dermatologists called for "the pan-service acceptance of the voluntary growth of a beard by any service member".[170(p459)]

Fortunately, the lack of a consistent policy was recognized and rectified so that today, PFB clinics are functioning smoothly throughout the military. Administrative guidelines are clearer, commanders are better informed, and medical providers are better educated on the unique problems regarding PFB.

The importance of keeping PFB under control without growing a beard is not simply to maintain a uniform, clean shaven appearance. It is also important for the safety of the individual in a combat environment, where the threat of chemical weapons is ever present. Although tests on the efficacy of gas masks reveal that beard growth of as much as ⅛ in. (up to 3 d) did not significantly alter the seal to the mask,[186] it seems obvious that excessive beard growth would have an adverse effect on the seal. An individual whose PFB was poorly controlled and who required a 30-day profile to allow for beard growth, would likely require evacuation to the rear. Thus, proper management of a common condition like PFB is essential for avoiding unnecessary loss of manpower. The key to the successful management of PFB will always be education and communication among soldiers, healthcare providers, and supervisors.

CUTANEOUS VIRAL INFECTIONS

Herpes Simplex Labialis

Herpes simplex labialis is the condition commonly referred to as "fever blisters." It is caused by herpes simplex virus (HSV), a double-stranded DNA virus, of which two types exist. Most infections involving the oral mucosa are of type 1, while type 2 is responsible for most HSV infections involving the genitalia (genital herpes is discussed in Chapter 19, Sexually Transmitted Diseases). Like all herpes viruses, HSV-1 is able to persist in a latent form in its host, causing recurrent outbreaks.[187] It occurs worldwide, and by the fourth decade of life more than 90% of the population have developed antibodies to HSV.[188] Thus, recurrent HSV labial infection is an extremely common condition; it affects 20% to 40% of the adult population.[189]

Clinical Features

Pharyngitis and gingivostomatitis are the usual manifestations of primary infection with HSV-1, seen most commonly in children and young adults.[190] Vesicles or erosions may be seen on the palate, gingiva, tongue, lip, or perioral region of the face.[191] Primary infection usually is associated with fever and cervical adenopathy as well, and is most severe in adults.

Recurrent infection manifests as vesicles or erosions on the vermilion border of the lip (Figure 20-26) that usually crust over within 48 hours. Of-

Fig. 20-26. Herpes simplex labialis. Note intact vesicle.

Fig. 20-27. Targetlike lesions in erythema multiforme. Note vesiculation.

ten, the patient experiences burning and itching at the site prior to vesicle formation. The rate of recurrence varies between 16% and 45%.[192] Recurrent outbreaks represent reactivation of the virus from its latent form in the trigeminal ganglion.[192] Although the exact mechanism of reactivation is not known, it is assumed that the virus travels down the axon of the nerve to infect keratinocytes on the adjacent location on the lip. Many precipitating factors have been identified including trauma, UV light exposure, fever, immunosuppression, psychological stress, and exposure to excessive amounts of alcohol, tobacco, or spicy foods.[193,194]

Recurrent HSV-1 outbreaks can precipitate a reaction known as erythema multiforme, an acute, widespread eruption with characteristic targetlike lesions (Figure 20-27). Antiviral therapy with acyclovir has been shown to prevent relapses of recurrent erythema multiforme.[195]

Diagnosis

Grouped vesicles or crusted erosions on the lip are strongly suggestive of HSV infection. Lesions that are secondarily infected with bacteria may be difficult to distinguish from primary impetigo, which is characterized by honey-colored crusts. A history of recurrence in the exact location of episodes of minor trauma or stress or UV light exposure support the diagnosis of herpes simplex. Primary gingivostomatitis may resemble aphthae, hand-foot-and-mouth disease (coxsackie virus), Behçet's syndrome, or Stevens-Johnson syndrome.

The diagnosis of HSV infection is facilitated by performing a Tzanck smear. Material is obtained by scraping the base of a vesicle or erosion. The specimen is then smeared on a glass slide, stained with Wright's stain, and examined under the microscope. In HSV-infected tissue, multinucleated giant cells and/or keratinocytes with large, pale nuclei with peripheral clumping of chromatin will be seen (Figure 20-28). In addition, culture confirmation of HSV is available through most laboratories. Confirmation of HSV infection through detection of the virus's DNA by polymerase chain reaction, an exquisitely sensitive technique, has been described[196] but is expensive and impractical for ordinary use.

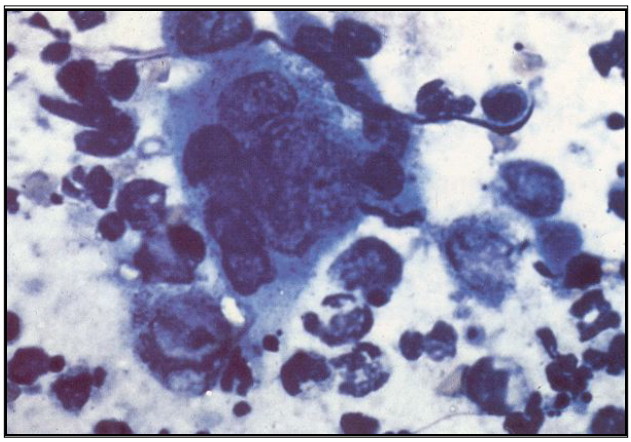

Fig. 20-28. Tzanck smear (original magnification 100X). Note the large multinucleated keratinocyte in the center.

Treatment

In most instances, systemic treatment of herpes simplex labialis is not required. Cool compresses and topical application of an antibiotic ointment may promote healing and prevent bacterial superinfection. Topical acyclovir is ineffective in immunocompetent individuals.[197] Patients may benefit from oral acyclovir (200 mg five times daily) if initiated immediately after symptom onset.[198]

Recurrences of herpes simplex labialis can be decreased by prophylactic administration of oral acyclovir (200 mg three times daily).[199] In most cases, the expense of this method of treatment precludes its use. It is indicated, however, for patients with recurrent erythema multiforme due to HSV.[195,200] It has also been shown to be of practical value in individuals with a history of UV radiation–induced herpes simplex labialis who are going to be exposed to periods of intense UV exposure such as snow skiing (or desert deployment).[199,201] Zinc oxide, a complete sun blocker, should also be considered for these individuals.

Herpes Zoster

Herpes zoster, also called shingles, is a common neurocutaneous disease caused by the varicella-zoster virus (VZV), a member of the herpesviridae group, which is also the etiologic agent for chickenpox. It occurs in 1.3 to 4.8 persons per 1,000 per year,[202–204] and is characterized by a vesicular eruption in a dermatomal distribution. Often, it is associated with varying degrees of pain, which may persist beyond the point of healing of the rash.

Clinical Features

Herpes zoster occurs in individuals with a previous history of varicella. Patients typically present

Fig. 20-29. Herpes zoster. (**a**) Thoracic dermatome. Note sharp cutoff at the midline. (**b**) Close-up view of (a) to reveal characteristic grouped vesicles on an erythematous base. (**c**) Lumbar distribution. (**d**) Sacral distribution with sharp cutoff at midline; note vesicles coalescing and becoming purpuric.

Fig. 20-30. Herpes zoster. Vesicles have coalesced into larger bullae, which have become (**a**) purpuric or (**b**) pustular.

with grouped vesicles on an erythematous base in a dermatomal distribution (Figure 20-29). A generalized eruption may occur in 2% to 5% of patients, particularly in elderly or immuno-compromised patients.[205] The eruption is almost always unilateral and rarely extends across the midline. The vesicles may coalesce into larger bullae and may become hemorrhagic or even pustular (Figure 20-30). The patients may or may not experience the prodrome of fever, malaise, and headache. Often, the rash is preceded by radicular pain, a burning sensation, or hyperesthesia in the region of the same dermatome. The most common dermatomes involved are the thoracic, followed by the cranial, cervical, lumbar, and sacral. The most common single nerve involved is the trigeminal nerve—usually a single branch.[206]

New lesions can develop for up to approximately 8 days, but usually do not occur after 4 days from the onset of the rash.[207] Crusting occurs in 10 to 14 days, but lesions may persist for longer periods in elderly or immunocompromised patients. The areas involved may heal with residual postinflammatory hyperpigmentation and can result in significant scarring (Figure 20-31).

Types of Herpes Zoster

Herpes Zoster Ophthalmicus. Involvement of any branch of the trigeminal nerve is called herpes zoster ophthalmicus (Figure 20-32). Although ocular involvement may occur in association with maxillary or mandibular nerve involvement, this is uncommon. Most frequently, the supraorbital and supratrochlear divisions of the frontal nerve are involved. Hutchinson's sign consists of lesions on the nasal tip, which indicate involvement of the nasociliary branch of the ophthalmic nerve and a high likelihood of ocular complications. When Hutchinson's sign is present, immediate ophthalmological consultation is warranted. Eye complications include lid ulceration and scarring; conjunc-

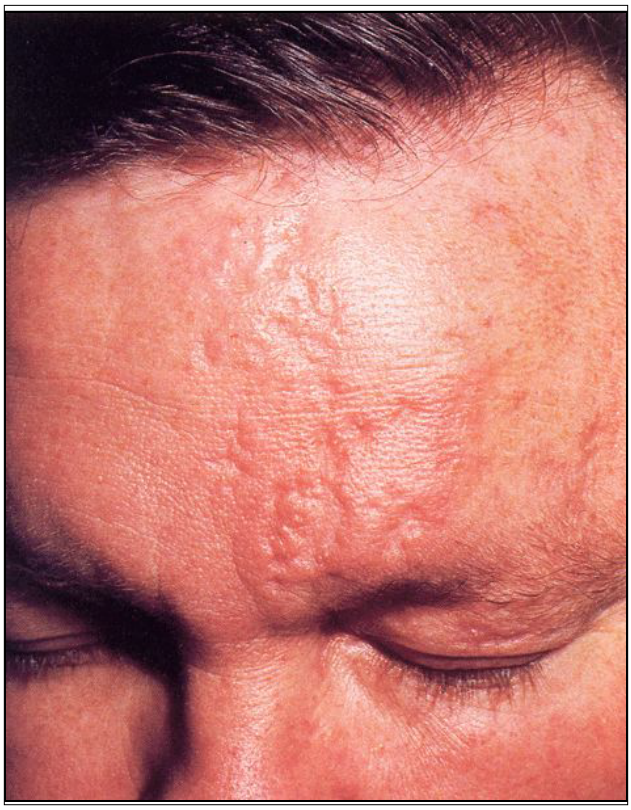

Fig. 20-31. Midline and unilateral forehead and eyelid atrophic scars that resulted after healing of herpes zoster infection.

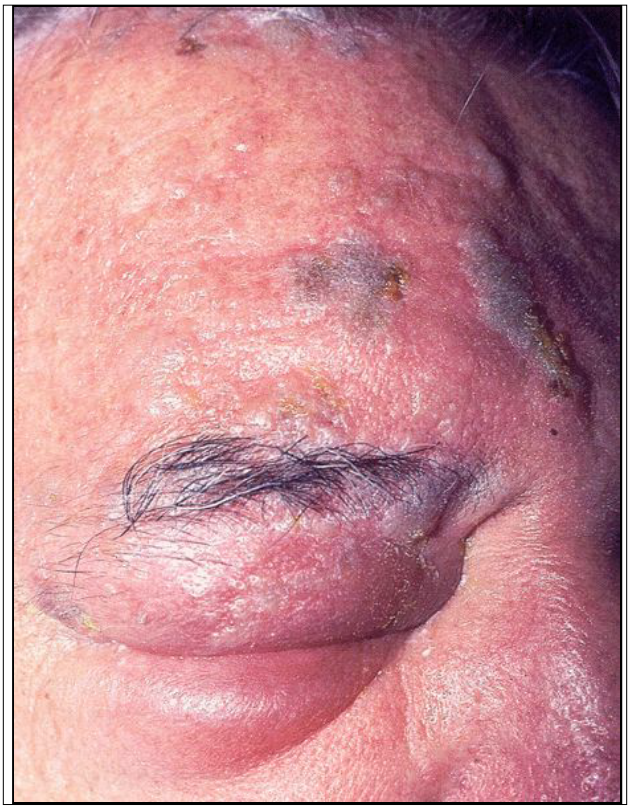

Fig. 20-32. Herpes zoster ophthalmicus with marked periorbital and lid edema. Immediate ophthalmological consultation is required.

tivitis; proptosis; keratitis; corneal ulceration, vascularization, or perforation; uveitis; and vascular ischemic injuries.[206]

Ramsay Hunt's Syndrome. Ramsay Hunt's syndrome includes facial nerve palsy as a result of involvement of the geniculate ganglion with VZV (Figure 20-33). Vesicles are usually present on the external ear or tympanic membrane, and auditory symptoms may be present such as tinnitus, vertigo, or diminished auditory acuity. Early intervention with systemic steroids may be beneficial. The facial nerve palsy usually resolves, but can be permanent.

Postherpetic Neuralgia. The acute pain of herpes zoster is usually of a transitory nature. In some individuals, however, particularly the elderly, severe pain may persist for months and become disabling. The frequency of postherpetic neuralgia varies between 15% and 70%.[205] It is particularly frequent and severe in patients with herpes zoster ophthalmicus. The neuralgia resolves spontaneously in 50% of patients within 3 months and in 75% within 1 year.[208]

Diagnosis

The presence of grouped vesicles on an erythematous base in a dermatomal distribution, with associated pain in a similar location, creates little question about the diagnosis of shingles. Disseminated cases may resemble primary varicella infection or disseminated HSV. The Tzanck smear will not differentiate the three. Viral cultures are available, but can take up to 2 weeks to grow. Fluorescein-tagged VZV antibody applied to a Tzanck smear may help to differentiate VSV from HSV but requires a fluorescent microscope.

Treatment

In most cases involving immunocompetent patients, symptomatic treatment will suffice. Cool compresses with Burow's solution will hasten drying and crusting of the vesicles. For analgesia, narcotics may be required.

Acyclovir has been shown to be effective in shortening the duration of disease and reducing the acute and postzoster pain.[209–211] VZV is up to 8-fold less susceptible to acyclovir than HSV,[212] so higher doses are required. The recommended dose is 800 mg orally five times daily for 10 days.

The role of systemic corticosteroid therapy in the treatment of VZV infection is somewhat controversial.[213] A short course (60 mg/d orally for 5 d tapered over 2 wk) combined with a 10-day course of acyclovir may be useful for the prevention of

Fig. 20-33. Ramsay Hunt's syndrome: inability to raise eyebrow with ipsilateral drooping of the corner of the mouth.

postherpetic neuralgia in patients at high risk, such as those greater than 60 years old with VSV involving the trigeminal nerve.

Molluscum Contagiosum

Molluscum contagiosum is a benign cutaneous infection caused by a poxvirus.[214] It occurs in children and young adults and is worldwide in distribution. It is spread by fomites as well as by direct contact,[215] including venereal transmission.[216] (Molluscum contagiosum is also discussed in Chapter 19, Sexually Transmitted Diseases.)

Clinical Features

The pathognomonic lesion of molluscum contagiosum is a small (2–5 mm), firm, smooth, dome-shaped, translucent papule with a central umbilication. Rapid freezing may accentuate this central depression, thus aiding in the diagnosis (Figure 20-34). With pressure, a white, curdlike substance can be expressed from the center of fully developed lesions. Microscopical examination of a smear of this substance after staining will reveal the characteristic cytoplasmic inclusions known as Henderson-Patterson bodies.

Patients may have few or numerous lesions. They can occur on any cutaneous site, but have a predilection for the pubic region and adjacent locations in adults; in children, the trunk, face, and proximal extremities are most often involved. In general, the lesions are asymptomatic. Without treatment, the disease will last an average of 6 months to 3 years; individual lesions persist for approximately 2 months.[217]

Diagnosis

The appearance of typical, small, umbilicated papules on the exposed areas of children or the area of the genitalia of adults usually leaves little doubt as to the diagnosis of molluscum contagiosum. In acquired immunodeficiency syndrome (AIDS) patients, lesions may appear with atypical features.[218] Recently, there have been reports of cutaneous cryptococcosis in AIDS patients resembling molluscum contagiosum,[219,220] and a case of molluscum contagiosum mimicking a basal cell car-

Fig. 20-34. Molluscum contagiosum. (**a**) Flesh-colored papules in periorbital location. Note central umbilication of some lesions. (**b**) Slightly erythematous papules on the trunk. (**c**) Use of cryotherapy to accentuate the central umbilication, facilitating diagnosis.

cinoma in a patient with AIDS.[221] If any doubt exists, demonstration of the pathognomonic Henderson-Patterson intracytoplasmic inclusions by cytological or histological examination will confirm the diagnosis.

Treatment

When approaching the management of molluscum contagiosum, it is important to consider that it is a benign disease in which the lesions eventually resolve spontaneously. Therefore, one should avoid aggressive treatment that may be painful or result in scarring. Some argue that the disease should not be treated at all, particularly in children.[222] Treatment may be justified, however, as an attempt to shorten the course of the disease, thus preventing viral transmission and autoinoculation.

Treatment involves destruction of the lesions by mechanical means such as curettage, cryotherapy, or electrosurgery or by chemical irritants such as retinoic acid, cantharidin, phenol, podophyllin, or trichloroacetic acid. The most effective of these modalities is probably removal by curettage. The treatment may be facilitated in children by use of newly developed topical anesthetic agents such as eutectic mixture of local anesthetic (EMLA).[223]

Warts

Warts are benign cutaneous tumors that will affect up to 10% of the population.[224] They are caused by the human papillomavirus (HPV), a virus that has gained a considerable degree of attention due to its ubiquitous nature, tenacity, and oncogenic potential. (Genital warts caused by HPV are discussed in Chapter 19, Sexually Transmitted Diseases.)

The papillomavirus (PV) of the papova group of viruses consists of multiple species that are host-specific such as bovine PV, sheep PV, cottontail rabbit PV (Shope fibroma virus), and HPV.[225] Natural infection by PV is limited to the skin and mucous membranes of the host species. HPV is an ether-resistant virus with icosahedral symmetry and a double-stranded circular DNA.[226] It is the presumed etiologic agent of human warts, based on the facts that DNA and viral particles of HPV have been found in human warts, and filtered extracts of warts will produce papillomas if injected into the skin of human.[227]

At least 55 types of HPV have been recognized based on DNA homology, and each type appears to have some degree of anatomic specificity. For instance, HPV type 4 is associated with common warts, while types 6 and 11 are associated with condyloma acuminata of the genital region.[228] Some types apparently have significant oncogenic potential, particularly types 16, 18, and 31, which are commonly identified in cervical carcinoma.[228]

Clinical Manifestations

Like all papillomaviruses, HPV can infect the skin and mucous membranes including the genitalia, conjunctiva, oral cavity, and larynx. This discussion is limited to HPV infection of the skin.

Common Warts. The common wart (verruca vulgaris) is an exophytic, rough-textured, hyperkeratotic papule that is usually painless. Although typically smaller than 1 cm, warts can form larger plaques. Warts can occur almost anywhere on the skin, but are most common on the dorsum of the hands and fingers, particularly in young children (Figure 20-35). Patients may present with single lesions, but multiple lesions are more common since autoinoculation is a frequent process. Common warts will frequently resolve spontaneously after several months, but they may persist or recur after many years. Warts that resolve spontaneously do not scar. When they occur in the periungual region, they may cause nail plate deformities (Figure 20-36).

Flat Warts. Flat warts (verruca plana) are small (1–3 mm), slightly elevated, flesh colored, flat papules that are almost always multiple. They occur mainly on the face, neck, hands, or knees of young adults and adolescents (Figure 20-37), and are resistant to treatment.

Filiform Warts. Filiform warts (verruca filiformis) occur most commonly on the face. Multiple lesions may be seen, but they are usually single. These are elongated, thin, pointed projections that, although cornified, remain relatively soft.

Plantar Warts. Plantar warts (verruca plantaris) are of two types: mosaic and myrmecia (Figure 20-38). The most commonly seen are the mosaic types, which appear as multiple flat, slightly elevated, hyperkeratotic papules that are usually coalescent. They are most frequently seen in adolescents overlying the metatarsal heads, and are frequently tender and can cause pain on walking. Close inspection of these warts will reveal the typical coarse surface that is sharply demarcated from the surrounding skin. The normal skin markings are interrupted on the surface of the warts. Paring of the keratotic surface will reveal dark, punctate areas that represent thrombosed capillaries. Continued paring will produce pinpoint bleeding.

Fig. 20-35. Common verrucae. (**a**) Typical grouped warts in a periungual location. (**b**) Isolated wart on dorsum of hand. (**c**) Larger wart on thumb; note thrombosed capillaries visible on the surface. (**d**) Large wart on arm.

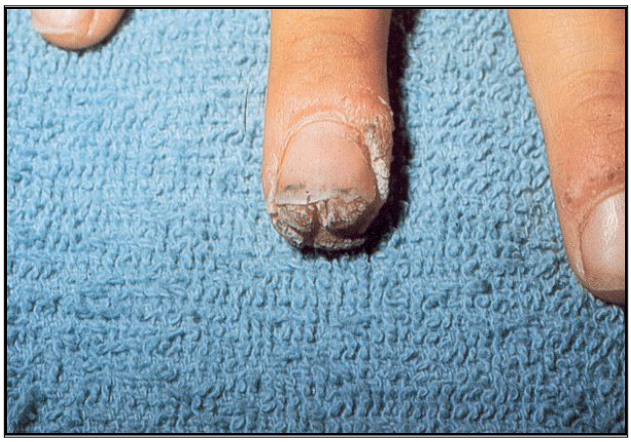

Fig. 20-36. Periungual wart causing lifting of distal free edge of the nail plate.

Fig. 20-37. Flat warts. (**a**) Facial involvement. (**b**) Lesions on the knee.

Fig. 20-38. Plantar warts. Mosaic types predominate surrounding a myrmecia type. Location over metatarsal heads is common.

The second type of plantar wart is the myrmecia ("ant hill") type. These are deeper, dome-shaped papules that frequently become inflamed.

Other Cutaneous Manifestations. Epidermodysplasia verruciformis is a rare, inherited disease characterized by widespread verruciform plaques that occur in childhood and persist into adulthood. These plaques represent extensive infection with HPV in individuals with impaired immunity. Squamous cell carcinoma will develop in a large number of these patients, particularly on sun-exposed areas.[229]

The DNA of HPV has been demonstrated in some keratoacanthomas[230] and lesions of Bowen's disease (squamous cell carcinoma in situ).[231]

Diagnosis

The morphology of warts usually is distinctive enough to allow diagnosis by visual inspection. At times they may resemble seborrheic keratoses, actinic keratoses, molluscum contagiosum, cutaneous horns, or acrokeratosis verruciformis of Hopf. Plantar warts may mimic corns (clavi) or calluses. Squeezing a plantar wart usually elicits pain, unlike a callus. In contradistinction to warts, the normal skin markings are accentuated in clavi and calluses. Paring of the warts with a scalpel blade will reveal the characteristic dark, punctate, thrombosed capillaries.

Treatment

Like molluscum contagiosum, cutaneous warts are generally a benign infectious process that will frequently resolve spontaneously. Spontaneous remission is seen in 40% of patients within 6 months, and 66% in 2 years.[232] Therefore, the physician should avoid overly aggressive treatment that may result in scarring, and be particularly careful to

avoid scarring on the plantar surface as this could cause pain on walking. The modalities available for treating warts are numerous, which speaks for the tenacity of HPV. Recalcitrance is common with warts, and the physician should explain to patients at the initial visit that multiple treatments are sometimes required and recurrences are frequent.

Effective topical keratolytic agents are available. These include salicylic acid, which is available in 40% concentration in a self-adhesive tape (Mediplast, manufactured by Beiersdorf, Norwalk, Conn.) and combined with lactic acid in flexible collodion (Duofilm, manufactured by Stiefel, Coral Gables, Fla.). Both work well under occlusion, if applied daily for several weeks. These may be helpful for treating plantar warts, particularly in children, but can require a fair amount of patience and compliance.

One of the easiest and most effective treatments for warts is curettage with or without electrodesiccation or cryotherapy to the base. Mahrle and Alexander[233] report good results in the treatment of periungual and plantar warts with light focal electrocoagulation, followed by curettage.

Cryotherapy with liquid nitrogen can also be an effective means of eradication. Again, multiple treatments may be required. Bunney et al[234] reported a cure rate of 80% when treating warts on the hands with cryotherapy every 3 weeks for up to 12 weeks.

For warts recalcitrant to the methods already described, particularly periungual or plantar, one might consider intralesional bleomycin[235] or vaporization with the carbon dioxide laser.[236] Facial verruca plana can be most refractory to treatment. Daily application with Retin-A (tretinoin, manufactured by Ortho, Raritan, N.J.) may be helpful, as can twice-daily application of Efudex (5-fluorouracil, manufactured by Roche Laboratories, Nutley, N.J.).[237]

Military Considerations

An important consideration for the military physician regarding cutaneous viral infections concerns the role played by stress in triggering outbreaks. The battlefield certainly provides a degree of stress, both emotional and physical, that most people will never experience elsewhere. For this reason, the incidence of infections such as herpes simplex labialis or herpes zoster is likely to be increased. It is extremely important, then, for the military physician to have some useful knowledge regarding their treatment and possible prevention. Some degree of protection may be granted to the individual with a history of UV radiation–induced herpes labialis with the prophylactic use of acyclovir and sun blockers such as zinc oxide. There are no measures available to prevent an episode of shingles. However, the physician can intervene to prevent secondary bacterial infection, which is certainly more likely to occur during wartime, when standards of hygiene are unavoidably lowered. This can be achieved through temporary isolation or hospitalization and the use of topical or systemic antibiotics.

In the treatment of warts, early medical intervention is encouraged to avoid the possible impairment of performance that may occur as the result of widespread involvement of the fingers or the presence of painful plantar lesions. However, overly aggressive treatment should be avoided, because scars or large, iatrogenic bullae could negatively affect performance, permanently or temporarily.

SUMMARY

It is imperative for the medical officer to have some basic understanding of the common dermatoses. Historically, these skin diseases have had a substantial impact on the number of casualties suffered during armed conflicts. While usually not considered significant threats to an individual's health, these maladies will frequently be exacerbated under battlefield conditions, resulting in significant morbidity with a subsequent negative impact on performance of combat duty.

The common dermatoses are usually not difficult to manage. Prompt recognition and intervention by the medical officer may prevent a simple problem from rapidly escalating into an incapacitating condition.

Medical officers with a firm grasp on the recognition and management of common skin diseases will be able to intervene easily to maintain the health of individual troops as well as the collective fighting effectiveness of their units. During armed conflict, given the harsh environmental conditions that exist, intervention may be required frequently. Understanding the information contained in this chapter will enable the medical officer to manage these common dermatoses appropriately and skillfully.

REFERENCES

1. Sulzberger MB, Akerg WA. Impact of skin diseases on military operations. *Arch Dermatol*. 1969;100:702.

2. Allen AM. *Skin diseases in Vietnam, 1965–72*. In: Ognibene AJ, ed. *Internal Medicine in Vietnam*. Vol 1. Washington, DC: Medical Department, US Army, Office of The Surgeon General and Center of Military History; 1977: 29–40.

3. Pillsbury DM, Livingood CS. Experiences in military dermatology. *Arch Dermatol Syphilol*. 1947;55:441–462.

4. Macpherson WG, Horrocks WH, Beveridge WWO, eds. *History of the Great War, Medical Services, Hygiene of the War*. London: His Majesty's Stationery Office; 1923: 68.

5. Baker H. Psoriasis. In: Rook A, Esling FJG, Wilkinson DS, Burton JL, eds. *Textbook of Dermatology*. 4th ed. Oxford, England: Blackwell Scientific Publications; 1988: 1469–1532.

6. Christophers E, Krueger GG. Psoriasis. In: Fitzpatrick TB, Eiseu AZ, Wolff K, Freedberg IM, Austen KF, eds. *Dermatology in General Medicine*. 3rd ed. New York, NY: McGraw-Hill Book Co; 1987: 461–491.

7. Farber EM, Nall ML. The natural history of psoriasis in 5,600 patients. *Dermatologica*. 1974;148:1–18.

8. Van Scott EJ, Ekel TW. Kinetics of hyperplasia in psoriasis. *Arch Dermatol*. 1961;88:373–381.

9. Guilhou JJ, Maynodier J, Clot J. New concepts in the pathogenesis of psoriasis. *Br J Dermatol*. 1978;18:585–592.

10. Krueger GG. Psoriasis: Current concepts of its etiology and pathogenesis. In: Sobson RL, Thiecs BH, eds. *Yearbook of Dermatology*. Chicago, Ill: Yearbook Medical Publishers; 1981: 13–70.

11. Nicholas GD, Helwig EB. Exfoliative dermatitis: A clinicopathologic study of 135 cases. *Arch Dermatol*. 1973;108:788–797.

12. Abrahams T, McCarthy JT, Sanders SR. One hundred and one cases of exfoliative dermatitis. *Arch Dermatol*. 1963;87:96–101.

13. Penneys NS, Ziboh V, Lord J. Pathogenesis of Woronoff ring in psoriasis. *Arch Dermatol*. 1976;112:955–957.

14. Gupta AK, Ellis CN, Goldfarb MT, Vorhees JJ. Woronoff ring during anthralin therapy for psoriasis. *Arch Dermatol*. 1986;122:248.

15. Weathers DR, Baker G, Archard HO, Burkes EJ Jr. Psoriasiform lesions of the oral mucosa. *Oral Surg*. 1974;37:872–888.

16. Cataldo E, McCarthy P, Yaffee H. Psoriasis with oral manifestations. *Cutis*. 1977;20:705–708.

17. Buchners A, Begleiter A. Oral lesions in psoriatic patients. *Oral Surg*. 1976;41:327–332.

18. Depaoli M. Experimental study of the phenomenon of the isomorphous reaction in psoriasis and lichen planus. *Minerva Dermatol*. 1953;28:197.

19. Rosenberg EW, Noah PW. The Köebner phenomenon and the microbial basis of psoriasis. *J Am Acad Dermatol*. 1988;18:151–158.

20. Bernhard JD. Auspitz sign is not sensitive or specific for psoriasis. *J Am Acad Dermatol*. 1990;22:1079–1081.

21. Whyte HJ, Baughman RD. Acute guttate psoriasis and streptococcal infection. *Arch Dermatol*. 1964;89:350.

22. Jurik AG, Tenowitz T. Frequency of skeletal disease, arthro-osteitis, in patients with pustulosis palmoplantaris. *J Am Acad Dermatol*. 1988;18:666–671.

23. Rosen K, Lindstedt G, Mobacken H, Nystrom E. Thyroid function in patients with pustulosis palmoplantaris. *J Am Acad Dermatol*. 1988;19:1009–1016.

24. Lindgren S, Groth O. Generalized pustular psoriasis: A report of 13 patients. *Acta Derm Venereol*. 1976;56:139–147.

25. Baker H, Ryan TJ. Generalized pustular psoriasis: A clinical and epidemiological study of 104 cases. *Br J Dermatol*. 1986;80:771–793.

26. Hellgren L. Induction of generalized pustular psoriasis by topical use of betamethasone-dipropionate ointment in psoriasis. *Ann Clin Res*. 1976;8f:317–318.

27. Wright V. Psoriasis and arthritis. *Ann Rheum Dis*. 1956;15:348–356.

28. Moll JMH, Wright V. Familial occurrence of psoriatic arthritis. *Ann Rheum Dis*. 1973;22:181.

29. Kragballe R, Beck HI, Sogaard H. Improvement of psoriasis by a topical vitamin D_3 analogue (MC903) in a double-blind study. *Br J Dermatol*. 1988;119:223–230.

30. Kettler AH, Baughn RE, Orengo IF, Black H, Wolf JE. The effect of dietary fish oil supplementation on psoriasis. *J Am Acad Dermatol*. l988;18:1267–1273.

31. Ellis C, Gorsolowski D, Hamilton T. Cyclosporine improves psoriasis in a double-blind study. *JAMA*. 1986;256:3110–3116.

32. Keczkes K, Teasdale P, Wiseman RA, Mugglestone CJ. Plasma cortisol levels after topical application of diflucortolone valerate (0.3%) or clobetusol propionate (0.05%) in psoriatic patients. *Br J Dermatol*. 1970;99:417–420.

33. Katz HI, Hien NT, Prawer SE, Mastbaum LI, Mooney JJ, Samson CR. Superpotent topical steroid treatment of psoriasis vulgaris—clinical efficacy and adrenal functlon. *J Am Acad Dermatol*. 1987;16:804–811.

34. Katz HI, Hien NT, Prawer SE, Scott JC, Grivna EM. Betamethasone dipropionate in optimized vehicle: Intermittent pulse dosing for extended maintenance treatment of psoriasis. *Arch Dermatol*. 1987;123:1308–1311.

35. Lowe NI, Ashton RE, Koudsi H, Verschoore M, Schufer H. Anthralin for psoriasis: Short contact anthralin therapy compared with topical steroid and conventional anthralin. *J Am Acad Dermatol*. 1989;10:69–72.

36. Schulze HJ, Schauder S, Mahrle G, Steigleder GK. Combined tar-anthralin versus anthralin treatment lowers irritancy with unchanged antipsoriatic efficacy. Modifications of short contact therapy and Ingram therapy. *J Am Acad Dermatol*. 1987;17:19–24.

37 Young E, Weelden HV. Treatment of psoriasis with a combination of dithranol and coal tar. *Br J Dermatol*. 1987;116:281–282.

38. Comaish JS. The effect of tar and ultra-violet on the skin. *J Invest Dermatol*. 1987;88(Suppl):61–64.

39. Fischer LB, Maibach HI. Topical antipsoriatic agents and epidermal mitosis in man. *Arch Dermatol*. 1973;108:374–377.

40. Goeckerman WH. The treatment of psoriasis. *Northwest Med*. 1925;24 229–231.

41. Stern RS, Ziegler S, Parrish JA. Skin carcinoma in patients with psoriasis treated with coal tar and artificial ultraviolet radiation. *Lancet*. 1980;1:732–735.

42. Moy LS, Chalet M, Lowe NJ. Scrotal squamous cell carcinoma in a psoriatic patient treated with coal tar. *J Am Acad Dermatol*. 1986;14:518–519.

43. Joivet J, Cowan KH, Curt GA, Clendennin NJ, Chabner BA. The pharmacology and clinical use of methotrexate. *N Engl J Med*. 1983;309:1094–1104.

44. Roenigh HH Jr, Auerbach R, Mailbach HI, Weinstein GD. Methotrexate in psoriasis: Revised guidelines. *J Am Acad Dermatol*. 1988;19:145–156.

45. Guzzo C, Benik K, Lazarus GI, Johnson J, Weinstein G. Treatment of psoriasis wlth piritrexim, a lipid-soluble folate antagonist. *Arch Dermatol*. 1981;127:511–514.

46. Eichner R. Epidermal effects of retinoids: In-vitro studies. *J Am Acad Dermatol*. 1986;15:789–797.

47. Ellis CN, Vorhees JJ. Etretinate therapy. *J Am Acad Dermatol*. 1987;16:267–291.

48. Slawsky LD, Libow L. Successful treatment of acrodermatitis continua of Hallopeau with etretinate. *J Am Acad Dermatol*. 1990;6:1176–1178.

49. DiGiovanna JJ, Helfgott RK, Gerber LH, Peck GL. Extraspinal tendon and ligament calcification associated with longterm therapy with etretinate. *N Engl J Med*. 1986;315:1177–1182.

50. DiGiovanna JJ, Zech LA, Ruddel ME, Gant G, McClean SW. Etretinate: Persistent serum levels of a potent teratogen. *J Invest Dermatol*. 1984;82:434.

51. Goldfarb MT, Ellis CN, Gupta AK, et al. Acetretin improves psoriasis in a dose-dependent fashion. *J Am Acad Dermatol*. 1988;18:655–662.

52. Parrish JA, Fitzpatrick TB, Tanenbaun L, Pathak M. Photochemotherapy of psoriasis with oral methoxsalen and long-wave UVL. *N Engl J Med*. 1974;291:1207–1211.

53. Lowe NJ, Urbach F, Bailin P, Weingarten DP. Comparative efficiency of two dosage forms of oral methoxsalen in psoralen plus UVA therapy of psoriasis. *J Am Acad Dermatol*. 1987;16:994–998.

54. Wolff K, Honigsman H. Safety and therapeutic effectiveness of selected psoralens. *NCI Monogr*. 1982;66:159–164.

55. Fitzpatrick TB, Parrish JA. Non-melanoma skin cancer occurring in patients treated with PUVA five to ten years after first treatment. *J Invest Dermatol*. 1988;91:120–124.

56. Bruyuzeel I, Bergman W, Hartevelt HM, et al. "High single dose" European PUVA regimen also causes an excess of non-melanoma skin cancer. *Br J Dermatol*. 1991;124:49–55.

57. Stern RS. The photochemotherapy follow-up study group. Genital tumors among men with psoriasis exposed to psoralens and ultraviolet A radiation. *N Engl J Med*. 1990;322:1083–1097.

58. Hannuksela M, and Karvonen J. Trioxsalen bath plus UVA: Effective and safe in the treatment of psoriasis. *Br J Dermatol*. 1978;99:703–707.

59. Berne B, Fisher T, Michaelson G. Long-term safety of trioxsalen bath PUVA treatment: An 8-year follow-up of 149 psoriasis patients. *Photodermatol*. 1984;1:18–22.

60. Hannuksela M, Karvonen J. Carcinogenicity of trioxsalen bath PUVA. *J Am Acad Dermatol*. 1989;21:813–814.

61. Coleman WR, Lowe NJ, David M, Halder RM. Palmoplantar psoriasis: Experience with 8-methoxypsoralen soaks plus ultraviolet A with the use of a high output metal halide device. *J Am Acad Dermatol*. 1989;20:1078–1082.

62. Pillsbury DM, Livingood CS. Dermatology. In: Havens WP, ed. *Infectious Diseases and General Medicine*. In: Havens WP, Anderson RS, eds. *Internal Medicine in World War II*. Vol 3. Washington, DC: Medical Department, US Army, Office of The Surgeon General; 1968: 543–674.

63. Kuflik EG. Effect of antimalarial drugs on psoriasis. *Cutis*. 1980;26:153–155.

64. Olsen TG. Chloroquin and psoriasis. *Ann Intern Med*. 1981;94:546–547.

65. Wilson E. On lichen planus. *J Cutan Med*. 1969;3:112–132.

66. Fine JD, Arndt KA. Lichen planus. In: Demis DJ, ed. *Clinical Dermatology*. Philadelphia, Pa: JB Lippincott Co; 1980: Units 1-9, 1-22.

67. Arndt KA. Lichen planus. In: Fitzpatrick TB, Eisen AZ, Wolff K, Freedberg IM, Austen KF, eds. *Dermatology in General Medicine*. 3rd ed. New York, NY: McGraw-Hill Book Co; 1987: 967–973.

68. Shklar G. Lichen planus as an oral ulcerative disease. *Oral Surg*. 1972;33:376–388.

69. Copeman DW, Tan RS, Timlin D, Samman PD. Familial lichen planus: Another disease or a distinct people? *Br J Dermatol*. 1978;98:573–577.

70. Sodalfy M, Vollium DI. Familial lichen planus: A case report. *Br J Dermatol*. 1978;98:579–581.

71. Stankler L, Ewen SWB. The effects of experimental skin damage in patients with lichen planus. *Br J Dermatol*. 1974;90:25.

72. Tomkins JK. Lichen planus: A statistical study of 41 cases. *Arch Dermatol*. 1955;71:519–525.

73. White CJ. Lichen planus: Critical analysis of 64 cases. *J Cutan Dis*. 1919;37:671–684.

74. Black MM. Lichen planus and lichenoid eruptions. In: Rook A, Eblong FJG, Wilkinson DS, Champion RH, Burton JL, eds. *Textbook of Dermatology*. 4th ed. Oxford, England: Blackwell Scientific Publications; 1986: 1665–1685.

75. Cram DL, Kierland RR, Winkelman RK. Ulcerative lichen planus of the feet. *Arch Dermatol*. 1966;93:692–701.

76. Crotty CP, Su WPD, Winkelman RK. Ulcerative lichen planus. *Arch Dermatol*. 1980;116:1252–l256.

77. Samman PD. Lichen planus: Analyses of 200 cases. *Trans St Johns Hospital Dermatol Soc*. 1961;46:36–38.

78. Kanwar AJ, Singh OP. Leukoderma as a sequela of lichen planus. *Arch Dermatol*. 1978;114:130.

79. Marks R, Samman PD. Isolated nail dystrophy due to lichen planus. *Trans St John's Hospital Dermatol Soc*. 1972;58:93–97.

80. Burgoon CF. Lichen planus limited to the nails. *Arch Dermatol*. 1969;100:371.

81. Scher RK, Fischbein R, Ackerman AB. Twenty-nail dystrophy: A variant of lichen planus. *Arch Dermatol*. 1978;114:612–613.

82. Wilkinson JD, Dawber RPR, Bowers RP. Twenty-nail dystrophy of childhood: Case report and histopathological findings. *Br J Dermatol*. 1979;100:217–22l.

83. Altman J, Perry HO. Variations and course of lichen planus. *Arch Dermatol*. 1961;84:179–191.

84. Scully C, El-Kom M. Lichen planus review and update on pathogenesis. *J Oral Path*. 1985;14:431–458.

85. Andreason JO. Oral lichen planus: A clinical evaluation of 115 cases. *Oral Surg*. 1968;25:31–42.

86. Silverman S, Griffith M. Studies on oral lichen planus. *Oral Surg*. 1974;32:705–710.

87. Thorn JJ, Holmstrup P, Rindum J, Pindberg JJ. Course of various clinical forms of oral lichen planus. A prospective follow-up study of 611 patients. *Oral Pathol*. 1988;17:213–218.

88. Holmstrup P, Thorn JJ, Rindum J, Lindberg JJ. Malignant development of lichen planus-affected oral mucosa. *J Oral Pathol*. 1988;17:219–225.

89. Korkij W, Chuvang T, Saltani K. Liver abnormalities in patients with lichen planus. *J Am Acad Dermatol*. 1984;11:609–615.

90. Mokni M, Rybojad M, Puppin D, et al. Lichen planus and hepatitis C virus. *J Am Acad Dermatol*. 1991;24:792.

91. Powell FC, Rogers RS, Dickson ER. Primary biliary cirrhosis and lichen planus. *J Am Acad*. 1983;9:540–545.

92. Alario A, Ortonne J, Schmitt D, Thivolet J. Lichen planus: Study with anti-human T lymphocyte antigen serum on frozen tissue section. *Br J Dermatol*. 1978;98:601–604.

93. Bjerke JR, Krogh HK. Identification of mononuclear cells in situ in skin lesions of lichen planus. *Br J Dermatol*. 1978;98:605–610.

94. Norris DA. Cytokine modulation of adhesion molecule in the regulation of immunologic cytotoxicity of epidermal targets. *J Invest Dermatol*. 1990;95(Suppl):111–120.

95. Gonzales E, Montaz KT, Freedman S. Bilateral comparison of generalized lichen planus treated with psoralens and ultraviolet A. *J Am Acad Dermatol*. 1984;10:958–961.

96. Ortonne JP, Thivolet J, Sannwald C. Oral photochemotherapy in the treatment of lichen planus. *Br J Dermatol*. 1978;99:77–88.

97. Handler HL. Isotretinoin for oral lichen planus. *J Am Acad Dermatol*. 1984;10:674.

98. Vighoglia PA, Villaneuva CR, Martasano AD. Efficacy of acetretin in severe cutaneous lichen planus. *J Am Acad Dermatol*. 1990;5:852–853.

99. Seghal VN, Bickchandani R, Karanut RV. Histopathological evaluation of griseofulvin therapy in lichen planus: A double-blind controlled study. *Dermatologica*. 1980;161:22–27.

100. Levy A, Stempler D, Yuzuk S, Schewak-Miller M, Roneu M, Tel-Hashower I. Treatment of lichen planus with griseofulvin. *Int J Dermatol*. 1986;25:405.

101. Massa NC, Rogers RS. Griseofulvin therapy of lichen planus. *Acta Derm Venereol*. 1981;61:542–550.

102. Frances C, Boisnic S, Etienne S, Szpirglas H. Effect of the local application of cyclosporine A on chronic erosive lichen planus of the oral cavity. *Dermatologica*. 1988;177:194–195.

103. Eisen D, Ellis CN, Duell EA, Griffiths CEM, Vorhees JJ. Effect of topical cyclosporine rinse on oral lichen planus. *N Engl J Med*. 1990;323:290–294.

104. Bazemore JM, Johnson HH, Swanson ER, Hayman JM. Relation of quinacrine hydrochloride to lichenoid dermatitis (atypical lichen planus). *Arch Derm Syphilol*. 1946;54:308–324.

105. Livingood CS. Follow-up report of occurrence of an unusual skin disease. Report to Surgeon General. Washington, DC: Government Printing Office, 1945.

106. Nishber TW. A new cutaneous syndrome occurring in New Guinea and adjacent islands. Preliminary report. *Arch Derm Syphilol*. 1945;52: 221–225.

107. Schmitt CL, Alpins O, Chambers G. Clinical investigation of a new cutaneous entity. *Arch Derm Syphilol*. 1945;52:226–229.

108. Bagby JW. A tropical lichen planus-like disease. *Arch Derm Syphilol*. 1945;512:217–220.

109. Dilaimy M. Lichen planus subtropicus. *Arch Dermatol*. 1976;112:1251–1253.

110. Dostrovsky A, Sagher R. Lichen planus in subtropical countries. *Arch Derm Syphilol*. 1949;59:308–328.

111. Breserton EM, Carpenter RG, Rook AJ. The prevalence and prognosis of eczema and asthma in Cambridgeshire school children. *Medical Officer*. 1959:317.

112. Walker RB, Warren RP. The incidence of eczema in early childhood. *Br J Dermatol*. 1956;68:182.

113. Johnson ML. Prevalence of dermatologic disease among persons 174 years of age: United States. In: *Advance Data From Vital and Health Statistics, No. 4*. Washington, DC: National Center for Health Statistics: 1977.

114. Hanifin JM. Clinical and basic aspects of atopic dermatitis. In: *Seminars in Dermatology*. New York, NY: Thoieme-Stratton, Inc; 1983 (2): 5–29.

115. Rajka G. *Atopic dermatitis*. London, England: WB Saunders; 1975: 36.

116. Roth HL, Kierland R. The natural course of atopic dermatitis. *Arch Dermatol*. 1964;89:209–214.

117. Hanifen JM, Cooper KD, Roth HL. Atopy and atopic dermatitis. *J Am Acad Dermatol*. 1986;15:703–706.

118. Agrup G. Hand eczema and the hand dermatoses in south Sweden. *Acta Derm Venereol*. 1969;49:81–91.

119. Leves R. Hadley K, Downey D, Mackie R. Staphylococcal colonization in atopic dermatitis and the effect of topical mupirocin therapy. *Br J Dermatol*. 1988;119:189–190.

120. Masenga MD, Garbe C, Wagner J, Orianos CE. *Staphylococcus aureus* in atopic dermatitis and non-atopic dermatitis. *Int J Dermatol*. 1990;29:579–582.

121. Bibel DJ, Aly R, Shinefield HR, Maibach HI. The *Staphylococcus aureus* receptor for fibronectin. *J Invest Dermatol*. 1983;80:494–496.

122. Lopez JO, Reis MD, Bretani RR. Presence of laminin receptors in *Staphylococcus aureus*. *Science*. 1985; 229:275–277.

123. Boiko S, Kaufman R, Lucky AW. Osteomyelitis of the distal phalanges in three children with severe atopic dermatitis. *Arch Dermatol*. 1988;124:418–423.

124. Leung DYM, Wood N, Dubey D. Cellular basis of defective cell-mediated lympholysis in atopic dermatitis. *J Immunol*. 1983;130:1678–1682.

125. Wheeler CE Jr, Abele DC. Eczema herpeticum, primary and recurrent. *Arch Dermatol*. 1966;93:162–171.

126. Fivenson DP, Breneman D, Wonder AH. Kaposi's varicelliform eruption. *Arch Dermatol*. 1990;126:1037–1039.

127. Atherton DJ, Carabott F, Glover MT. The role of psoralen photochemotherapy (PUVA) in the treatment of severe atopic eczema in adolescents. *Br J Dermatol*. 1988;118:791–795.

128. Sekler S, Larko O. UVB phototherapy of atopic dermatitis. *Br J Dermatol*. 1988;119:692–705.

129. Jkler J, Larko O. Combined UVA-UVB versus UVB phototherapy for atopic dermatitis: A paired-comparison study. *J Am Acad Dermatol*. 1990;22:49–53.

130. Scholtz JR. Management of atopic dermatitis. *Calif Med*. 1965;102:210.

131. Jacobs AH. Atopic dermatitis. In: Sellis S, Kagan J, eds. *Current Pediatric Therapy*. 11th ed. Philadelphia, Pa: WB Saunders Co; 1984: 438–439.

132. Ayres S Jr. Atopic dermatitis: Papaverine therapy versus the Scholtz regimen. *J Amer Acad Dermatol*. 1986;15: 1052–1053.

133. Sulzberger MB. Atopic dermatitis: Its clinical and histologic picture. In: Baer RC, ed. *Atopic Dermatitis*. New York, NY: University Press; 1955: 11–42.

134. Glickman FS, Silvers SH. Hand eczema and atopy in housewives. *Arch Dermatol*. 1967;95:487–489.

135. Shmunes E, Kell JE. Occupational dermatoses in South Carolina: A descriptive analysis of cost variables. *J Am Acad Dermatol*. 1983;9:861–866.

136. Burrell BA, Halpean GM, Huntley AC. Chronic urticaria. *West J Med*. 1990;152:268–276.

137. Champion RH, Roberts SB, Carpenter RG. Urticaria and angiodema: A review of 554 patients. *Br J Dermatol*. 1969;81:588–597.

138. Sater NA. Urticaria: Current therapy. *J Allergy Clin Immunol*. 1990;86:1009–1014.

139. Champion RH. Urticaria: Then and now. *Br J Dermatol*. 1988;119:427–436.

140. Champion RH. A practical approach to the urticarial syndromes—a dermatologist's view. *Clin Exp Allergy*. 1990;20:221–224.

141. Sater NA, Wasserman SI. Physical urticaria and angioedema: An experimental model of mast-cell activation in humans. *J Allergy Clin Immunol*. 1980;66:358–365.

142. Daves JS, Black AK, Ward AM, Breaves MW. Delayed pressure urticaria. *J Am Acad Dermatol*. 1988;18:1289–1298.

143. Shuster S. Delayed shear-induced dermatographism and delayed pressure-induced dermatographism are distinct entities. *J Am Acad Dermatol*. 1989;21:588–589.

144. Gorevik PO, Kaplan AP. The physical urticarias. *Int J Dermatol*. 1980;19:417–435.

145. Illig L. Physical urticaria: Its diagnosis and treatment. *Curr Probl Dermatol*. 1973;5:79–116.

146. Neittoanmuki H. Cold urticaria: Clinical findings in 220 patients. *J Am Acad Dermatol*. 1985;13:636–644.

147. Douglas HMG, Blemink E. Familial cold urticaria. *Arch Dermatol*. 1974;110:382–386.

148. Bermen BA, Ross RN, Sly RM. Acquired cold urticaria. *Cutis*. 1983;32:20–32.

149. Rauits M, Armstrong RB, Harber LC. Solar urticaria: Clinical features and wave length dependence. *Arch Dermatol*. 1982;118:228–231.

150. Leiferman KM, Norris PG, Murphy GM, Hauk JL. Winkelman RK. Evidence for eosinophil degranulation with deposition of granular major basic protein in solar urticaria. *J Am Acad Dermatol*. 1989;21:75–80.

151. Leenutaphong V, Holzle E, Hewig G. Pathogenesis and classification of solar urticaria: A new concept. *J Am Acad Dermatol*. 1989;21:232–240.

152. Duschet P, Leyen P, Schwartz T. Solar urticaria treatment by plasmapheresis. *J Am Acad Dermatol*. 1988;15:712–713.

153. Parrish JA, Jarnicke KF, Morrison WL. Solar urticaria: Treatment with PUVA and mediator inhibitors. *Br J Dermatol*. 1982;106:575–580.

154. Bernhard JD, Japnicke K, Montaz TK, Parrish JA. Ultraviolet A phototherapy in the prophylaxis of solar urticaria. *J Am Acad Dermatol*. 1984;10:29–33.

155. Keahey TM, Lauker RM, Kaidbey FH. Studies on the mechanism of clinical tolerance in solar urticaria. *Br J Dermatol*. 1984;110:327–330.

156. Shelly WB, Rawasley HM. Aquagenic urticaria: Contact sensitivity reaction to water. *JAMA*. 1964;189:895–898.

157. Greaves MW, Black AK, Eady RA, Cautts A. Aquagenic pruritus. *Br Med J*. 1981;282:2003–2010.

158. Epstein PA, Kidd KK. Dermodistortive urticaria: An autosomal dominant dermatologic disorder. *Am J Med Genet*. 1981;96:307–315.

159. Weues MH, Metzger WJ, Simon RA. Occupationally acquired vibratory angioedema with secondary carpal tunnel syndrome. *Ann Int Med*. 1983;98:44–46.

160. Lawlor F, Black AK, Breathnack AS, Greaves MW. Vibratory angioedema: Lesion induction, clinical features, laboratory and ultrastructural findings and response to therapy. *Br J Dermatol*. 1989;120:93–94.

161. Tatnall FM, Gaylarde PM, Saskaney I. Localized heat urticaria and its management. *Clin Exp Dermatol*. 1984;9:367–374.

162. Sheffner AL, Soter NA, McFadden ER. Exercise-induced anaphylaxis: A distinct form of physical allergy. *J Allergy Clin Immunol*. 1983;71:311–316.

163. Pecquet C, Leynadier F, Dry J. Contact urticaria and anaphylaxis to natural latex. *J Am Acad Dermatol*. 1990;22:631–633.

164. McDuffie FC, Sams WM, Maldonado JE. Hypocomplementemia with cutaneous vasculitis and arthritis. *Mayo Clin Proc*. 1973;48:340–348.

165. Black AK, Greaves MW, Champion RH, Pye RJ. The urticarias: 1990. *Br J Dermatol*. 1991;124:100–108.

166. Dahl MV. *Clinical Immunodermatology*. Chicago, Ill: Yearbook Medical Publishers; 1988: 133–134.

167. Monroe EW, Cohen SH, Kalbfleisch J, Schulz CI. Combined H_1 and H_2 antihistamine therapy in chronic urticaria. *Arch Dermatol.* 1981;117:404–407.

168. Green SL, Reed LE, Schroeter AL. Double-blind crossover study comparing doxepin with diphenhydramine for the treatment of chronic urticaria. *J Amer Acad Dermatol*. 1985;12:669–675.

169. Monrop EW. Chronic urticaria: Review of nonsedating H_1 antihistamines in treatment. *Arch Dermatol*. 1988;19: 842–849.

170. Alexander AM, Delph WI. Pseudofolliculitis barbae in the military: A medical, administrative, and social problem. *J Natl Med Assoc*. 1974;66:459–464.

171. Brauner GJ, Flaudesmeyer KL. Pseudofolliculitis barbae: Medical consequences of interracial friction in the US Army. *Cutis*. 1977;23:61–66.

172. Strauss JS, Kligman AM. Pseudofolliculitis of the beard. *Arch Dermatol*. 1956;74:533–542.

173. Steggerda M. Cross section of human hair from four racial groups. *J Hesed*. 1940;31:475.

174. Strauss J, Kligman A. Pseudofolliculitis of the beard. *Arch Dermatol*. 1956;74:533–542.

175. Craig G. Shaving. *Arch Dermatol*. 1955;71:11.

176. Coute MS, Lawrence JE. Pseudofolliculitis barbae: No "pseudo problem." *JAMA*. 1979;241:53–54.

177. Brown LA. Pathogenesis and treatment of pseudofolliculitis barbae. *Cutis*. 1983;32:373–375.

178. Kenney JA. Management of dermatoses peculiar to Negroes. *Arch Dermatol*. 1965;91:126–l29.

179. Garcia RL, Henderson R. The adjustable rotary electric razor in the control of pseudofolliculitis barbae. *J Assoc Milit Dermatol*. 1978;4:28.

180. Alexander AM. Evaluation of foil-guarded shaver in the management of pseudofolliculitis barbae. *Cutis*. 1981;27:534–542.

181. de la Guardia M. Facial depilatories on black skin. *Cosmet Toilet*. 1976;91:37–38.

182. Halder RM. Pseudofolliculitis barbae and related disorders. *Dermatol Clin*. 1988;6:402–412.

183. Edlich RF, Haines PC, Nichter LS, Silloway KA, Morgan RF. Pseudofolliculitis barbae with keloids. *Arch Dermatol*. 1986;4:283–286.

184. Kligman AM, Mills OH. Pseudofolliculitis of the beard and topically applied tretinoin. *Arch Dermatol*. 1973;107: 551–552.

185. Halder RM. Pseudofolliculitis barbae and related disorders. *Practitioner*. 1989;233:307–309.

186. US Department of the Army. *Pseudofolliculitis of the Beard*. Washington, DC: DA; 1983. Technical Bulletin MED 287.

187. Nahmias AJ. Herpesviruses from fish to man—a search for pathobiologic unity. *Pathobiol Annu*. 1972;2:153–182.

188. Nahmias AJ, Roizmea B. Infection with herpes simplex virus 1 and 2. *N Engl J Med*. 1973;289:667–674, 719–725, 781–789.

189. Davis LE, Redman JC, Skipper BJ, McClaren LC. Natural history of frequent recurrences of herpes simplex labialis. *Oral Surg*. 1988;66:558–561.

190. Corey L, Spear PG. Infections with herpes simplex viruses. *N Engl J Med*. 1986;314:686–691, 749–757.

191. Hale BD, Rendtoff RC, Walker LC, Roberts AN. Epidemic herpetic stomatitis in an orphanage nursery. *JAMA*. 1963;183:1068–1072.

192. Spruance SL. Pathogenesis of herpes simplex labialis: Excretion of virus in the oral cavity. *J Clin Microbiol*. 1984;19:675–679.

193. Scully C. Orofacial herpes simplex virus infections: Current concepts in the epidemiology, pathogenesis and treatment, and disorders in which the virus may be implicated. *Oral Surg*. 1989;68 701–710.

194. Fiumara NJ. Herpes simplex. *Clinics in Dermatology*. 1989;7:23–36.

195. Molin L. Oral acyclovir prevents herpes simplex virus associated erythema multiforme. *Br J Dermatol*. 1987;116:109–111.

196. Penneys NS, Goldstein B, Nahass GT, Leonardi C, Zhu W. Herpes simplex virus DNA in occult lesions: Demonstration by the polymerase chain reaction. *J Am Acad Dermatol*. 1991;24:689–692.

197. Raborn GW, McGow WT, Grace M, Percy J, Samuels S. Herpes labialis treatment with acyclovir 5% modified aqueous cream: A double-blind randomized trial. *Oral Surg*. 1989;67:676–679.

198. Spruance SL, Stewart JCB, Rowe NH, McKeogh MB, Wenerstrom G, Freeman DL. Treatment of recurrent herpes simplex labialis with oral acyclovir. *J Infect Dis*. 1990;161:185–190.

199. Spruance SL. Cutaneous herpes simplex virus lesions induced by ultraviolet radiation. *Am J Med*. 1988;85(suppl 2A):43–45.

200. Green JA, Spruance SL, Wenerstrom G, Plepkorn WM. Post-herpetic erythema multiforme prevented with prophylactic oral acyclovir. *Ann Intern Med*. 1985;102:632–633.

201. Spruance SL, Hamill ML, Hoge WS, Davis G, Mills J. Acyclovir prevents reactivation of herpes labialis in skiers. *JAMA*. 1988;260:1597–1599.

202. Wilson JB. Thirty-one years of herpes zoster in a rural practice. *Br Med J*. 1986;293:1349–1351.

203. Ragozzino WM, Melton LJ, Kurland LT. Risk of cancer after herpes zoster: A population-based study. *N Engl J Med*. 1982;307:393–397.

204. Guess HA, Broughton DD, Melton LJ. Epidemiology of herpes zoster in children and adolescents: A population-based study. *Pediatrics*. 1985;76:512–517.

205. Hope-Simpson RE. The nature of herpes zoster: A long-term study and a new hypothesis. *Proc R Soc Lond*. l965;58:9–20.

206. Liesgang TJ. The varicella-zoster virus: Systemic and ocular features. *J Am Acad Dermatol*. 1984;11:165–191.

207. Burgoon CF Jr, Burgoon JS, Baldridge GD. The natural history of herpes zoster. *JAMA*. 1957;164:265–269.

208. Blumberg EA, Molavi A. Herpes zoster. *Clin Dermatol*. l989;7:37–48.

209. Huff JC, Bean B, Balfour HH. Therapy of herpes zoster with oral acyclovir. *Am J Med*. 1988;85(suppl 24)84–88.

210. McKendrick MW, Negill JI, White JE, Wood MJ. Oral acyclovir in acute herpes zoster. *Br Med J*. 1986;293: 1529–1532.

211. McKendrick MW. Oral acyclovir in herpes zoster. *Scand J Infect Dis*. 1985;47:76–79.

212. Biron KK, Elion GB. In vitro susceptibility of varicella-zoster virus to acyclovir. *Antimicrob Agents Chemother*. 1980;18:443–447.

213. Post BT, Philbrick JT. Do corticosteroids prevent postherpetic neuralgia? A review of the evidence. *J Am Acad Dermatol*. 1988;10:605–610.

214. Postelthwaite K. Molluscum contagiosum: A review. *Arch Environ Health*. 1970;21:432–452.

215. Brown ST, Nalley JF, Draus SL. Molluscum contagiosum. *Sex Transm Dis*. 1981;8:227–234.

216. Brown ST, Weinberger J. Molluscum contagiosum: Sexually transmitted disease in 17 cases. *J Am Vener Dis Assoc*. 1974;1:35–36.

217. Hawley TG. Molluscum contagiosum. *N Z Med J*. 1972;75:313.

218. Fischer B, Warner L. Cutaneous manifestations of the acquired immunodeficiency syndrome. *Int J Dermatol*. 1987;26:615–630.

219. Simienez AF, Casado M, Borbujo J, Soto MJ, Vegues JM, Sanjurjo MJ. Cutaneous cryptococcosis mimicking molluscum contagiosum in a hemophiliac with AIDS. *Clin Exp Dermatol*. 1987;12:446–450.

220. Piron L, Vaillunt L, Duong T, et al. *Acta Derm Venerol*. 1989;69:365–367.

221. Fireuson DP, Weltman RE, Cibson SH. Giant molluscum contagiosum presenting as basal cell carcinoma in an acquired immunodeficiency syndrome patient. *J Am Acad Dermatol*. 1988;19:912–914.

222. Weston WL, Lane AT. Should molluscum be treated? *Pediatrics*. 1980;65:865.

223. de Waad van der Spek FB, Aranje AP, Lillieborg S, Hop WC, Stolz E. Treatment of molluscum contagiosum using a lidocaine/prilocaine cream (EMLA) for analgesia. *J Am Acad Dermatol*. 1990;32:665–688.

224. Celmetti C, Cerri D, Schluma AA, Menni S. Treatment of extensive warts with etretinate: A clinical trial in 20 children. *Ped Dermatol*. 1987;4:254–258.

225. Lancaster WR, Olson C. Animal papillomaviruses. *Microbiol Rev*. 1982;46:191–207.

226. Beutner KR. Human papillomavirus infection. *J Am Acad Dermatol*. 1989;20:114–123.

227. Ciutto G. Innesto positivo con filtrato di versusue volgare. *Giorm Ital Mal Venereol*. 1907;48:12–17.

228. Fuchs PG, Girardi F, Pfistee H. Human papillomavirus DNA in normal, metaplastic, preneoplastic, and neoplastic epithelia, of the cervix uteri. *Int J Cancer*. l988;41:41–45.

229. Lutzer YA, Blanchet-Bardon C, Ortho G. Clinical observations, virologic studies and treatment trials in patients with epidermodysplasia verruciformis, a disease induced by specific human papilloma viruses. *J Invest Dermatol*. 1986;83:185–255.

230. Gasseumaler A, Pfister H, Horustein OP. Human papillomovirus 25-related DNA in solitary keratoacanthoma. *Arch Dermatol Res*. 1986;279:73–76.

231. Kawashima M, Jablonska S, Favre M. Characterization of a new type of human papillomavirus found in a lesion of Bowen's disease of the skin. *J Virol*. 1986;57:688–692.

232. Massing AM, Epstein WL. Natural history of warts. *Arch Dermatol*. 1963;87:306–310.

233. Mahrle G, Alexander W. Surgical treatment of recalcitrant warts. *J Dermatol Surg Oncol*. 1983;9:445–450.

234. Bunney MH, Nolan MW, Williams DA. An assessment of methods of treating viral warts by comparative treatment trials based on a standard design. *Br J Dermatol*. 1976;94:667–678.

235. Shumer S, O'Keefe E. Bleomycin in the treatment of recalcitrant warts. *J Am Acad Dermatol*. 1983;9:91–96.

236. McBurney E, Rosen D. Carbon dioxide laser treatment of verrucae vulgares. *J Dermatol Surg Oncol*. 1984;10:45–48.

237. Lockshin N. Flat facial warts treated with fluorouracil. *Arch Dermatol*. 1979;115:929–930.