Chapter 6

ALLERGIC AND IRRITANT CONTACT DERMATITIS

MARK A. CROWE, M.D.* AND WILLIAM D. JAMES, M.D.†

INTRODUCTION

ALLERGIC CONTACT DERMATITIS
- **Allergic Contact Dermatitis due to Plants: Offending Agents**
- **Allergic Contact Dermatitis due to Plants: Geographical Distribution**
- **Other Allergic Contact Dermatitides**

IRRITANT CONTACT DERMATITIS
- **Alkalis and Acids**
- **Hydrocarbons**
- **Diethyltoluamide Dermatitis**
- **Chloracne**
- **Irritant Contact Dermatitis due to Plants**

OTHER CONTACT DERMATITIDES
- **Mechanical Injury**
- **Pharmacological Reactions**
- **Contact Urticaria**

CONTACT DERMATITIS BY ANATOMICAL SITE
- **Eyelids**
- **Face**
- **Neck**
- **Trunk**
- **Abdomen**
- **Groin**
- **Hands and Feet**

PATCH AND USE TESTING

TREATMENT
- **Removal of the Irritant**
- **Nonsteroidal Therapy**
- **Steroids**

SUMMARY

*Lieutenant Colonel, Medical Corps, U.S. Army; Dermatology Service, Madigan Army Medical Center, Tacoma, Washington 98431-5000; formerly, Walter Reed Army Medical Center, Washington, D.C. 20307-5001
†Colonel, Medical Corps, U.S. Army; Chief, Dermatology Service, Walter Reed Army Medical Center, Washington, D.C. 20307-5001

INTRODUCTION

One of the most frequent dermatologic disorders requiring both outpatient and inpatient therapy that arises during military conflicts is dermatitis caused by contact with exogenous materials. In some regions of the world, contact dermatitis produces a significant proportion of those battlefield casualties that are dermatologic in nature.[1] During World War II, the Office of The Surgeon General reported 75,371 hospital admissions for treatment of contact dermatitis, with over 99% of those soldiers being returned to duty.[1] Under wartime conditions, inadequate facilities may limit proper personal hygiene, and the exposure to common chemical irritants and allergens can be prolonged.

During World War II, toxicodendrons (poison ivy and related plants) were the most frequent cause of plant dermatitis,[2] and reactions to topical therapies were also exceedingly common.[3–5] In 1944, Woolhandler[6] reported that over 10% of his military dermatologic practice was related to contact dermatitis, with fungus infections being the only dermatologic disorder that was more frequent. After the war, a report[7] of cutaneous diseases in U.S. Army Air Force personnel revealed that contact dermatitis to greases, solvents, and zinc chromate was the most common skin disease encountered. In this population, contact dermatitis was more frequent than pyodermas, fungus infections, or verrucae.

More recently, Allen reported that contact dermatitis was infrequent among troops in Vietnam but at times was an important source of discomfort and disability.[8] Although contact dermatitis resulted in only a small percentage of the total number of clinic visits to the 95th Evacuation Hospital in Da Nang, Vietnam, it was listed as one of the top ten dermatologic conditions treated.[8] Contact dermatitis also caused many minor casualties who were treated at battalion aid stations and returned to duty. Much of the decrease (from World War II rates) in the rate of contact dermatitis casualties referred to the evacuation hospital in Vietnam was believed to be related to the development of antibiotics, steroid preparations, and nonsensitizing creams after World War II. Thus, there is extensive information suggesting that contact dermatitis results in a constant drain on troop strength and readiness.[8] In addition, a delay in diagnosis may result in the prolonged loss of a soldier to a disorder that can be treated easily and effectively.

With the exception of phytodermatitis (plant-related dermatitis), contact dermatitis related to individual contactants rarely causes a significant impact on troop strength. The most likely situation in which contact dermatitis might produce significant numbers of casualties is if large numbers of soldiers were exposed to the same chemical agents (eg, mass exposure of soldiers in Vietnam to insect repellents and defoliants). Additional casualties can be avoided if the causative agent is identified and further exposure prevented.

In general, because dermatologic diagnoses tend to rely heavily on visual clues, the clinical history is less important to dermatologists than it is to most subspecialists. However, in the field of contact dermatitis, a detailed history is extremely important. When contact dermatitis is suspected and the contactant is not obvious, the medical officer must specifically query the soldier regarding environmental exposures. An occupational exposure history should include a detailed description of daily activities with emphasis on exposures to materials such as paints, dyes, cleaning solutions, soaps, and other materials used in the work environment. Often a site visit is productive. The soldier should be asked whether symptoms improve or worsen over weekends or vacations. It is important to inquire into exposures in the home and during recreational activities, exposures related to hobbies, and exposures from the use of any topical or oral therapy.

This chapter will emphasize potential sources of contact-related dermatitis in a battlefield environment. The modern U.S. Army includes support personnel who perform essentially every occupation encountered in the civilian sector, from combat laundry to the maintenance of sophisticated hardware. Materials other than plants that have resulted in contact dermatitis will be discussed if they have particular significance or are unusual and enlightening causes of contact dermatitis. Several excellent texts cover the topic of contact dermatitis in great detail.[9–11]

ALLERGIC CONTACT DERMATITIS

Contact dermatitis is generally subdivided into allergic contact dermatitis (ACD) and irritant contact dermatitis. ACD is an acquired, type IV hypersensitivity response generated after exposure to an allergen. Not everyone will react to the allergen, and the allergic response does not occur during the primary exposure unless the soldier has been exposed to a closely related compound in the past.

Type IV hypersensitivity reactions consist of two distinct phases: the induction phase and the elicitation phase. During the induction phase, an allergen, or hapten, penetrates the epidermis where it is picked up and processed by an antigen presenting cell. Antigen presenting cells include Langerhans cells, dermal dendrocytes, and macrophages. The processed antigen is then presented to T lymphocytes, which undergo blastogenesis in the regional lymph nodes. One subset of these T cells differentiates into memory cells, while others become effector T lymphocytes that are released into the bloodstream.

The elicitation phase occurs when the sensitized individual is reexposed to the antigen. The antigen penetrates the epidermis and is again picked up and processed by an antigen presenting cell. The processed antigen is then presented to the circulating effector T lymphocytes, which, in turn, produce lymphokines. These lymphokines mediate the production of the inflammatory response that is characteristic of an ACD.

As a type IV hypersensitivity reaction, ACD has symptoms that usually develop hours to days after exposure. The dermatitis associated with allergic reactions is frequently very pruritic and may extend beyond the borders of the region exposed to the allergen. ACD is generally much more edematous and vesiculation is much more common than that seen in an irritant contact dermatitis. Relative to irritant contactants, very small quantities of allergens are required to stimulate allergic dermatitis. The most common causes of ACD are toxicodendrons (poison ivy, oak, or sumac), *p*-phenylenediamine, nickel, rubber compounds, ethylenediamine, potassium dichromate, and thimerosal.[9]

Patch testing can often confirm the etiology of an ACD. By placing standard concentrations of common allergens or specific ingredients in an implicated product on the skin and leaving them covered for 2 days, one can identify the cause of the dermatitis. If the soldier has been previously sensitized to one of the agents under occlusion, the reexposure will produce the elicitation phase of a type IV hypersensitivity reaction resulting in pruritus, erythema, and vesiculation.

Irritant dermatitis, which is also called primary irritant dermatitis, is due to a nonallergic reaction resulting from exposure of the skin to an irritating substance and is much more common than ACD. Examples of irritant contact dermatitis include the reactions that result from contact with acids; alkalis; and metal salts such as cyanides of calcium, copper, mercury, nickel, silver, and zinc. Contact with the halogens and many hydrocarbons also produces irritant dermatitides. With a high-enough concentration, an irritant will cause dermatitis in any individual and the reaction may follow the first exposure. Significantly higher concentrations are required to induce irritant contact dermatitis than are required to stimulate an allergic reaction.

Soldiers with an irritant contact dermatitis may develop symptoms within minutes of the exposure. The dermatitis is often localized to the site of exposure and a burning sensation is more common than the intense pruritus often associated with ACD. The severity of the dermatitis depends on the concentration and dwell time of the irritant as well as the site and condition of the skin. Areas of the body with thick, dry skin are the most resistant to the effects of irritants.

Allergic Contact Dermatitis due to Plants: Offending Agents

The family Anacardiaceae probably accounts for more cases of ACD than all other plant families combined. It is composed of about 70 genera and 600 species of trees, shrubs, and vines that are found mostly in the tropics but with some species in temperate regions. Genera of the family Anacardiaceae include *Anacardium, Gluta, Mangifera, Semecarpus,* and *Toxicodendron*. Poison ivy, poison oak, and poison sumac were classified in the genus *Rhus* until recently, when they were reclassified to the genus *Toxicodendron*. For example, poison ivy is

now termed *Toxicodendron radicans* rather than *Rhus radicans*. True members of the genus *Rhus* rarely cause contact dermatitis. The term rhus dermatitis is still commonly encountered and refers generically to ACD produced by exposure to poison ivy, poison oak, or poison sumac.

The antigen in these plants is an oleoresin known as urushiol, from the Japanese word kiurushi, meaning sap.[12] In poison ivy and poison oak, the active agent in urushiol is pentadecylcatechol. Slight molecular variations in catechols may result in large variations in the degree of antigenicity. Poison ivy and poison oak sap contain a near maximal percentage of these allergenic catechols.[13]

Prevention of ACD begins by educating the soldier in the recognition of common plants that may produce eruptions. The soldier should keep exposed skin to a minimum when in areas of high risk for exposure to toxicodendrons. If exposure to contactants is suspected, the exposed skin should be washed thoroughly with soap and water as soon as feasible. Soldiers returning from an area endemic for toxicodendrons should shower with soap to remove residual allergens. Soldiers should also be aware that plant resins on clothing, field jackets, and equipment can produce ACD many months after it was deposited.

Poison Ivy and Poison Oak

Plants in the genus *Toxicodendron* produce a large percentage of the cases of phytodermatitis. The genus *Toxicodendron* includes two species of poison ivy, *Toxicodendron rydbergii*, a nonclimbing shrub, and *T radicans*, which can be either a shrub or a climbing vine. In addition, there are many subspecies of *T radicans* (Figures 6-1 and 6-2). The genus *Toxicodendron* also includes western poison oak (*T diversilobum*—Figure 6-3), eastern poison oak (*T toxicarium*—Figure 6-4), and poison sumac (*T vernix*). These plants do not contain resin canals and consequently uninjured plants do not induce a dermatitis: the plant must be injured or bruised before oleoresin containing the urushiol can contact the skin. Smoke from burning plants can cause a severe dermatitis. All parts of the plant are antigenic and, under controlled conditions, over 70% of the population in the United States will react to the urushiol in poison ivy and oak.[14] Vernacular names for poison ivy include (English) climbing or three-leaved ivy, climath, trailing or climbing sumac, mercury, black mercury vine, markry, mark-weed, picry; (French) *sumac radicant*, *lierre toxique*; and (German) *Kletter-Gift Sumach*, *Rankender Sumach*, and *Gift Efeu*. Vernacular names for poison oak include (English) western or Pacific poison oak, eastern poison oak; (French) *sumac irrégulièrement lobé*; and (German) *Verschiedenlappiger Sumach*.[10]

Oleoresin adheres to skin, clothes, equipment, and pets. Contaminated clothes can cause the eruption to recur even after prolonged storage. Oleoresin on the hands can be unintentionally spread to the face and genitals resulting in very severe eruptions (Figures 6-5 and 6-6). Blister fluid, on the other hand, does not contain urushiol and will not result in further contamination of the affected soldier or care providers.

The oleoresin that exudes from damaged areas of poison ivy, poison oak, and poison sumac will frequently form into a black deposit on the leaves, stems, or trunk. The patient seen in Figure 6-7 developed a characteristic dermatitis after exposure to oleoresin from poison ivy. In addition, the oleoresin on the skin darkened into a black, enamellike deposit. This characteristic of the oleoresin to darken on exposure to the air is found in many other members of the Anacardiaceae family. Beaman[15] reported sleeping on a foundation of poles in an area of rocky terrain in Malaysia. The next morning he discovered the poles, which were most likely from a species of *Gluta* that had been cut by his guide, had developed obvious black deposits. Dermatitis developed within 15 to 20 hours. It is this same attribute of the oleoresin that makes it useful as a marking agent when obtained from *Semecarpus anacardium* (the India marking nut tree) and that produces the color associated with the lacquer of the Japanese lacquer tree (*T verniciflua*). Leaves from plants suspected of being related to poison ivy can be crushed between sheets of white paper. The leaves are discarded and the oleoresin on the paper allowed to dry for a few minutes. Oleoresin from *Toxicodendron* should darken markedly.[16] Although no one characteristic is reliable for identifying *Toxicodendron*, the finding of dark black deposits on damaged plants and trees should alert the physician to the distinct possibility that the sap or resin can produce ACD.

Signs and Symptoms. Clinically, the typical urushiol eruption is manifested by erythema, edema, papules, vesicles, and bullae (Figure 6-8). Linear streaks are characteristic, but not always noted. Daily contact with the plant may result in an eruption 9 to 14 days after initial contact even in someone not previously sensitized.[14] In previously sensitized individuals the eruption can occur within hours to several days of exposure. Different parts of the body are more sensitive to urushiol or may be

Fig. 6-1. *Toxicodendron radicans* subsp *radicans.* Poison ivy species found commonly in the eastern United States. The mature plant has leaflets that are usually unlobed and ovate (widest below the center). It climbs by aerial rootlets. Reprinted courtesy of J. D. Guin, Department of Dermatology, University of Arkansas, Fayetteville, Ark.

Fig. 6-2. *Toxicodendron radicans* subsp *radicans.* Poison ivy species found commonly in the eastern United States. Reprinted courtesy of J. D. Guin, Department of Dermatology, University of Arkansas, Fayetteville, Ark.

Fig. 6-3. Western poison oak (*Toxicodendron diversilobum*). This plant grows in a variety of soil types in California, Oregon, and Washington. It may develop aerial roots and climb, although it is often seen as a shrub. The fruit is the largest of any of the toxicodendrons and often dangles like ripe cherries. The leaflets have rounded lobes resembling the leaves of a live oak. Reprinted courtesy of J. D. Guin, Department of Dermatology, University of Arkansas, Fayetteville, Ark.

Fig. 6-4. Eastern poison oak (*Toxicodendron toxicarium*). Much smaller than western poison oak, this plant is found primarily in the southeastern United States. It is a small subshrub that does not climb, does not have aerial rootlets, and is found in sandy soil with poor mineral content. Leaflet morphology is extremely variable and may closely resemble white oak leaves. Reprinted courtesy of J. D. Guin, Department of Dermatology, University of Arkansas, Fayetteville, Ark.

Fig. 6-5. Rhus dermatitis. Oleoresin may be easily spread from the hands to other sites of the body, as in this patient. Severe facial dermatitis may also result when sensitized soldiers are exposed to smoke from burning toxicodendrons.

Fig. 6-7. Rhus dermatitis. The black deposit is residual oleoresin that has turned black on exposure to the air. Many members of the family Anacardiaceae possess this characteristic. Damaged trees and shrubs may develop black deposits as oleoresin oxidizes on exposure to the air.

Fig. 6-6. Rhus dermatitis involving the genital region. Oleoresins on the hands may be spread to this area of thin skin during the process of voiding, with unfortunate results. Severe perianal dermatitis may result when leaves are used to wipe the area following defecation. Reprinted courtesy of L. Lieblich, Department of Dermatology, State University of New York Downstate.

Fig. 6-8. Typical rhus dermatitis with linear vesicles, erythema, edematous papules, and bullae. The allergen that produces this dermatitis is an oleoresin, urushiol.

exposed at different times, resulting in the false impression that the eruption is spreading or is infectious. On rare occasions *Toxicodendron* exposure can result in urticaria or an erythema multiforme pattern.[14]

Field Identification. Several features of poison ivy, oak, and sumac may be useful in field identification. All species of poison ivy and oak have three leaflets per leaf (see Figures 6-1 through 6-4). Poison sumac contains 7 to 13 leaflets per leaf. The leaf stalk (petiole) has a groove where it attaches to the branch. Blooms and fruits arise in the angle between the leaf and the branch. Toxicodendrons change color earlier than most other plants. Old flower and fruit stalks often persist through the winter and the following growing season. Young leaves are frequently reddish in color and the mature fruit of toxicodendrons is tan or cream colored.[13]

The plant family Anacardiaceae has many other species that contain urushiol and also cross-react with poison ivy. The following plants are discussed because they represent a common source of sensitization in certain regions of the world or are of historical interest.

Poison Sumac

Poison sumac (*T vernix, T pinnatum, Rhus venerata)* is a shrub or small tree usually only 2 to 3 m tall but occasionally as tall as 7 m. Compound leaves are up to 40 cm in length with 7 to 13 oval leaflets. Poison sumac is highly antigenic, resulting in severe contact dermatitis in sensitized soldiers. It is a native plant of eastern North America, growing in swampy areas. A related species, *T succedanea,* known as the wax tree, is native to Japan and China. *T succedanea* is used as a source of lacquer in Indochina and as a source of wax in Japan. Vernacular names include (English) poison sumac, poison dogwood, swamp sumac, poison elder; (French) *sumac vernig, bois chandler*; and (German) *Giftsumach*.[10,13,14]

India Marking Nut Tree: "Dhobie Mark" Dermatitis

During World War II in the China-Burma-India theater of operations, service personnel developed an epidemic of patchy dermatitis caused by exposure to the India marking nut tree. The dermatitis consisted of circumscribed patches of intense pruritus, vesiculation, oozing, and, sometimes, a more chronic eczematoid reaction.[17]

In India and Malaysia, the black sap of the *Semecarpus anacardium* (also called the Ral or Bella gutti [bhilawa]) tree is used as marking ink, hence its common name, marking nut tree. A pin is used to pierce the hard capsule of the nut and enough brown or black fluid is obtained to place a relatively permanent identifying mark on garments. Further investigation at the time revealed that this tree is a member of the Anacardiaceae family and is related to poison ivy. Shortly after their arrival, service personnel began having their clothes laundered by native washermen (dhobies). The service personnel developed patches of dermatitis at the site of the laundry (dhobie) mark.[17]

Fifteen to twenty percent of personnel whose clothes were laundered by dhobies developed dhobie mark dermatitis.[17] Most soldiers who react to poison ivy will develop an allergic dermatitis to the nut of the marking nut tree and to other plants and trees in this family. Before World War II, this condition had been known as dhobie itch or washerman's itch and was believed to result from a tropical dermatophytosis. In India and other countries, the terms dhobie itch and tinea cruris are sometimes used interchangeably.[17] However, it was never proved that cutaneous fungal infections resulted from having clothes washed by dhobies. Dhobie itch or dhobie mark dermatitis is a true ACD resulting from contact with a marking fluid that contains allergens very similar to those seen in poison ivy.[17]

The marking nut tree is a moderate-sized deciduous tree with large alternate, leathery oblong leaves measuring 20 to 60 cm long and 10 to 25 cm across. Flowers are small and greenish white, on stout, branching panicles about the same length as the leaves. The fruit is a 2.5-cm-long, smooth, black nut (Figure 6-9). The tree is native to India. Two related species (*S forstenii* and *S heterrophylla*) located in Java and Sumatra are also potent sensitizers. About 60 related species are distributed from India to Ceylon, Burma, Thailand, Indochina, Taiwan, Australia, Micronesia, the Solomon Islands, New Caledonia, and Fiji. Contact dermatitis can result from contact with the stem, small branches, leaves, or juice of the nut. Vernacular names include (English) marking nut tree, bhilawa tree; (French) *anacarde d'orient*; and (German) *Tintenbaum*.[1,10,17,18]

Japanese Lacquer Tree

The Japanese lacquer tree (*T verniciflua*) is 15 to 20 m tall with 25- to 50-cm-long leaves composed of 7 to 13 oblong or oval leaflets (Figure 6-10). The tree is native to Japan and central and western

Fig. 6-9. The nut of the marking nut tree or bhilawa of India (*Semecarpus anacardium*). Resins were removed by piercing the nut with a needle. As with other members of the family Anacardiaceae, the fluid turns black after exposure to the air. The black resin was used by washermen to mark clothing. This resulted in contact dermatitis at the site of the laundry mark. Reprinted courtesy of J. D. Guin, Department of Dermatology, University of Arkansas, Fayetteville, Ark.

Fig. 6-10. Japanese lacquer tree (*Toxicodendron verniciflua*). The tree grows up to 20 m in height and is native to Japan and central and western China. Leaves are odd-pinnate. Reprinted courtesy of J. D. Guin, Department of Dermatology, University of Arkansas, Fayetteville, Ark.

China. Its sap is used as lacquer in varnishes for floors and for lacquering boxes, tea pots, and furniture. "Lacquer dermatitis" affects areas of the body that come in contact with a lacquered surface. After World War II, American soldiers who were sensitive to poison ivy developed dermatitis after handling Japanese rifles that had been lacquered, and 12 American officers developed dermatitis on their arms from leaning on a recently varnished bar in Japan.[19] There are occasional reports of dermatitis to lacquered furniture even hundreds of years after application. Vernacular names include (English) Japanese lacquer tree, varnish tree; (French) *sumac a laque, vernis urai*; (German) *Lacksumach*; (Japanese) *urushi*; and (Chinese) *qi su*.[10,20,21]

Mango

The mango (*Mangifera indica)* is a large tropical tree growing to heights of 15 to 18 m. The mango has wide, spreading branches, and produces a delicious greenish, yellowish, or reddish ovoid fruit measuring 10 to 20 cm in length (Figure 6-11). Some 35 species exist and are widely distributed naturally and through cultivation in Southeast Asia, India, Malaysia, and Burma. It is also extensively cultivated in tropical regions of southern Florida, Hawaii, and California, as well as Central and South America. Contact dermatitis develops most commonly in the perioral region (Figure 6-12) and on the hands and results from exposure to the peel, not the juice. The mango is eaten raw or made into jams, jellies, pickles, mango powder, and chutney. Timber is used for the production of furniture and boats, and for planking and plywood. The timber is known in some areas as asam. Vernacular names include (English) mango tree; (French) *manguier*; (German) *Mangobaum*; and many variations of mango such as mangii, mangga, manga, maga, and mangka.[10,11]

Cashew

The cashew (*Anacardium occidentale*) is a small (4–6 m) tree with a thick, crooked trunk that is native to Central America and northern South America and is cultivated throughout the tropical regions of the world and India. It is primarily cultivated for its nut, oil, and gum. Its timber, known as acajou, is used in house and boat building in South America. The wood produces a yellow gum that can blister the skin. Cashew sap blackens on exposure to the air and can produce contact dermatitis.

Fig. 6-11. Mango tree (*Mangifera indica*). Mango trees are widely distributed naturally and through cultivation. They grow to 18 m in height. Reprinted courtesy of J. D. Guin, Department of Dermatology, University of Arkansas, Fayetteville, Ark.

Fig. 6-12. Allergic contact dermatitis after consumption of a mango fruit. Dermatitis results from exposure to the peel, not the juice. Reprinted courtesy of R. Horn, Ithaca, N.Y.

Apples from the cashew may be red or yellow, and the cashew nut dangles from the apex. The cashew "apple" is not a fruit, but the thickened stem at the base of the cashew nut. The cashew nut is innocuous unless contaminated with the shell oil; smoke from fires used to roast the freshly fallen nuts may be irritating to the skin and mucous membranes. The gum is used as a varnish to protect books and woodcarvings. Dermatitis may result from contact with all parts of the cashew tree except the roasted nut. Vernacular names include (English) cashew nut tree; (French) *anacardier* (*noix et pomme d'acajou*); and (German) *Kaschu*, *Acajuba*, *Acajoubaum*, and *Westindischer Nierenbaum*.[10,22]

Ginkgo

The ginkgo (*Ginkgo biloba*) is now mostly grown as an ornamental tree in yards or along roadways in temperate regions. It is widely cultivated in Japan and is grown in Asia around Buddhist temples. The tree is sparsely branched and may grow to 40 m in height. Usually only the male plant is used in plantings because the female of the species produces yellowish fruits with a foul-smelling pulp and acidic outer coat (Figures 6-13 and 6-14). Epi-

Fig. 6-13. Ginkgo (*Ginkgo biloba*). The ginkgo is an ornamental tree which may grow to 40 m. This a male ginkgo. The female is seldom planted as an ornamental tree because the fruits are foul smelling and can produce allergic contact dermatitis. Reprinted courtesy of J. D. Guin, Department of Dermatology, University of Arkansas, Fayetteville, Ark.



Fig. 6-14. Ginkgo (*Ginkgo biloba*). Typical fan-shaped leaves and fallen fruit. Allergic contact dermatitis results from exposure to the fruit.

demic contact dermatitis may be produced in groups exposed to the fallen fruits.[23] The kernel of the fruit is sweet and edible. Ginkgolic acid is thought to be the possible allergen. Vernacular names include (English) maiden hair tree, gingko tree; (French) *arbre aux quarante écus*, *abricotier d'argent*; and (German) *Ginkyobaum*.[10,23,24]

Gluta

The genus *Gluta* of the family Anacardiaceae includes approximately 30 species of trees and large shrubs that are distributed throughout most of Southeast Asia. In this region *Gluta* is a major cause of dermatitis. The timber of many species has blood-red heartwood and like many of the Anacardiaceae, the sap turns black on exposure to air.

Furniture made from wood of a *Gluta* species can produce dermatitis in sensitized individuals years after being harvested.[15] Even sitting under these trees may produce a dermatitis due to resins being washed down from the leaves in raindrops.

Some species grow in peat swamps and along rivers, where they may be the dominant vegetation. Individual trees are also widely scattered in lowland forest regions of Borneo. Vernacular names include *rengas* or *renghas* (Malaya) and *jitong*.[15] Other names include *hangus* (Penang), *rangus* (Sankar), *ruengas* (Sudan), *ingas* (Indonesia), and *angus* and *ligas* (Philippines). These names are also used for many trees in the genus *Melanorrhoea,* which is now combined with *Gluta*.[20]

Allergic Contact Dermatitis due to Plants: Geographical Distribution

The standard approach for discussing plants that produce contact dermatitis is to identify a few important species, as was done in the preceding text. However, the military physician has a practical need to know which plants are common sensitizers in different climates and different continents. This regional report is not meant to serve local practitioners, who are usually well aware of the native plant offenders, but to help recently assigned medical officers, who are frequently unfamiliar with local flora. With the transplantation of exotic species to gardens in the United States, such a report also may benefit physicians in the United States. However, many factors make this approach difficult. Plant species can have a variety of common names and may vary markedly in appearance when grown in different climates within the same country. Limited botanical information is available from some areas or this information may be buried in encyclopedic floral reviews. An excellent attempt at this type of review can be found in *Clinics of Dermatology*, April–June 1986.[11] It is beyond the scope of this chapter to provide more than a short review of the worldwide significance and distribution of certain allergenic plants.

Hawaii

Although poison ivy, *T radicans*, is not found in Hawaii, related plants in the family (Anacardiaceae) are the most common cause of ACD. The mango (*M indica*) and the India marking nut tree (*S anacardium*) are in this family and are found in Hawaii. The flower of the kahili tree (*Grevillea banksii*) is a significant cause of ACD in Hawaii, but contact with other parts of the plant does not result in dermatitis.[25] The kahili is a small tree originally from Australia that produces cylindrical spikes of red or white flowers.

A photosensitive contact dermatitis may result from exposure to furocoumarin- (psoralen-) containing members of the Rutaceae family. The peel of limes (*Citrus aurantifolia*) and black seeds and leaves of the mokihana tree (*Pelea anisata*) contain psoralens. The black mokihana seeds are strung into leis.[26]

Seaweed dermatitis results in intense itching and burning and affected over 100 people after swimming in the ocean on the windward shore of Oahu in 1958.[27] The areas of the body that were affected were always areas that had been covered by bathing suits. Symptoms developed a few minutes to several hours after exposure. The affected areas often resembled an acute burn. The etiology has been proven to be a blue-green algae, *Microcoleus lyngbyaceus*. This algae has a pantropic distribution, and episodic cases have been reported elsewhere in the Pacific and in Florida.[27]

Nettle dermatitis may occur from exposure to the native nettle, *Hesperocnide sandwicensis*, or to the stinging nettle, *Urtica ureus*, which was accidentally introduced from the continental United States.

The Americas and the Caribbean

In North, Central, and South America and the Caribbean Islands, each region contains its own subspecies of Anacardiaceae with little or no crossover into neighboring areas. For example,

- the subspecies of poison ivy found commonly in the United States extend no farther south than Florida, the northern Bahamas,

and northern Baja California;

- the three subspecies of poison ivy in Mexico are found no farther north than the southern borders of Texas and Arizona;
- with few exceptions, dermatitis-producing Anacardiaceae of the genera *Metopium, Comcladia,* and *Pseudosmodingium* are restricted to Central America; and
- only two species from the genera of South American dermatitis-producing Anacardiaceae are indigenous to southern Central America.

Botanical information on Central America and the Caribbean is incomplete. Some flora studies[11] are being revised and few medical reports of plant dermatitis exist. Information is known about the introduced species such as the cashew, *A occidentale*, and the mango, *M indica*.[11,22] In addition, the Brazilian pepper tree, *Schinus terebinthifolius* (Figure 6-15), was introduced into these regions as an ornamental plant from South America. The cashew is found in much of the Caribbean and Central America. In these regions, the mango is the most popular fruit tree, having been introduced from tropical Asia. It is cultivated in areas of southern Florida, Texas, and California, and now grows throughout Central America and the Caribbean. *Laportea aestuans*, a stinging nettle with particularly persistent symptoms lasting a week or longer, has been accidentally introduced to southern Florida.[28]

Plants in the genus *Comocladia* are confined essentially to the Caribbean islands. *Comocladia glabra* is a small tree and like many plants that cause ACD, when damaged a whitish latex is produced that turns black on exposure to air.

Metopium consists of three species and is found in southern Florida, the West Indies, and Central America (southern Mexico, Belize, and Guatemala). Contact dermatitis can result from contact with all exterior parts of the tree except the pollen and wood (Figure 6-16). A large outbreak of dermatitis due to *Metopium* occurred among British Royal Air Force personnel clearing underbrush in the Bahamas.[29]

Four subspecies of *T radicans*, poison ivy, extend into southern Florida and Central America. *T striatum* is primarily a South American species, but it is very common in regions of Guatemala and

Fig. 6-15. Brazilian pepper tree (*Schinus terebinthifolius*). This tree is also known as Florida holly. Latex from the bark and crushed berries have been implicated as the most common cause of allergic contact dermatitis in south Florida. Reprinted courtesy of J. D. Guin, Department of Dermatology, University of Arkansas, Fayetteville, Ark.



Fig. 6-16. Poisonwood (*Metopium toxiferum*). This tree is found in the Florida Keys, the West Indies, and Central America. The leaves are pinnately compound, usually with five but sometimes three or seven leaflets. Allergic contact dermatitis results from exposure to all exterior parts of the tree. The bare wood and pollen are toxin free. Reprinted courtesy of J. D. Guin, Department of Dermatology, University of Arkansas, Fayetteville, Ark.

Costa Rica. Newly formed leaves are bright red, pinnate, and have 11 to 15 leaflets.

The Brazilian pepper tree, *Schinus terebinthifolius* (see Figure 6-15), is found in Florida, the Bahamas, Cuba, Puerto Rico, and Mexico. In Florida, where it is known as Florida holly, it has been implicated as the most common cause of ACD.[28]

The manchineel tree, *Hippomane mancinella*, or beach apple, grows in southern Florida, the West Indies, and Central America. Because of its reputation for producing dermatitis,[11,28] it has been eradicated from the inhabited parts of Florida and persists only in remote areas of the Everglades.

Appearing in protected areas away from the seashore, the beach apple is a compact, densely leaved tree about 10 m tall. The deciduous leaves are elliptical and glossy. It produces large numbers of small, pleasant-smelling, crabapplelike fruits (Figure 6-17). The manchineel exudes a creamy white latex that produces an irritant dermatitis. Biting into the fruit produces severe oral pain, profuse salivation, and occasional dysphagia. Keratoconjunctivitis and possibly an ACD may also be produced. Rain or dew falling off the leaves has been reported to produce conjunctivitis and dermatitis.[28]

Few Anacardiaceae have been described in South America, with the majority coming from the genera *Toxicodendron, Lithraea, Maurin, Tapirira,* and *Loxopterigium*. The cashew, mango, and Brazilian pepper tree are widespread and abundant in much of South America and are all well-known sources of contact dermatitis.

Fig. 6-17. Manchineel or beach apple (*Hippomane man-cinella*). The tree is compact and densely leaved, and grows to 10 m in height. Dermatitis can result from exposure to latex from the trunk, from the fruits, or from rain dripping from the leaves. Reprinted courtesy of J. D. Guin, Department of Dermatology, University of Arkansas, Fayetteville, Ark.

T succedanea, also known as charao or the Indochina lacquer tree, was introduced into Brazil from Indochina for the production of lacquer. *T verniciflua* and *T radicans* have also been cultivated in Brazil. *T diversilobum* has been cultivated in Argentina as an ornamental.

Lithraea caustica, or litre, is a large tree that grows abundantly in Chile and that to Chileans is synonymous with the family Anacardiaceae. Despite its high potential for causing contact dermatitis, it is burned as a source of heat and its hard wood is used in the construction of homes and boats. Several species of *Lithraea* cause contact dermatitis and all are generally restricted to southern South America.[30]

Asia

As elsewhere, in Asia members of the family Anacardiaceae probably cause more dermatitis than all other families combined. Asia may well have the greatest number of dermatitis-producing species of any continent, with some 250 native species. The largest concentration of Anacardiaceae is in Southeast Asia. Five genera are well known as documented causes of ACD: *Anacardium, Gluta, Mangifera, Semecarpus,* and *Toxicodendron.* Another group of genera probably contain plants of similar allergenic potency, but are much less well studied: *Campnosperma, Drimycarpus, Holigarna, Melanochyla, Nothopegia, Pentaspadon,* and *Swintonia*. The genera *Buchanania, Lannea, Parishia,* and *Spondias* include plants that may cause contact dermatitis, but specific documentation is lacking.[31]

Most of the allergenic Anacardiaceae of tropical Asia are trees in primary forests. The genus *Anacardium* is represented by *A occidentale* (cashew), which is widely planted in the Asian tropics. The genus *Gluta* includes about 30 species of trees and large shrubs and is a major cause of plant dermatitis in Southeast Asia.[31] *M indica*, mango, is only one of the 35 or so species of *Mangifera* distributed throughout Southeast Asia.[31] Although a perioral dermatitis following ingestion of mangos is the most common occurrence (see Figure 6-12), dermatitis has also resulted from the sap, bark, smoke from bonfires, and raindrops that have dripped off the leaves of the more toxic species of *Mangifera*. Members of the genus *Semecarpus* include 60 species distributed from India through Southeast Asia to Fiji.[31] *S anacardium*, the India marking nut tree discussed previously, is only one example. Many species of *Toxicodendron* are found in China, Japan, and Southeast Asia. Several of these are used commercially as a source of lacquer. *T verniciflua* is generally known

in English as the Chinese lacquer tree, in Japanese as *krushi*, and in Chinese as *qi su*.[31]

Australia

The flower of the kahili tree (*Grevillea banksii*, also found in Hawaii) can produce an ACD. An Australian stinging nettle, *Dendrocnide moroides*, produces piloerection, local vasodilation, sweating, and severe pain. Superficial lymphatics and proximal lymph nodes become tender.[28]

Other Allergic Contact Dermatitides

Although less likely than toxicodendrons to produce numerous battlefield casualties, many products in the soldier's environment may produce acute, chronic, or recurrent dermatitis resulting in inconvenience to the soldier or temporary loss of his or her services from the unit: *p*-phenylenediamine, nickel, rubber, ethylenediamine, potassium chromate, and many other chemicals are major sources of ACD. Often the pattern of dermatitis in these cases is not instantly recognizable as ACD, and, unless the correct diagnosis is considered, the soldier may suffer recurrent, preventable episodes of dermatitis requiring further evaluation and lost time from the unit. Reactions to each individual item may be relatively uncommon, but ACD after exposure to these agents as a group is very common.

Topical Drugs

Overtreatment with irritating and sensitizing drugs during World War II frequently caused more disability than the diseases that were being treated.[3,5] Tincture of iodine, Frazier's solution, topical penicillin, sulfonamide ointments, strong salicylic acid preparations, and Whitfield's ointment were frequently misused, resulting in increased casualties.[3,5] Ointments, pastes, and occlusives should be used with extreme care, particularly in warm tropical climates, because they may produce significant maceration. Frazier's solution, an antifungal agent supplied in jungle kits during World War II, was responsible for much overtreatment because of self-medication by soldiers.[3]

During World War II, topical use of penicillin resulted in frequent reports of allergic dermatitis. Since the banning of topical penicillin, neomycin has become the most sensitizing topical antibacterial preparation used.[9] Neomycin is particularly likely to result in sensitization when applied on stasis ulcers, in chronic otitis externa, and on chronic eczematous dermatitis. Intermittent use of the drug on minor cuts and wounds probably is not associated with an increased risk of sensitization. Neomycin has been included as a topical antibiotic in many ointments, creams, and lotions (Figure 6-18). It cross-reacts with gentamicin, kanamycin, spectinomycin, streptomycin, and tobramycin. Neomycin-sensitive patients who are given these antibiotics intravenously may develop a severe systemic eczematous contact-type dermatitis. The soldier shown in Figure 6-19 developed itching and redness on the lower leg near the edge of the boot but was negative on patch testing to samples from the boots. The eruption proved to be an allergic reaction to neomycin that the soldier had used as self-medication for a local irritation. Patch testing for neomycin was strongly positive.

Skin eruptions resulting from topical antibiotics are not limited to neomycin. Topical bacitracin, polymyxin, gentamicin, clindamycin, erythromycin, chloramphenicol, tetracycline, and nystatin are all causes of allergic dermatitis, though somewhat rare.

Whitfield's ointment contains 6% salicylic acid and 12% benzoic acid in petrolatum. It is a rare sensitizer, but the benzoic acid may produce a nonallergic contact urticaria, particularly when used in an intertriginous area. Antifungal agents such as tolnaftate, haloprogin, clotrimazole, miconazole, and econazole are very rare sensitizers but may cause an irritant dermatitis when used in intertriginous areas.

Benzocaine is a common and potent sensitizer found in hundreds of topical medications including

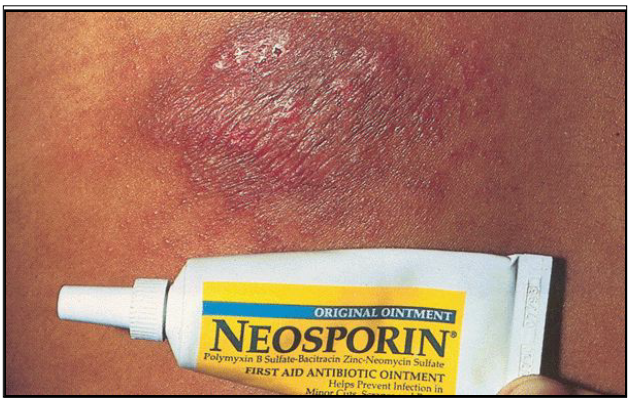

Fig. 6-18. Allergic contact dermatitis to neomycin. Neomycin is included in numerous topical antibiotic creams and is a common sensitizer.

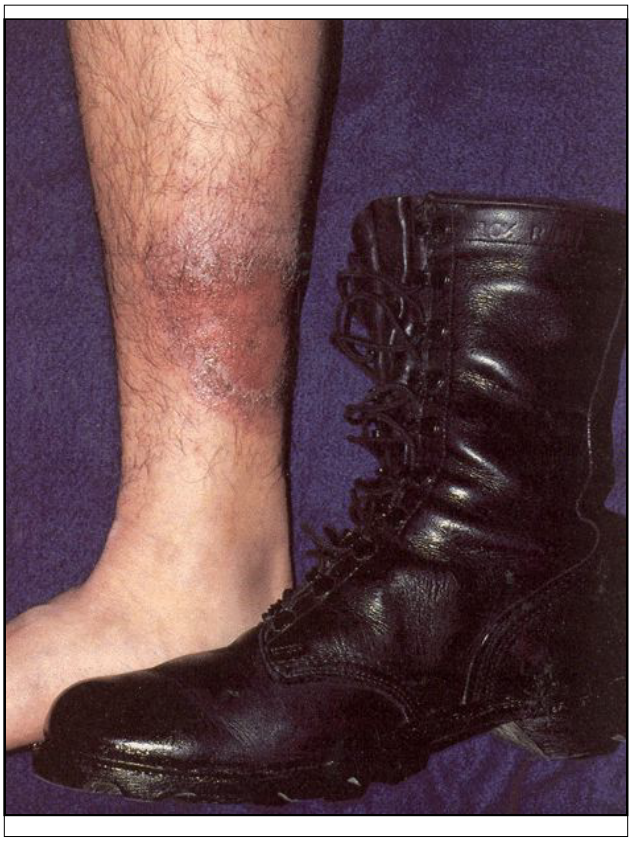

Fig. 6-19. Allergic contact dermatitis to neomycin. The soldier was initially felt to have an allergic reaction to material in his boots. That the soldier had been using an antibiotic cream containing neomycin was only discovered after negative testing of the boot material. Patch testing to neomycin was strongly positive.

Fig. 6-20. Allergic contact dermatitis to Lanacane (benzocaine). Benzocaine is an anesthetic in numerous topical preparations used to treat burns, bug bites, and abrasions.

burn remedies, athlete's foot therapies, topical analgesics, sore throat lozenges, astringents, wart remedies, and various antibacterial compounds (Figure 6-20). Eczematous, ulcerated, or burned skin is particularly likely to become sensitized to benzocaine. Because benzocaine cross-reacts with procaine, tetracaine, and cocaine, these should be avoided when treating the benzocaine-sensitive soldier. In addition, because benzocaine is a derivative of *p*-aminobenzoic acid (PABA), benzocaine-sensitive soldiers should avoid using sunscreens that contain PABA or glyceryl PABA (Figure 6-21). Benzocaine-sensitive soldiers can be safely treated with lidocaine, mepivacaine, prilocaine, pramoxine, and nupercaine. Amide anesthetics such as lidocaine, dibucaine and mepivacaine are very rare sensitizers. Methylparaben, a preservative found in some anesthetic solutions, is also a sensitizer.[9]

A variety of ingredients are added to topical agents including preservatives, stabilizers, antioxidants, and emulsifying agents. Ethylenediamine is a stabilizer in medicated creams. Mycolog cream

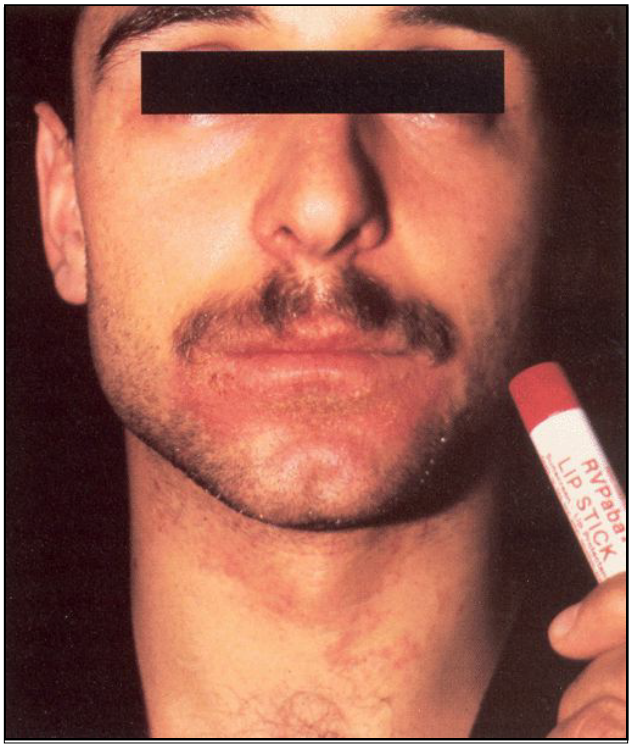

Fig. 6-21. Allergic contact dermatitis to PABA. *p*-Aminobenzoic acid (PABA) is an active ingredient in sunscreens and can produce allergic contact dermatitis in sensitized patients.

contained ethylenediamine and was a very common cause of sensitization until its replacement with Mycolog-II (nystatin and triamcinolone acetonide, manufactured by Westwood-Squibb, Buffalo, N.Y.), which lacks ethylenediamine, neomycin, or gramicidin (Figure 6-22). Ethylenediamine-sensitive soldiers should avoid aminophylline (which contains theophylline and ethylenediamine), hydroxyzine (Vistaril [manufactured by Pfizer, New York, N.Y.] or Atarax [manufactured by Roerig, New York, N.Y.]), and Vasocon-A eye drops (naphazoline hydrochloride and antazoline phosphate, manufactured by Cooper-Vision, Rochester, N.Y.).

Sunscreens

PABA, PABA esters, cinnamates, and benzophenones are used in sunscreens to block primarily ultraviolet B (UV-B) radiation. UV-B is that part of the sun's radiation that is most responsible for producing sunburns. The longer wavelength light, ultraviolet A (UV-A), can potentiate the effects of UV-B. The UV-A–blocking ingredient, dibenzoylmethane, is used in Photoplex (avobenzone and padimate O, manufactured by Allergan Herbert, Irvine, Calif.). Opaque sunscreens such as zinc oxide, titanium dioxide, kaolin, talc, and iron oxide reflect and scatter UV radiation. The opaque sunscreens and dibenzoylmethanes rarely produce ACD.[32]

PABA and its esters can produce an ACD, and PABA-sensitive soldiers may develop cross-reactions on exposure to *p*-phenylenediamine, procaine, sulfonamides, and azo dyes.[33] The patient shown in Figure 6-21 developed a severe perioral contact dermatitis from the PABA in RVPaba Lip Stick. Benzocaine is a PABA derivative and benzocaine-sensitive soldiers should be cautioned to avoid PABA or glyceryl sunscreens. PABA esters, digalloyl trioleate, or cinnamates also may produce an allergic photosensitization reaction.

Benzophenones used in sunscreens can produce ACD, immediate urticarial reactions, and photoallergic reactions.[34] Benzophenones are also widely used in textiles and plastics to provide colorfastness and protection from UV radiation.[9]

Metals

Metal dermatitis most frequently results after exposure to nickel, chromates, and mercury, but can also follow exposure to arsenic, gold, platinum, and other metallic compounds. With the exception of nickel, most pure metals do not cause ACD and must be in the form of a metallic salt in order to produce hypersensitivity. Positive patch test re-

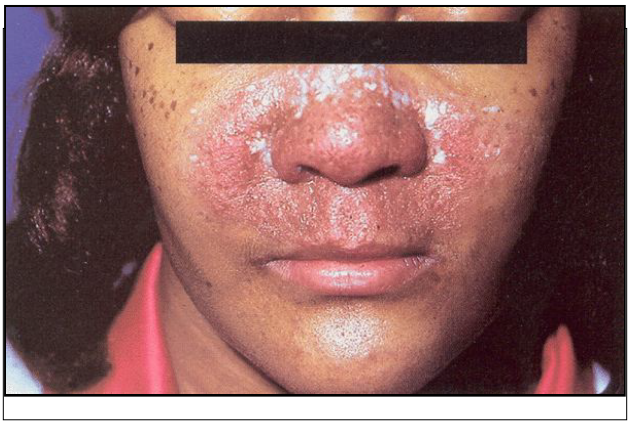

Fig. 6-22. Allergic contact dermatitis to Mycolog. Ethylenediamine is a very common sensitizer that was in Mycolog cream. It has been removed from Mycolog-II.

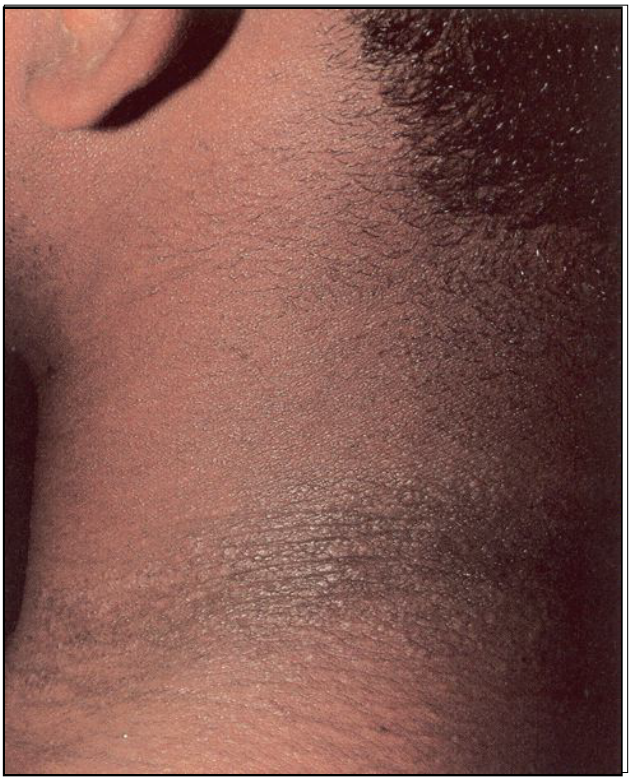

Fig. 6-23. Allergic contact dermatitis to nickel. Nickel in chains that are used to hold identification tags and jewelry can produce dermatitis in sensitized soldiers.

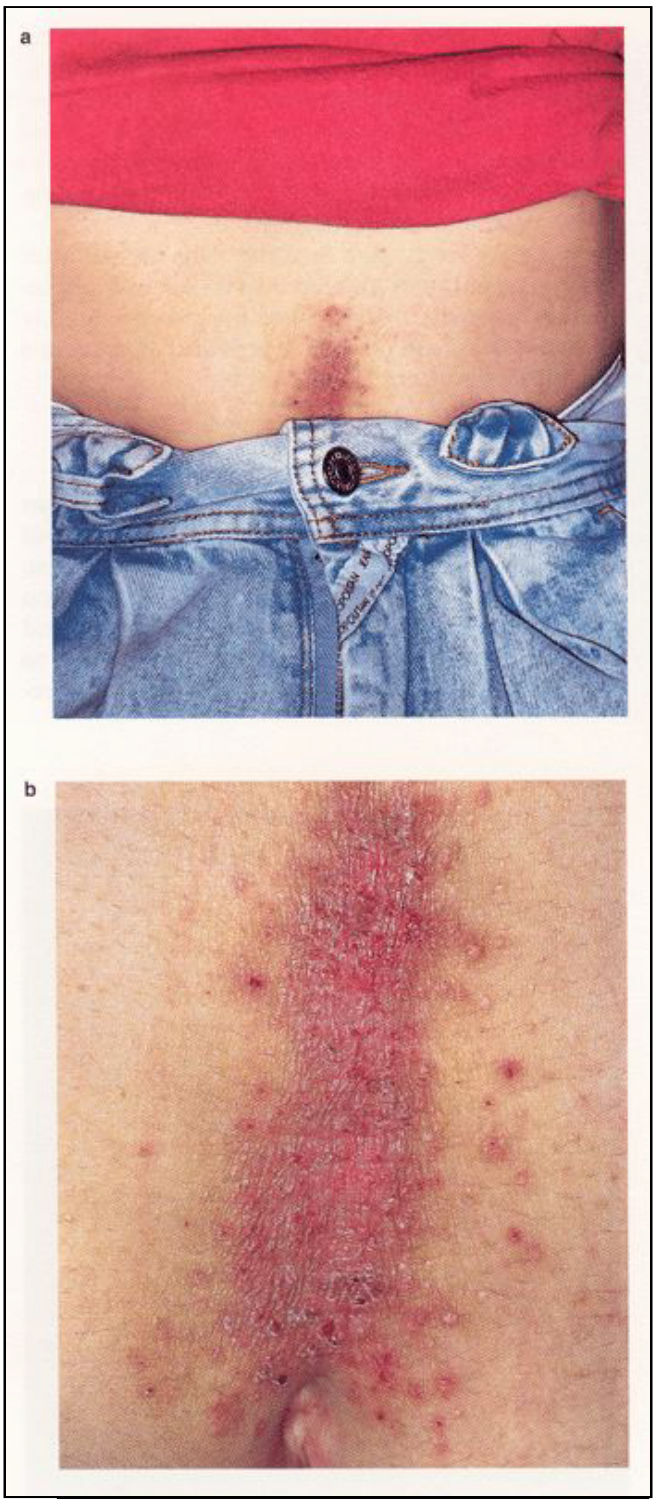

Fig. 6-24. (**a**) Nickel dermatitis from metal buttons in clothing. Allergic contact dermatitis from nickel may result from exposure to metal buttons, zippers, snaps, coins, etc. (**b**) Closer view of nickel dermatitis from metal buttons in clothing. Reprinted courtesy of D. Cuozzo, Dermatology Service, Walter Reed Army Medical Center, Washington, D.C.

Fig. 6-25. Nickel dermatitis from a watch band and ring. Gold- or silver-plated jewelry may produce dermatitis when the plate is worn away, exposing underlying nickel.

sults to a metallic salt do not usually indicate sensitivity to the pure metal. Allergic sensitivity to metals is usually highly specific, and cross-sensitivity with other metals is exceptional.

Nickel. Nickel-containing products are extremely common and cause more cases of ACD than all other metals combined. Nickel dermatitis has resulted from contact with hair pins, earrings, spectacle frames, metal identification tags[35] (Figure 6-23), chains, metal buttons in clothing (Figure 6-24), zippers, metal coins carried in pockets, watch bands, bracelets, metal arch supports, and nickel in bullets and shrapnel. The patient shown in Figure 6-25 developed nickel dermatitis under both his watch and ring.

Women are more commonly allergic to nickel than men. The most common cause of nickel dermatitis in women is contact with jewelry that contains nickel. Women who have their ears pierced with nickel-plated instruments very frequently become sensitized. Earlobe dermatitis is almost pathognomonic for nickel dermatitis (Figure 6-

Fig. 6-26. Nickel dermatitis of the earlobe. Earlobe dermatitis such as this is almost pathognomic for nickel sensitivity.

26).[36,37] Men tend to become sensitized to nickel more commonly through industrial exposures.

Perspiration containing sodium chloride can combine with nickel to form nickel chloride, resulting in a more severe dermatitis. Even extremely small quantities of the metal will produce dermatitis. Widespread nickel dermatitis may result when nickel contaminates perspiring fingers. Sweat, friction, and pressure will all increase the frequency of contamination and severity of the eruption. Prevention of sweating can decrease or prevent nickel dermatitis.

Patch testing for nickel is done with 5% nickel sulfate solution. The U.S. Indian head nickel can also be used in patch testing. Trace amounts of soluble nickel can be detected in suspected metal objects using the dimethylglyoxime (DMG) spot test. Two or three drops of 1% DMG and 10% ammonium hydroxide solution are placed on a white cotton-tipped applicator. This applicator tip is then rubbed against any objects that are suspected of containing soluble nickel. Appearance of a pink color on the applicator tip is a positive result (Figure 6-27). This technique can be used to test jewelry, buttons, keys, scissors, door knobs, or other metallic objects. A positive test is proof of the presence of nickel. Although this test is sensitive, a negative test result does not absolutely eliminate the possibility that nickel is present.[38–40]

Chromates. Chrome salts are used in the processing of leather goods and may cause an allergic dermatitis. Chromates are corrosive and irritating as well as sensitizing. In addition to leather goods, exposure to chrome salts can occur during contact with matches, paints, cement, diesel engines, and photographic processing solutions. Chromium metal and stainless steel (which contains chromium) do not cause allergic dermatitis. Apparent contact dermatitis related to these metals may be due to associated nickel. Patch testing for chrome is performed with 0.5% potassium dichromate.

Mercury. Mercury salts can cause irritant or allergic dermatitis. Phenylmercuric salts are used

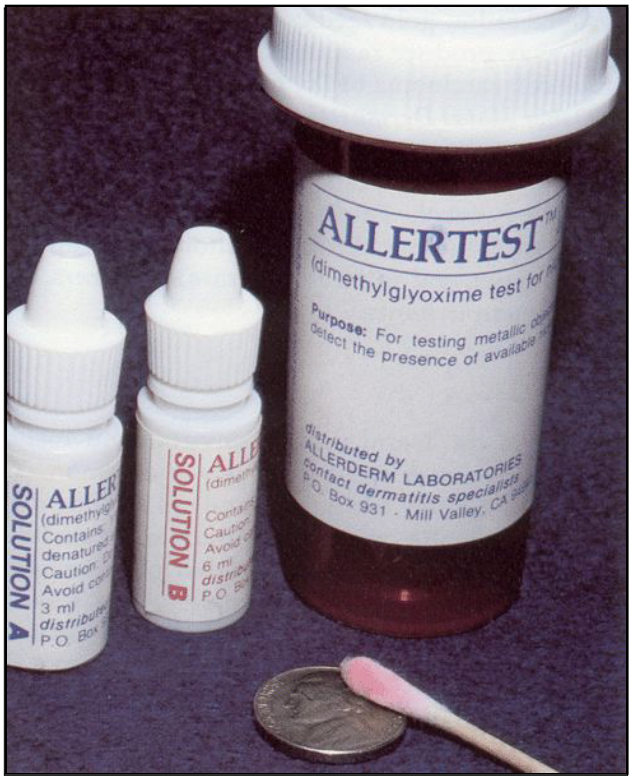

Fig. 6-27. Dimethylglyoxime (DMG) spot test showing a positive (pink) reaction for nickel. The test is performed by adding a few drops of each test solution to a cotton swab and rubbing the metallic object.

as weed killers, fungicides, and insecticides and may cause an allergic dermatitis on exposed skin. Mercuric compounds may also be found in cosmetic creams, suppositories, dental amalgams, and solder used in dry batteries. Merthiolate is an organic mercurial compound that can result in sensitization. Patch testing is done with 0.05% mercuric bichloride.

Arsenic. Arsenic is a sensitizer in dyes used in wallpaper, chalk, artificial flowers, and fabrics, and in some disinfectants and weed killers. Arsenic is also used in embalming, animal skin preservation (tanning), printing, farming, and gardening.

Gold. Gold dermatitis is uncommon, but may occur as a result of exposure to gold salts in jewelry. In cases where gold dermatitis is suspected, the article of jewelry should be tested with dimethylglyoxime to assure that nickel is not present. Patch testing for gold salt allergy is done with 1% gold chloride solution.

Many cases of gold dermatitis were reported in association with gold rings manufactured using gold contaminated with radon. The source of the contamination was apparently gold from reclaimed, decayed radon-gold seeds. The contaminated gold rings may produce radiation dermatitis and squamous cell carcinoma of the finger.[41]

Other Metal Dermatitides. Platinum dermatitis may occur after exposure to platinum salts. Platinum in jewelry causes a dermatitis similar to that caused by nickel. Patch testing can be performed with 1% platinum chloride solution. Zinc, aluminum, copper, and antimony are rare sensitizers, but are frequent irritants.

Shoes

Despite the warm, humid environment inside shoes, shoe dermatitis is relatively uncommon. To identify the likely allergens involved in shoe dermatitis, the healthcare provider must ascertain how the shoe is manufactured and what products and chemicals are used. Unfortunately, this task is frequently extremely difficult. Most shoes sold in the United States are now manufactured in part or wholly outside the United States. The combinations of glues, resins, fabric, rubber, dyes, metals, finishes, and leathers that may be combined in a modern shoe or boot make it impossible to identify every potential allergen. However, several specific agents are routinely used in patch testing when shoe dermatitis is suspected. These agents include antimildew agents (creosol, phenylmercuric nitrate, phenylphenol); nickel; dyes (aminoazobenzene, lanolin, *p*-phenylenediamine); leather tanning agents (formaldehyde, glutaraldehyde, potassium dichromate); neoprene and neoprene cements; polyurethanes and polyurethane cements; and rubber and rubber cements (carba mix, thiuram mix, colophony, mercapto mix, mercaptobenzothiazole, and isopropyl-*p*-phenylenediamine [IPPD]).[42,43]

ACD caused by leather is usually related to tanning agents and dyes. Most cases are associated with chrome used in the tanning process.[44,45] ACD rarely results from formaldehyde and glutaraldehyde used as leather tanning agents or by leather dyes. Scutt[46] reported an epidemic of 86 cases of leather shoe dermatitis in sailors of the British Royal Navy assigned to the Far East. The dermatitis was caused by chromates in leather sandals that were worn in direct contact with the skin. A severe, debilitating dermatitis resulted. Contact dermatitis to trivalent chrome salts used in tanning is detected by patch testing with 0.5% potassium dichromate.

Although synthetic materials are replacing rubber in many shoes, rubber allergy is still the most common cause of shoe contact dermatitis in the United States. The rubber accelerators mercaptobenzothiazole and tetramethylthiuram disulfide are the most common allergens found in rubber shoe dermatitis. IPPD is a rubber antioxidant and is a less common cause of contact dermatitis, but it has been shown to produce a purpuric shoe dermatitis.

Patch testing can be done using pieces of the shoe soaked in water and applied under occlusion to the medial forearm or back for 48 hours. Depending on the location of the allergen in the shoe, dermatitis can involve the dorsal or plantar surface (Figure 6-28). The instep, toe webs, and flexural crease areas of the

Fig. 6-28. Allergic contact dermatitis to shoes. Allergic shoe dermatitis may result from exposure to glues, resins, fabric, rubber, dyes, metals, finishes, or leather.

toes are usually spared. Involvement of these areas should suggest the possibility of a secondary bacterial infection or tinea pedis. The differential diagnosis also should include a mechanical irritant dermatitis, dyshidrosis, pustular psoriasis, lichen planus, and epidermolysis bullosa simplex.

Rubber Compounds

One potentially very significant allergen in the military is the rubber liner in the standard-issue gas mask. The soldier whose arm is shown in Figure 6-29 gave a history of burning, pruritus, and erythema shortly after putting on her gas mask. A small sample of the black rubber liner was taped to her forearm. Within 2 hours she noted significant pruritus and within 24 hours she developed the erythema and vesiculation characteristic of ACD. The patient in Figure 6-30 developed a similar response from exposure to rubber chemical-protective gloves.

Soldiers may show either an acute contact urticaria or a delayed-type hypersensitivity reaction in response to rubber. Most reactions to rubber represent a delayed hypersensitivity reaction. With only rare exceptions, reactions to rubber are due not to the rubber itself, but to the chemicals added in the manufacturing process. Antioxidants and accelerators used in the manufacturing process cause most of the ACD associated with processed rubber. Antioxidants are added to help preserve the rubber; *p*-phenylenediamine is a common antioxidant and sensitizer. Vulcanization or curing of raw rubber results in cross-linking of polymer chains and is the process that gives rubber its elasticity. This process is hastened with accelerators such as disulfiram, thiuram, mercaptobenzothiazole, and diphenylguanidine. ACD may result from exposure to rubber in gloves, gas masks, condoms, tires, heavy-duty rubber goods, boats, and undergarments.

Patch testing is usually done using rubber chemical "mixes" rather than single ingredients. For soldiers with a proven allergic reaction to the rubber in gas masks, M4D silicon masks may be obtained from the U.S. Army Medical Research Institute for Chemical Defense (ICD), Aberdeen Proving Grounds, Aberdeen, Maryland 21010-5425.

Clothing

Natural and synthetic fabrics used in the manufacture of clothing seldom result in dermatitis. When dermatitis does result, it is usually in response to products added to the fabric, with the most common culprits being dyes, rubber compounds,

Fig. 6-29. Allergic contact dermatitis from the black rubber liner of a standard issue military gas mask. An M4D silicon gas mask should be obtained for soldiers with a documented allergic reaction to the standard issue gas mask.

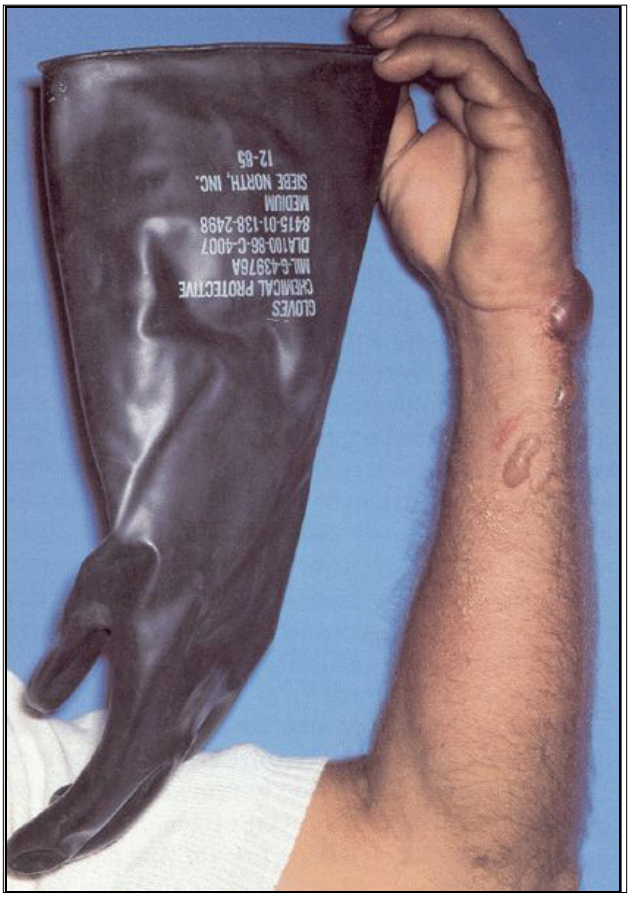

Fig. 6-30. Allergic contact dermatitis from a rubber chemical protective glove. Symptoms of allergic contact dermatitis developed a few hours after exposure. Reprinted courtesy of C. Samlaska, Dermatology Service, Tripler Army Medical Center, Honolulu, Hawaii

chromates, nickel, glues, permanent-press finishes (formaldehyde resins), or sizing.

Dermatitis from additives to the fabric of pants most commonly results in an eruption on the inner and anterior thighs or popliteal fossa. An eruption in the axillary folds and antecubital fossa can be caused by shirts or dresses. A local eruption may occur on the midabdomen from exposure to nickel in belt buckles.

Allergic dermatitis to natural wool is uncommon; however, irritant dermatitis, especially in atopic soldiers, commonly occurs at body sites where the wool is in contact with the skin. Woolen khaki shirts worn by soldiers in World War II were noted to cause an occasional purpuric eruption that probably resulted from exposure to lubricating oils used in the manufacture of the fabric.[47] Chrome also causes an allergic dermatitis when used in the dying process of green woolen military textiles.[48] Dermatitis caused by untreated man-made fibers such as nylon, dacron, orlon, and rayon is rare.

Pure spandex fibers are used as a rubber substitute in many undergarments because spandex is lighter in color and weight. It is an excellent substitute for soldiers who are allergic to rubber. The antioxidants and accelerators that cause most of the dermatitis from rubber are not used in the manufacture of spandex.

Many textile additives such as softeners, water repellents, biocides, antistatic agents, lubricants, moth proofers, and antislip finishes are not sensitizers. However, formaldehyde and formaldehyde resins used to make permanent-press finishes may cause allergic contact reactions. Dermatitis as a result of residual detergents after washing of clothes is uncommon[49] but can be related to perfumes in the detergents. Textile dyes may cause an ACD. Forty percent of textile dyes are azo dyes. Azo dyes are among the most common causes of textile dye dermatitis and may cross-react with *p*-phenylaminediamine. Regardless, ACD resulting from exposure to dyes is rare.[49]

Skin eruptions may also result from occlusive, tightly fitting garments. Pressure urticaria, acneform eruptions, and exacerbation of preexisting eczematous skin conditions may result from clothing that fits too snugly. Patch testing for clothing dermatitis can be performed using a 1-in. square of fabric soaked in water for 10 minutes and applied under a closed patch on an uninvolved medial forearm or the back for 3 days.

Blousing garter dermatitis is a syndrome of hyperpigmentation of the ankles and feet below the level of application of elastic garters used to keep fatigues neatly in place. Chronic pressure of this kind may result in mild edema and a subsequent form of stasis dermatitis with the associated deposition of melanin and hemosiderin. This condition is not a contact dermatitis.

Preservatives

Quaternium-15 is a common preservative in cosmetics and creams and is a common cause of allergic dermatitis (Figure 6-31). Imidazolidinyl urea is a very common preservative used in cosmetics but is a less common sensitizer. Bronopol is another sensitizer but is a less commonly used preservative. Formaldehyde is a preservative used in shampoos, cosmetics, and many paper products. It is a significant sensitizer. Although sensitization after use of a formaldehyde-containing shampoo is uncommon, sensitized soldiers may develop an eruption after

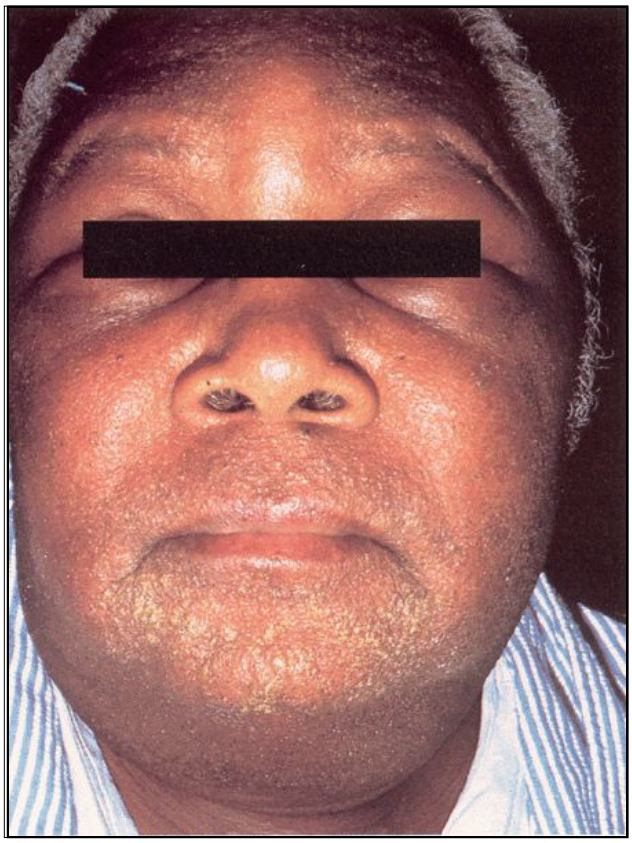

Fig. 6-31. Allergic contact dermatitis from quaternium-15 in a moisturizing cream. Quaternium-15 is a common preservative in cosmetics and creams. Severe edema and pruritus developed a few hours after a single exposure.

contact with newspaper, magazines, books, paper towels, tissues, or photographic paper.[50]

Paraben esters (methyl, ethyl, propyl, and bretyl *p*-hydroxybenzoates) are used in combinations as preservatives in some cosmetics, foods, drugs, and suppositories. Paraben sensitization is evaluated using a 12% paraben mix in petrolatum.

Fragrances

Fragrances, or perfumes, are the leading cause of ACD due to cosmetics (Figure 6-32).[51] Besides being found in cosmetics, they are used in detergents, toothpastes, sanitary pads, fabric softeners, and many other products. In addition to allergic reactions, fragrances may produce photodermatitis (sun-related), contact urticaria, primary irritation, or depigmentation. Some of the more common offenders are cinnamic alcohol and aldehyde, hydroxycitronella, eugenol, and isoeugenol. Other fragrances that can cause dermatitis include coriander, geraniol, heliotropine, hydroxycitronella, jasmine, linalool, lavender, lemon, lemon grass, neroli, origanum, oil of cloves, peppermint, spearmint, and wintergreen.

Fig. 6-32. Perfume dermatitis. Fragrances, or perfumes, are the leading cause of allergic contact dermatitis due to cosmetics and may be ingredients in many other products.

Other Sensitizers

p-Phenylenediamine is a common sensitizer used in hair dyes, photographic processing, and rubber vulcanization. *p*-Chloro-*m*-xylenol is a chlorinated phenol antiseptic sensitizer used in Absorbine Jr. (wormwood, thymol, and chloroxylenol, manufactured by W.F. Young, Springfield, Mass.), Desitin powder (talc, manufactured by Leeming/Pacquin, New York, N.Y.), and Unguentine spray (benzocaine, manufactured by Mentholatum Co., Buffalo, N.J.). Propylene glycol is widely used as a vehicle for cosmetics, emollient lotions, and topical medications. It is also used in brake fluids, automotive antifreeze, lubricants for food machinery; in additives for food colors; and in antiperspirants. Propylene glycol is both an irritant and a sensitizer.

Lanolin (wool fat, wool wax, wool alcohol) and related compounds are found in many topical medications. Lanolin is a common sensitizer found in creams, hair products, lipsticks, moisturizers, ointments, soaps, furniture polishes, leather, shoe polishes, fur, and textile finishes. Lanolin is a significant cause of allergic dermatitis when it contacts eczematous skin. The risk of sensitization when contact is with normal skin is much lower.

Balsam of Peru is used widely in topical therapies. It has mild antibacterial activity and is used in toothpastes, sore throat lozenges, and dental cements. It may also be found in sunscreens, cosmetics, perfumes, and a variety of suppositories. Cross-reactions can occur with benzoin, rosin, benzyl alcohol, cinnamic acid, orange peels, clove, benzyl benzoate, and wood tars. Balsam of Peru is a well-documented sensitizer and also produces a nonallergic contact urticaria.[9]

Rosin (colophony) is a natural resin used widely in topical medications, adhesives, cements, and cleaners. It is used on violin bows and in rosin bags for baseball players. Rosin is a sensitizer, and sensitized soldiers may cross-react with Balsam of Peru. Thiuram is a common sensitizer in rubber products but may also be found in adhesives, fungicides, disinfectants, paints, pesticides, soaps, repellents, and putty.

IRRITANT CONTACT DERMATITIS

Many substances produce a nonallergic inflammatory reaction of the skin. Any soldier exposed to sufficiently high concentrations of the substance will develop dermatitis. No prior exposure is required, and the effect is evident within minutes or a few hours. Variations in severity of the reaction to these irritants—from soldier to soldier or from time to time in the same soldier—are due to the condition of the skin and the duration of exposure to a given concentration of irritant. Excessive humidity, heat,

cold, pressure, or friction may adversely affect the epidermal barrier, making the skin more vulnerable to the irritant effects of a substance. Cold weather and low humidity may produce chapping, excessive dryness, and pruritic skin and predispose to irritant dermatitis. High temperatures and humidity in the summer predispose to maceration and increased frequency of irritant dermatitis. Thick skin of the palms and soles is more resistant to irritants than thin skin. Repeated exposure of the skin to some mild irritants may, in time, produce a "hardening" effect, which makes the skin more resistant to an irritant.

Alkalis and Acids

Alkalis are composed primarily of sodium hydroxide, potassium hydroxide, ammonium hydroxide, and calcium hydroxide compounds; they penetrate deeply and destroy the skin because they dissolve keratin. These agents are frequently associated with hand eczemas after exposure to soaps; detergents; bleaches; ammonia preparations; lye; and drain pipe, toilet bowl, and oven cleaners. Exposure to concentrated alkalis may be buffered by rinsing the site with a weak acid solution such as vinegar, lemon juice, or 0.5% hydrochloric acid.

Exposure to acids (eg, hydrochloric, nitric, sulfuric, and hydrofluoric) causes an irritant burn. Hydrochloric acid produces more superficial damage than the others and more frequently results in blister formation. Nitric acid, which is used in the production of some explosives, causes deep burns while turning the skin yellow. Sulfuric acid is used extensively in industry and results in a brownish charring of the skin, which ulcerates and heals slowly. Hydrofluoric acid is a very potent inorganic acid that will dissolve glass, but may be slow to cause dermatitis. If left in contact with the skin, progression from erythema to vesiculation, ulceration, and finally necrosis occurs.

Acid burns should be treated by rinsing with copious amounts of water. Alkalization of the site can be done with sodium bicarbonate, calcium hydroxide (lime water), or soap solutions.

Hydrocarbons

Hydrocarbons in crude petroleum and lubricating and cutting oils may cause an irritant dermatitis. Chronic exposure can also result in pruritus, folliculitis, calcifications, or acneform eruptions. Exposure to creosote, asphalt, and other tar products may result in melanoderma. Creosote is a contact irritant, sensitizer, and photosensitizer.

Diethyltoluamide Dermatitis

Insect repellents containing diethyltoluamide (DEET) were first extensively used in a military conflict during the Vietnam conflict. Although it was not suspected of being capable of causing significant skin reactions, during the Vietnam conflict DEET was discovered to result in a bullous eruption in some personnel. Although this chemical was a relatively uncommon cause of significant dermatitis, it did result in pain, disability, and permanent scarring in some individuals.[8,52,53]

DEET eruptions were characterized by a distinctive clinical course and by their restriction to the antecubital fossae. The eruption was first noted by soldiers on morning awakening. A red, tender area in one or both antecubital fossae was noted. This area would evolve over 24 hours into blisters on a tender base. Lamberg and Mulrennan[53] showed in 1969 that about half the people tested will develop a reaction to DEET when it is applied to the antecubital fossa, but none of the 62 patients tested reacted to DEET applied to the upper inner arm. Besides proving that the eruption was an irritant reaction, not an allergic one, Lamberg and Mulrennan pointed out that when DEET is used in the antecubital fossae, a large percentage of the populace will be at risk for this eruption. Besides being capable of producing an irritant dermatitis, DEET produces contact urticaria in some individuals.[52]

Chloracne

Chloracne was first described by Herxheimer in 1899 as a form of acne that is distinct from all other forms of acne, such as acne vulgaris and acne rosacea.[54] Chloracne may result from exposure to a variety of aromatic chlorinated hydrocarbons.

During the Vietnam conflict, Agent Orange was by far the most commonly used defoliant. The herbicide is composed primarily of a mixture of 2,4,5-trichlorophenoxyacetic acid (2,4,5-T) and 2,4-dichlorophenoxyacetic acid (2,4-D). These two products are potentially toxic, but a contaminant, 2,3,7,8-tetrachlorodibenzo-*p*-dioxin (TCDD), poses more significant health concerns. In addition to the many other health concerns associated with it, TCDD is a known chloracne-producing agent.

The distribution of lesions in soldiers with chloracne is of particular diagnostic importance.

The most frequently involved areas are on the face, below and lateral to the eyes, and behind the ears. These areas may be the only sites involved, and chloracne in these areas may persist for years after lesions in other parts of the body have resolved. The scrotum is also a particularly sensitive area. If the exposure is sufficient, lesions also may appear on the penis, shoulders, chest, back, and eventually, the buttocks and abdomen. The nose is uniformly spared and the distal extremities are seldom involved.

The primary lesion of chloracne is the comedo. With mild exposure, small numbers of comedones on the face may be all that is noted. With more severe exposure, soldiers also develop pale yellow cysts 1 to 10 mm in diameter that are mingled with the comedones. Soldiers may develop large inflammatory cysts and cold abscesses with very severe exposures, but even these cysts tend to be much less inflammatory than those seen in cystic acne.

The clinical course of chloracne varies depending on the method of exposure, chemical involved, and dose. Simple comedones usually do not develop until 2 to 4 weeks after exposure. After exposure ceases, most persons will clear all lesions within 4 to 6 months. However, some patients have shown chloracne lesions for 15 to 30 years after the last known exposure.[54]

Chloracne may be relatively unresponsive to therapy. Topical 0.05% Retin-A (tretinoin, manufactured by Ortho Pharmaceutical Corp., Raritan, N.J.) may be effective with comedonal lesions, and oral retinoids may be tried in more severe cases.[54]

Irritant Contact Dermatitis due to Plants

Numerous common plants and even edible fruits can cause an irritant contact dermatitis. The dermatitis frequently occurs only after exposure to a particular part of the plant, and the degree of toxicity may vary with the season, type of exposure, stage of maturity of the plant, locality, and anatomical factors such as thickness of the stratum corneum.

The majority of cases of irritant contact dermatitis can be traced to only a few plant families. The largest is the spurge family (Euphorbiaceae). Spurges such as the poinsettia (*Euphoria pulcherrima*), crown-of-thorns (*E splendens*), candelabra cactus (*E lactea*), and pencil tree (*E tirucalli*) contain a highly irritating, white, milky sap that may cause erythema, desquamation, and bulla formation. The active agent in the sap is known as euphorbin.[14] Another family of irritant plants, Brassicaceae, includes the mustard seed plant and butter cups. Calcium oxalate, another irritant, is found in a number of plants including *Dieffenbachia*, daffodils, hyacinths, and pineapples.

Many of these plants produce dermatitis only after chronic exposure and symptoms frequently consist only of erythema, burning, or pruritus. On rare occasions severe bullous eruptions occur, or oral exposure may result in oral or esophageal lesions.

OTHER CONTACT DERMATITIDES

Certain skin disorders are not typically classified as either ACD or irritant contact dermatitis. These dermatitides include mechanical injury, pharmacological reactions, and contact urticaria.

Mechanical Injury

Aside from the obvious risks of a combat environment, the soldier may be exposed to a variety of natural agents that can result in direct trauma to the skin. Traumatic injury from plants is a frequent cause of dermatitis, but seldom requires the care of a medical officer. Secondary bacterial and fungal infections around implanted thorns, needles, splinters or spines are not uncommon, even though these injuries are frequently sterile. *Sporothrix schenckii* (a dimorphic, imperfect fungus) infection should be considered following wounds produced by roses, trees, grasses, and sphagnum moss (Figure 6-33).[55] Cactus needles that remain imbedded in the skin may produce aseptic foreign-body granulomas. Coral cuts produced by the exoskeleton of the corals, order Milleporina, have a largely undeserved reputation for producing inflammatory lesions that heal slowly. This reputation is probably related chiefly to the injuries' location—most frequently on the feet—and the occasional implantation of small coral fragments. In general, coral cuts should be treated with vigorous cleansing as soon after the injury as is feasible.

Pharmacological Reactions

On contact with the skin, some plants cause dermatitis through the release of pharmacologically active agents. Essentially all persons will develop a

Fig. 6-33. *Sporothrix schenckii* infection. Infection can follow wounds produced by roses, trees, grasses, and sphagnum moss.

reaction to significant exposure. Most of these reactions are produced by plants in the family Urticuceae. Stinging nettles (*Urtica ureus*), common in dry, disturbed soil or woodland margins, are characterized by sawtoothed, heart-shaped leaves and are densely covered with coarse, stinging hairs. The hairs consist of a tiny capillary tube that breaks off at a predetermined line on contact with the skin. Pressure on a small bladderlike base injects fluid containing histamine, acetylcholine, and serotonin. The result is a typical triple response (erythema, flare, and wheal) with pruritus noted in seconds and lasting a few hours. Most stings are benign and require little or no therapy.[14]

Contact Urticaria

Contact urticaria may be defined as a wheal-and-flare reaction that occurs after topical exposure to an agent. It may be immunological, nonimmunological, or of unknown mechanism. The immunological type may be severe, with associated anaphylaxis. Nonimmunological contact urticaria is the most common and is caused by agents that directly stimulate the release of vasoactive substances from mast cells.

Agents that produce allergic contact urticaria include silk, wool, rubber, animal hair, dander, saliva, serum, seminal fluid, cockroaches, moths, insect stings, milk, eggs, fish, meat, fruits, potatoes, phenylmercuric propionate (as an antibacterial agent in the laundry), beer, penicillin, neomycin, nickel, formaldehyde, and rubber.

Contact urticaria from rubber occurs almost exclusively from the use of rubber gloves. Dentists, surgeons, operating room nurses, and numerous other healthcare providers may demonstrate a contact urticaria reaction to rubber gloves. The sensitization rate may be up to 10% in highly exposed personnel.[56]

Allergies to latex pose a risk to both the healthcare provider and his or her patients. Severe anaphylactic reactions have occurred in patients exposed to latex during surgery, obstetrical deliveries, and barium enemas. It is therefore recommended that before performing these procedures the history include questions regarding signs and symptoms of latex allergy. This point is of particular importance when the patient is a healthcare provider. Most of the patients who have developed intraoperative reactions to latex have been healthcare providers.[56] Many items in the operating room may be the source of latex. Sensitive individuals may react to latex in gloves, endotracheal tubes, syringes, intravenous tubing and bags, multidose vials, and enema and catheter tubing.

Agents that produce a nonimmunological contact urticaria include jellyfish, the Portuguese man-of-war, Balsam of Peru, caterpillar hair, moths, insect stings, benzoic acid, nettles (plants), dimethyl sulfoxide, cobalt chloride, trafuril, sorbic acid, and cinnamic acid.

Skin testing for contact urticaria is performed as an open patch test, and the suspected agent should initially be applied to previously uninvolved skin. If no reaction occurs, the agent can be placed on previously affected skin. If there is still no reaction, the agent may then be gently rubbed into a superficial scratch. Immediate contact urticarial reactions should be read at 20 minutes after application. Because anaphylaxis may result from such testing in highly allergic individuals, epinephrine and resuscitation equipment should always be available.

CONTACT DERMATITIS BY ANATOMICAL SITE

Many areas of the body are particularly sensitive to contact allergens, and some areas are affected most commonly by a few specific allergens. From a practical standpoint, it is important to be aware of these associations. Some material from earlier in the chapter is repeated here in order to assist the medical officer in rapid diagnosis and treatment.

Eyelids

The eyelid is one of the most sensitive and frequently affected parts of the body (Figure 6-34). Any allergen that contacts the face, scalp, or hands may be inadvertently transferred to the lids, resulting in an eczematous dermatitis even when the primary sites remain clinically uninvolved. Eyelid dermatitis occurs most commonly from products applied to other parts of the body and then accidentally transferred to the lids. Frequently only one eyelid is involved. Severe edema of the eyelids is frequently associated with exposure to *T rydbergii* and *T radicans* (poison ivy). Preservatives in ophthalmic medications and contact lens solutions can produce eyelid dermatitis and conjunctivitis. The most common preservatives implicated include benzalkonium chloride, thimerosal, chlorobutanol, chlorhexidine, and phenylmercuric nitrate and acetate. Cosmetics such as mascara and eye shadow, lemon and orange peels, and exposure to phosphorous sesquisulfide in "strike anywhere" matches can cause eyelid dermatitis.[57] Airborne contactants such as insecticides and volatile occupational chemicals can also produce a dermatitis of the lids.

Face

Contact dermatitis involving the face may result from direct contact or from inadvertent transfer of an allergen. In addition, sun- and plant-related dermatitis are often most severe on the face. Facial dermatitis due to rubber compounds may be of particular importance to military personnel. A severe eruption may occur after exposure to rubber used in gas masks (see Figure 6-29). Although the scalp is resistant to contact dermatitis, the forehead, ears, and posterior neck may become inflamed after contact with hair dye, hair spray, shampoo, and permanent-wave solutions. Dermatitis of the forehead may result from contact with leather or rubber compounds in hat bands or protective helmets. The forehead may also be affected after exposure to pomade hair straighteners. Pomade acne occurs primarily in black males and consists of closely packed, multiple, closed comedones along the hairline and temples (Figure 6-35). Perioral dermatitis may result from reactions to toothpaste or chewing gum. Earlobe dermatitis most commonly results from nickel found in earrings (see Figure 6-26). Severe contact dermatitis of the face may result after exposure to smoke from burning toxicodendrons (poison ivy). Other causes

Fig. 6-34. Allergic eyelid dermatitis. Eyelids are frequently sites of contact dermatitis. Allergens may be inadvertently transferred to the lids from the face, scalp, or hands.

Fig. 6-35. Pomade acne. Pomade hair straighteners can produce an acneform eruption along the hairline and temples.

Fig. 6-36. Contact dermatitis produced by deodorant. Irritant reactions to aluminum salts can occur. Allergic reactions are most frequently due to fragrances.

of facial dermatitis include cosmetics, sunscreens, acne medications, aftershave lotion, and moisturizing creams.

Neck

Nickel found in metal identification tags and chains and in necklaces may result in an underlying erythematous and eczematous eruption of the neck (see Figure 6-23). The dermatitis may occur just under the clasp of a necklace or just under the identification tag. An eruption in this area might also result from contact with rubber used to insulate or quiet the identification tag and chain. Dermatitis of the neck may result from airborne allergens, perfume, and aftershave lotion (see Figure 6-32).

Trunk

The trunk is infrequently afflicted with contact dermatitis. Metal identification tags and related covering materials may result in a dermatitis of the central chest. Dye or finish in clothing may occasionally result in a dermatitis of the chest or axilla. Dermatitis of the axillary vault is seen in reactions to deodorants (Figure 6-36). Elastic materials or metal wires and snaps found in brassieres may result in a contact dermatitis. Other sensitizers can include topical medications or sunscreens.

Abdomen

Dermatitis of the belt line may result from elastic material in undergarments. The central abdomen may develop a dermatitis under nickel-containing zippers, buttons, snaps, and belt buckles (see Figure 6-24).

Groin

The penis or scrotum may become inadvertently exposed to poison ivy oleoresins on the hands, resulting in severe contact dermatitis (see Figure 6-6). The patient in Figure 6-37 developed a severe contact dermatitis after using spray deodorant in his genital area. Penile dermatitis may also result from condoms. The allergen in these cases is usually a rubber antioxidant or accelerator.

Fig. 6-37. Contact dermatitis from using spray deodorant. Dermatitis of the scrotum or groin area can result from inadvertent transfer or inappropriate application of irritants or allergens.

Fig. 6-38. Allergic contact dermatitis from hand cream. Hand dermatitis can result from exposure to foods, toxicodendrons, oils, solvents, metals, topical medications, rubber gloves, soaps, or detergents.

Hands and Feet

Contact dermatitis of the feet most commonly results from leather, rubber, or adhesive materials used in shoes and boots (see Figure 6-28). Hand dermatitis may result from exposure to foods, toxicodendrons, oils, solvents, metals, topical medications, rubber gloves, soaps, or detergents (Figure 6-38).

PATCH AND USE TESTING

Although an extensive discussion of patch testing is beyond the scope of this text, Table 6-1 shows a list of agents frequently used in the process. Physicians experienced in performing patch tests frequently maintain their own stock of additional agents that can be used in patch testing. In addition, small samples of each of the ingredients in a product may be obtained from the manufacturer. Only standardized concentrations of each allergen should be applied. In no case should undiluted, nonstandardized mixes of chemicals be applied under occlusion.

Patch testing of solid objects may be performed by trimming off a small (0.5–1.0 cm^2) sample and applying it to the skin, or if small enough, the object in question may be taped to the skin. Small pieces of shoes or clothing can be moistened and applied under occlusive hypoallergenic tape. Suspect agents are usually left against the skin for 48 hours. The agent is removed and the site is examined; the exam is repeated 48 hours later. A significant allergen will produce pruritus, erythema, edema, and even vesiculation at the site.

TABLE 6-1

STANDARD PATCH-TEST SCREENING TRAY

Allergen	Common Sources of Exposure
Balsam of Peru 25%	Cosmetics, perfumes
Benzocaine 5%	Topical anesthetics, medications
Black rubber mix 0.6%	Rubber products
p-Tert-butylphenol formaldehyde resin 1%	Adhesives, rubber products
Carba mix 3%	Rubber cements and sealants
Cinnamic aldehyde 1%	Fragrance, flavorings
Colophony (rosin) 20%	Adhesives, cements, cleaners, topical medications
Epoxy resin 1%	Glue, pastes
Ethylenediamine dihydrochloride 1%	Mycolog, aminophylline, hydroxyzine, eye drops
Formaldehyde 1%	Glues, paper, clothing, cosmetics, leather
Imidazolidinyl urea 2%	Preservative in creams and cosmetics
Lanolin (wool) alcohol 30%	Cosmetics, medicated creams, leather, polishes, fur
Mercapto mix 1%	Shoes, rubber products
Mercaptobenzothiazole 1%	Rubber products
Neomycin sulfate 20%	Topical medications
Nickel sulfate 2.5%	Jewelry, metal fasteners, ID tags/chains, tools
p-Phenylenediamine 1%	Hair dyes, inks, rubber products
Potassium dichromate 0.25%	Cement, leather, green woolen military textiles
Quaternium-15, 2%	Cosmetics
Thimerosal 0.1%	Eye, ear, and nose preparations
Thiuram mix 1%	Rubber products

Data source: Fisher AF. *Contact Dermatitis*. Philadelphia, Pa: Lea & Febiger; 1986: 21–28.

Use testing may be performed with nonirritating creams, ointments, oils, and sprays that are believed to contain possible allergens by applying the material to the inner surface of the distal upper arm three times a day for 1 week. If no reaction occurs, the test is considered negative, but false-negative results are not uncommon with this form of testing.

TREATMENT

As with most medical conditions, making the correct diagnosis is crucial to providing appropriate therapy. The diagnosis of poison ivy dermatitis may be obvious in the soldier who presents with a linear bullous dermatitis on exposed skin. However, contact dermatitis may be neglected for several days, and a secondary infection may cloud the clinical picture. The medical officer must be alert to this possibility and attempt to come to the correct diagnosis with a thorough history and insightful physical examination. Once the correct diagnosis has been established, many affected soldiers' conditions will improve with adequate hygiene and avoidance of the primary contactant. Depending on the degree and duration of involvement, and the presence or absence of secondary infection, each of the following therapies may be considered.

Removal of the Irritant

In cases of acute irritant dermatitis from strong irritating chemicals, the first goal must be to remove the irritant from the skin to prevent further damage. Oral and topical steroid therapy do not benefit the soldier who has a nonallergic, irritant contact dermatitis.

Acid burns from such agents as hydrochloric, nitric, and sulfuric acids should be treated immediately with copious amounts of water and alkalization with sodium bicarbonate or soap solutions. Alkalis such as soaps, detergents, bleaches, ammonia preparations, lye, and drain pipe, toilet bowl, and oven cleaners all can cause significant irritant contact dermatitis. Alkalis may cause deep tissue destruction because they dissolve keratin. Strong alkaline solutions may be neutralized by rinsing the skin with a weak acid solution such as vinegar, lemon juice, or 0.5% hydrochloric acid. The site should also be rinsed with large quantities of water.

Nonsteroidal Therapy

Many cases of localized, mild contact dermatitis will respond well to cool compresses and adequate wound care. Cool, wet soaks applied for 5 to 10 minutes followed by air drying may significantly reduce serous drainage from the site. Clean water, isotonic saline, and Burow's solution can all be used with good success. Topical calamine lotion usually is of limited benefit.

Affected sites should be cleared of adherent crusts and a thin coat of antibacterial ointment should be applied. Most episodes of contact dermatitis will not require antibiotic therapy, if they are treated promptly and adequate wound care can be provided. But oral antibiotics may be of benefit if a significant degree of purulent material or crust is present. Adequate coverage for staphylococci and streptococci can usually be achieved with a 5- to 10-day course of oral therapy with dicloxacillin, erythromycin, or Keflex (cephalexin, manufactured by Dista, Indianapolis, Ind.) at 250 mg four times a day.

Severe pruritus may respond to antihistamines such as Atarax (hydroxyzine, manufactured by Roerig, New York, N.Y.), 25 to 50 mg nightly, or chlorpheniramine, 4 to 8 mg nightly.

Steroids

Potent topical steroids such as Temovate (clobetasol propionate, manufactured by Glaxo, Research Triangle Park, North Carolina) or Diprolene (betamethasone dipropionate, manufactured by Schering, Kenilworth, N.J.) applied twice daily for 1 to 2 weeks are effective in the therapy of small areas of moderate-to-severe ACD. However, the mainstay of therapy for the soldier with an acute episode of extensive ACD, or severe contact dermatitis involving the face and intertriginous areas, is systemic steroids. Without therapy, and barring secondary infection or reexposure, an episode of *Toxicodendron* dermatitis can be expected to persist up to 3 or 4 weeks. Early, adequate use of prednisone or intramuscular Kenalog (tri-amcinolone acetonide, manufactured by Westwood-Squibb, Buffalo, N.Y.) can significantly shorten this course, allowing the soldier to return to duty. Prednisone should be started at 40 to 80 mg (1.0–1.2 mg/kg) per day as a single oral dose and tapered over approximately 3 weeks. Soldiers who stop prednisone therapy prematurely will frequently experience a relapse that

may result in additional days lost from service. The duration of prednisone therapy should be long enough that the soldier will complete therapy 2 to 3 weeks after the initial onset of symptoms. Alternatively, a single dose of 4 mg of Celestone (betamethasone sodium phosphate, manufactured by Schering, Kenilworth, N.J.) may be mixed with 40 to 60 mg of triamcinolone (Kenalog) for use as intramuscular therapy, providing fairly rapid onset of action and prolonged action over 2 to 4 weeks. Celestone expedites recovery and Kenalog provides the duration required to maintain clearance of symptoms. If used alone, the Celestone dose may be increased to 12 mg but must usually be repeated in 5 to 7 days. Intramuscular therapy is efficacious and ensures compliance.

SUMMARY

Contact dermatitis may result from either an immunological or nonimmunological reaction of the skin after exposure to various agents. A common form of immunological reaction or ACD is produced when sensitized individuals are exposed to urushiol, the antigen in *Toxicodendron* species (eg, poison ivy, poison oak, and poison sumac). The concentration of the contactant required to produce dermatitis is very low, and not everyone who is exposed to the antigen will develop dermatitis. In contrast, irritant contact dermatitis is a nonimmunological process and will develop in all soldiers who are exposed to a sufficiently high concentration of the irritating substance.

Soldiers may also develop dermatitis after exposure to plants for reasons other than contact with allergens or irritants. Mechanical injury from plants may result in infection from bacteria and fungi or foreign body reactions to residual material such as cactus needles or coral fragments. Dermatitis may result from pharmacologically active agents such as histamine, acetylcholine, and serotonin found in stinging nettles. Contact urticaria can be produced by a variety of substances and may be immunological, nonimmunological, or of unknown mechanism. Contact urticaria can be severe, with associated anaphylaxis.

Contact dermatitis is a very common disorder, and a high index of suspicion should be maintained in the evaluation of all cases of eczematous dermatitis. Contact dermatitis should be considered in cases of recurrent dermatitis or when dermatitis fails to respond to appropriate therapy. It should be considered in the evaluation of dermatitis that demonstrates patterns such as symmetry and linearity, or location at common sites of exposure to allergens such as the earlobes or belt buckle area. The evaluation of such dermatitis begins with a detailed history of exposure to plants, creams, lotions, solvents, and topical medications. The diagnosis may be strongly suspected based on thepatient's history and may be confirmed in many cases with use testing or patch testing.

Effective therapy for contact dermatitis exists, and soldiers should report for medical intervention as soon as dermatitis develops. Early diagnosis and therapy may significantly shorten the course of the dermatitis, allowing the soldier to return to full duty with minimal delay.

The battlefield is a harsh environment for the skin, with many potential allergens and irritants. Some of these may be indigenous to the local area, while others may be imported with the troops. If the healthcare provider is alert to the clinical appearance of contact dermatitis, makes the proper diagnosis promptly, and institutes appropriate therapy, significant morbidity can be avoided and troop strength and readiness will be enhanced.

REFERENCES

1. Winkenwerder WL. Allergy. In: Havens WP, ed. *Infectious Diseases and General Medicine.* In: Havens WP, Anderson RS, eds. *Internal Medicine in World War II*. Vol 3. Washington, DC: Medical Department, US Army, Office of The Surgeon General; 1968:192–193.

2. Pillsbury DM, Livingood CS. Dermatology. In: Havens WP, ed. *Infectious Diseases and General Medicine.* In: Havens WP, Anderson RS, eds. *Internal Medicine in World War II*. Vol 3. Washington, DC: Medical Department, US Army, Office of The Surgeon General; 1968: 620–626.

3. US Department of the Army. Skin diseases in the tropics. *US Army Med Department Bulletin.* 1944;80:10–12.

4. Kierland RR. Local use of penicillin preparations in cutaneous diseases. *Mil Surgeon*. 1945;97:57–59.

5. US Department of the Army. Dermatological problems in tropical theaters. *US Army Medical Department Bulletin*. 1945;4:299–300.

6. Woolhandler HW. Dermatology in an army station hospital. *Arch Derm Syph*. 1944;49:91–102.

7. Canizares O. Cutaneous diseases in Army Air Force Personnel. *Arch Derm Syph.* 1947;56:364–72.

8. Allen AM. *Skin Diseases in Vietnam, 1965–72*. In: Ognibene AJ, ed. *Internal Medicine in Vietnam.* Vol 1. Washington, DC: Medical Department, US Army, Office of The Surgeon General; 1977: 39, 136–139.

9. Fisher AF. *Contact Dermatitis*. Philadelphia, Pa: Lea & Febiger; 1986: 59, 220–223, 244–245.

10. Benezra C, Ducombs G, Sell Y, Foussereau J. *Plant Contact Dermatitis*. Toronto, Canada: Mosby; 1985: 58, 68–86.

11. Guin JD, Beaman JH, eds. *Plant Dermatitis.* In: *Clinics in Dermatology*. Philadelphia, Pa: Lippincott; 1986: 137–147, 175–179.

12. Polunin I. Pineapple dermatosis. *Br J Dermatol*. 1951;63:441–455.

13. Guin JD, Gillis WT, Beaman JH. Recognizing the toxicodendrons (poison ivy, poison oak, and poison sumac). *J Am Acad Dermatol*. 1981;4:99–114.

14. Stoner JG, Rasmussen JE. Plant dermatitis. *J Am Acad Dermatol*. 1983;9: 1–15.

15. Beaman JH. Allergenic Asian Anacardiaceae. In: *Plant Dermatitis. Clinics in Dermatology*. Philadelphia, Pa: Lippincott; 1986: 196.

16. Guin JD. The black spot test for recognizing poison ivy and related species. *J Am Acad Dermatol*. 1980;2:332–333.

17. Livingood CS, Rogers AM, Fitz-Hugh T. Dhobie mark dermatitis. *JAMA*. 1943;123: 23–26.

18. Goldsmith NR. Dermatitis from *Semecarpus anacardium* (bhilawanol of the marking nut). *JAMA*. 1943;123:277–330.

19. Coomber RB. Dermatitis from contact with varnish of Japanese rifles. *Arch Dermatol*. 1947;55:110–111.

20. Mitchell JC, Rook A. *Botanical Dermatology: Plants and Plant Products Injurious to the Skin*. Vancouver, Canada: Greenglass; 1979: 63–93.

21. Little C. Dermatitis produced by Japanese lacquer. *Br Med J*. 1924;1:1112–1113.

22. Marks JG Jr, DeMelfi BS, McCarthy MA, et al. Dermatitis from cashew nuts. *J Am Acad Dermatol*. 1984;10:627–631.

23. Sowers WF, Weary PE, Collins OD, Cawley EP. Ginkgo tree dermatitis. *Arch Dermatol*. 1965;91:452–456.

24. Becker LE, Shipworth GB. Ginkgo tree dermatitis, stomatitis, and proctitis. *JAMA* 1975;231:1162–1163.

25. Menz J. Contact dermatitis from plants of the Grevillea family. *Austral J Dermatol*. 1985;26:74–78.

26. Elpern DJ, Mitchell JC. Photodermatitis from mokihana fruits (*Pelea anista H. Mann*, fam. Rutaceae) in Hawaiian lei. *Contact Dermatitis*. 1984;10: 224–226.

27. Grauer FH, Arnold HL Jr. Seaweed dermatitis: First report of a dermatitis-producing marine algae. *Arch Dermatol*. 1961;84:62–74.

28. Lampe KF. Dermatitis-producing plants of south Florida and Hawaii. In: Guin JD, Beaman JH, eds. *Plant Dermatitis.* In: *Clinics in Dermatology*. Philadelphia, Pa: Lippincott; 1986: 89.

29. Jackson, WPU. Plant dermatitis in the Bahamas. *Br Med J*. 1946;2:298–300.

30. Hurtado I. Poisonous Anacardiaceae of South America. In: Guin JD, Beaman JH, eds. *Plant Dermatitis.* In: *Clinics in Dermatology*. Philadelphia, Pa: Lippincott; 1986: 183.

31. Beaman JH. Allergenic Asian Anacardiaceae. In: Guin JD, Beaman JH, eds. *Plant Dermatitis.* In: *Clinics in Dermatology*. Philadelphia, Pa: Lippincott; 1986: 191.

32. Pathak MA. Sunscreens: Topical and systemic approaches for protection of human skin against harmful effects of solar radiation. *J Am Acad Dermatol*. 1982;7:285–312.

33. Mathias TCG, Maibach HI, Epstein J. Allergic contact photodermatitis to *p*-aminobenzoic acid. *Arch Dermatol*. 1978;114:1665–1666.

34. Thompson G, Maibach HI, Epstein J. Allergic contact dermatitis from sunscreen preparations complicating photodermatitis. *Arch Dermatol*. 1977;113:1252–1253.

35. Unger PN. Clinical abstracts of an unusual case of skin sensitivity to the metal tags worn by the troops in the field. *Mil Surgeon*. 1943;92:67–69.

36. Watts TL, Baumann RR. Nickel earlobe dermatitis. *Arch Dermatol*. 1968;98:155–158.

37. Guin JD. Metal sensitivity or the case of the oozing earlobes. *J Indiana State Med Assoc*. 1982;75:37–41.

38. Emmett EA, Risby TH, Jiang L, et al. Allergic contact dermatitis to nickel. *J Am Acad Dermatol*. 1988;19:314–322.

39. Fisher AA. Detection of nickel by dimethyl glyoxime spot test. *JAMA*. 1975;234:429–430.

40. Fisher AA. Nickel dermatitis. *Dermatology*. Dec 1981:19.

41. Stutzman CD, Schmidt GD. Squamous cell carcinoma from wearing radioactive rings. *J Am Acad Dermatol*. 1984;10:1075–1076.

42. Epstein E. Shoe contact dermatitis. *JAMA*. 1969;209:1487–1492.

43. Lynde CW, Warshawski L, Mitchell JC. Patch test results with a shoewear screening tray in 119 patients, 1977–80. *Contact Derm*. 1982;8:423–425.

44. Mali JWH, Malten K, Van Neer, FCJ. Allergy to chromium. *Arch Dermatol*. 1966;93:41–44.

45. Farkas J. Chronic shoe dermatitis from chromium tanned leather. *Contact Derm.* 1982;8:140.

46. Scutt RWB. Chrome sensitivity associated with tropical footwear in the Royal Navy. *Br J Dermatol*. 1966;78:337–339.

47. Davies JH, Barker AN. Textile dermatitis. *Br J Dermatol Syphil*. 1944;56: 33–37.

48. Fregert S, Gruvberger B, Göransson K, Normark S. Allergic contact dermatitis from chromate in military textiles. *Contact Derm*. 1978;4:223–224.

49. Hatch K, Maibach HI. Textile dermatitis. *J Am Acad Dermatol*. 1985;12: 1079–1092.

50. De Groot AC, Bos JD, Jagtman BA, Bruyunzeel DP, Van Joost T, Weyland JW. Contact allergy to preservatives, Part 2. *Contact Derm*. 1986;15:218–222.

51. Eierman HJ, Larsen W, Maibach HI, Taylor JS. Prospective study of cosmetic reactions. *J Am Acad Dermatol*. 1982;6:909–917.

52. Reuveni H, Yagupsky P. Diethyltoluamide-containing insect repellent: Adverse effects in worldwide use. *Arch Dermatol.* 1982;118:582–583.

53. Lamberg SI, Mulrennan JA. Bullous reaction to diethyltoluamide (DEET) resembling a blistering insect eruption. *Arch Dermatol*. 1969;100:582–586.

54. Tindall JP. Chloracne and chloracnegens. *J Am Acad Dermatol*. 1985;13:539–560.

55. Grotte M, Younger B. Sporotrichosis associated with sphagnum moss exposure. *Arch Pathol Lab Med*. 1981;105:50–51.

56. Berky ZT, Luciano WJ, James WD. Latex glove allergy: A survey of the United States Army Dental Corps. *JAMA*. 1992;268(19):2695–2697.

57. Burge SM, Powell, SM. Contact urticaria to phosphorus sesquisulphide. *Contact Derm*. 1984;10:424–429.