Chapter 8

ARTHROPOD AND OTHER ANIMAL BITES

MARK W. COBB, M.D.*

INTRODUCTION

ARTHROPOD BITES: GENERAL CONSIDERATIONS

CENTIPEDES AND MILLIPEDES

INSECTS
- **Caterpillars and Moths**
- **True Bugs**
- **Lice**
- **Mosquitoes and Flies**
- **Beetles**
- **Stinging Insects**
- **Fleas**

ARACHNIDS
- **Ticks**
- **Scabietic Mites**
- **Nonscabietic Mites**
- **Scorpions**
- **Spiders**

REPTILES
- **Snakes**
- **Gila Monsters**

CATS AND DOGS

SUMMARY

Commander, Medical Corps, U.S. Navy; Dermatology Branch, National Naval Medical Center, Bethesda, Maryland 20814

INTRODUCTION

The phylum Arthropoda contains more species than all other phyla combined, comprising literally billions of organisms. Only a small percentage of this myriad of creatures attack humans with any frequency. The consequences of these attacks, however, can be more than trivial, especially in the military setting. Cutaneous wounds inflicted by arthropods, although often insignificant in size, frequently become secondarily infected in the combat environment. In some cases, severe systemic reactions including anaphylaxis may result from the bite or sting. An additional concern, the role of arthropods as vectors of human disease, is discussed in Chapter 9, Arthropod Infestations and Vectors of Disease, and Chapter 11, Rickettsial Diseases.

Four classes of arthropods are of dermatologic interest and are covered in this chapter: Chilopoda, including centipedes; Diplopoda, including millipedes; Insecta, including caterpillars, moths, bedbugs, lice, flies, mosquitoes, beetles, bees, wasps, hornets, fire ants, and fleas; and Arachnida, including ticks, mites, scorpions, and spiders. Bites inflicted by reptiles, specifically snakes and lizards, and by mammals such as cats and dogs are also discussed.

Documents from three of the major military conflicts of this century (World War I, World War II, and Vietnam) underscore the significant role played by arthropods in wartime illness.[1–3] Among troops in France during the later stages of World War I, one army reported that 90% of all sickness was due to scabies, infections of the skin, and fevers of unknown origin. Because most cases of skin infection were associated with scabies, pediculosis, or both, these two infestations accounted for much of the illness of that army. Records from Number 25 General Hospital in Hardelot, France, a central hospital established for the care of skin diseases, showed that scabies was responsible for 65% of all forms of pyoderma. In the forward areas during times of active combat, infestation with *Pediculus humanus* var *corporis* (body louse) was of greater significance than scabies. One British division evacuated 11.5% of its troops to field hospitals for treatment of parasitic disease (primarily pediculosis) during the year 1918. The intimate contact of individuals, their clothing, and equipment, as well as the lack of clean clothing and bed linen during combat situations, promotes the spread of pediculosis and scabies. Of the two, the body louse is more easily transferred from one individual to another and survives much more readily off humans.

During World War II, the majority of U.S. soldiers with dermatologic complaints were treated at company or camp dispensaries by medical officers with little or no training in dermatology.[2] This situation resulted in the overtreatment of minor dermatologic diseases including scabies and insect bites, frequently resulting in major disabilities. In 1945, a number of stateside hospitals organized to care for troops returning from overseas experienced a marked increase in the incidence of scabies, reflecting the frequency of the infestation in Europe. The dermatology clinic at Camp Lee, Virginia, had more cases of scabies in 1945 than any other skin disease (9.3% of cases).[2] In the European theater, scabies likewise accounted for a disproportionately large percentage of hospital admissions.

During the winter of 1942 to 1943 at the 21st Evacuation Hospital, 10% of all medical admis sions were for dermatologic disease and, of these, 30% were scabies.[2] Among six hospitals in the Mediterranean theater surveyed in 1943, parasitic infestation accounted for 4% to 18.5% of the admissions to dermatologic services.[2] Once again, soldiers often presented with pyoderma such as furunculosis, cellulitis, and impetigo due to underlying parasitic infestation, so the actual percentages were much higher. Once the field medical officers were instructed on the diagnosis and treatmentof scabies (benzyl benzoate and sulfur ointment were used), disability from the complications of scabietic infestation sharply decreased and hospitalization for this condition became uncommon. Pediculosis, unlike the case in World War I, was seen infrequently in World War II.[1]

During the 8-year span of significant U.S. military involvement in Vietnam (1965–1972), dermatologic disease accounted for 7.4% of all medical hospital admissions.[3] The annual incidence of hospitalization for skin disease was 3- to 5-fold higher than that seen among the active-duty army population in the continental United States over those 8 years. Pyoderma accounted for approximately one third of the cases. Interestingly, scabies and pediculosis were not reported as significant dermatologic diagnoses during the Vietnam conflict, and insect bites represented only about 1% of skin disease seen. One arthropod reaction reported,

however, was blister beetle dermatitis, a blistering eruption resulting from contact with cantharidin, a cutaneous irritant contained in certain beetles. Men lying on the ground were most susceptible, and the resultant denuded skin was vulnerable to secondary bacterial infection.[1–3]

ARTHROPOD BITES: GENERAL CONSIDERATIONS

The clinical reaction to an assault on human skin by an arthropod is influenced by a variety of factors.[4] The injury itself can be due to any combination of mechanical trauma, secondary infection, sensitization phenomena, and toxic effects. The nature of the host also plays a crucial role in the expression of clinical disease. Children tend to react more severely to toxins and superficial irritants and more frequently suffer secondary infection. They are more likely to handle and play with arthropods and pets harboring arthropods, and will present with bites on the hands and forearms more commonly than adults. The elderly may react more severely to toxic venoms but are less likely to develop hypersensitivity reactions to bites.

The human skin contains substances that both attract and repel insects. It has been demonstrated[4] that the attractants are found in sweat, while the repellents are concentrated in the epidermal lipids. The individual's immune status is critical in determining the reaction to an arthropod assault. This observation is perhaps most graphically illustrated in the condition known as Norwegian scabies. These patients are debilitated, immunosuppressed, or both, and when infested with *Sarcoptes scabiei,* develop extensive crusted, hyperkeratotic lesions that teem with mites.

In 1946, Mellanby described five stages of immunity to arthropod bites in the normal host[5]:

- First, in a person with no prior exposure to a particular arthropod, no reaction takes place.
- With repeated bites, a sensitivity develops that manifests as a delayed reaction beginning about 24 hours after the bite and subsiding in about a week.
- Weeks, months, or even years later, the bites may be followed by an immediate wheal reaction that clears in a few hours and is succeeded by a delayed papule.
- With further exposure, only the immediate wheal develops after the bite.
- Finally, a stage is reached where once again no reaction develops to the bite.

Antigens found in arthropod saliva are responsible for most of these immediate and delayed hypersensitivity reactions.

Toxic venoms found in salivary and sting secretions provide an important mechanism for cutaneous (and systemic) injury to arthropod bites. These venoms contain a variety of biologically active compounds including proteases, hyaluronidase, phospholipase A, kinins, histamine, 5-hydroxytryptamine, acetylcholine, adrenaline-like substances, neurotoxins, and hemolytic toxins. From this list, one can see that the result of envenomation can range from cutaneous inflammation, pain, and necrosis to severe and potentially life-threatening systemic reactions. Some arthropods secrete irritants onto the surface of the skin from body parts unrelated to feeding. Examples are the vesicants secreted by blister beetles and the urticants found on the hairs of some caterpillars.

The act of biting varies among different arthropods and may produce different clinical responses. Mosquitoes, with their fine proboscises, can penetrate capillaries with minimal damage, while tsetse flies cause significant laceration and bleeding. The mouthparts of ticks tend to break off within the skin and may cause a dense granulomatous or lymphoid dermal reaction that can be quite persistent.

Finally, environmental factors influence the nature of reactions to arthropod bites. The amount of clothing obviously determines the extent of exposed skin susceptible to bites. Some arthropods such as midges, black flies, and mosquitoes limit their attacks to exposed skin; fleas prefer covered areas. Body lice live in clothing and, therefore, their bites are found on covered skin as well. Pets and livestock can be a source of parasites, so grooming and disinfestation become important measures. Overcrowded living conditions, poor sanitation, and inadequate garbage disposal all facilitate the breeding of potentially harmful arthropods. Spiders and scorpions live in wood and litter piles as well as outhouses. Dark crevices in homes may also provide a breeding ground. In the construction of temporary military housing, infestation can be greatly reduced by such simple measures as providing mesh netting for doors and windows; elevating the floor from the ground; and separating livestock, wood piles, and latrine and garbage sites from living quarters.

CENTIPEDES AND MILLIPEDES

American centipedes have a slender, segmented body that ranges in color from yellow to green to brown or black, and may vary in length from 1 to 30 cm (Figure 8-1).[6] While the *Scutigera* species found in the eastern United States does not sting humans, the *Scolopendra* species of the western United States and Hawaii can inflict a painful sting.[7] Centipedes are nocturnal carnivores and prefer a dark, moist environment like that found under rocks and logs. Envenomation occurs by means of two hollow fangs, each connected to a venom gland. The immediate reaction consists of local burning pain and a pair of hemorrhagic puncta surrounded by erythema and edema at the sting site. Occasionally, local necrosis, regional lymphangitis and lymphadenopathy, anxiety, irregular peripheral pulses, headache, and dizziness may develop. Therapy for a centipede sting should include cleansing the wound, injecting a local anesthetic into the wound, tetanus prophylaxis, and administering systemic antihistamines.

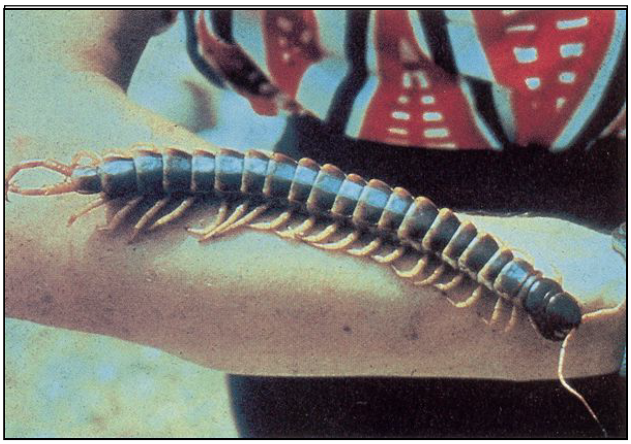

Fig. 8-1. The centipede has a multisegmented body, with a pair of legs on each segment. Its color ranges from yellow to green or brown to black. It may grow to 30 cm in length. Photograph: Courtesy of Entomology Department, Walter Reed Army Institute of Research, Washington, D.C.

Millipedes are multisegmented, with a hard, often brightly colored exoskeleton. Some tropical species may reach 30 cm in length. They are nocturnal vegetarians and, like centipedes, prefer dark, moist environments. When disturbed, millipedes will coil into a tight spiral and can then secrete a toxic liquid from repugnatorial glands located on the sides of each segment. This liquid causes an immediate burning sensation when it contacts human skin. The skin then becomes yellow-brown, and in 24 hours develops intense erythema and often vesiculation. Erosions may develop but usually heal without scar formation unless secondarily infected. Dyspigmentation, however, is a common sequelae in dark-skinned patients. If the toxic liquid should come in contact with an eye, the result is instantaneous and severe pain lasting 2 to 3 days. A chemical conjunctivitis ensues and corneal ulceration may develop. Skin contact with the toxin should be treated immediately with copious lavage of the area. Alcohol is a good solvent for the contaminating liquid, but water may be used. Management of the blisters and erosions with a topical antibiotic is similar to that of a superficial second-degree burn. Topical corticosteroids may be helpful.

INSECTS

The class Insecta comprises arthropods whose adult forms have three pairs of legs. Injury to humans can be inflicted by bites, stings, and contact with noxious hairs, venom, or excretions.

Caterpillars and Moths

Among the order of insects known as Lepidoptera, comprising butterflies and moths, contact with the poison hairs or spines of the larval form (caterpillars) or the poison hairs of the adult (moths) causes cutaneous disease.[8,9] In the United States, the venomous caterpillars (Figure 8-2) most frequently encountered are the brown-tail moth caterpillar, puss caterpillar, saddleback caterpillar, crinkled flannel moth caterpillar, slug caterpillar, and flannel moth caterpillar. They are present most often in the autumn and are usually found in trees. Their poison hairs may come in contact with the skin and mucous membranes directly by handling the caterpillars; however, the contact is usually indirect, involving hairs falling from trees, free wind-borne hairs, or objects that have been contaminated by hairs. Cocoons and egg cases can also contain the hairs. Venomous moths causing dermatitis in the United States include the brown-tail, gypsy, puss,



Fig. 8-2. Caterpillars, the larval form of moths and butterflies, may have venomous spines and hairs as shown here. Photograph: Courtesy of Entomology Department, Walter Reed Army Institute of Research, Washington, D.C.

io, and tussock moths. In Latin America, a genus of moth known as *Hylesia* is a frequent cause of moth dermatitis (Figures 8-3 and 8-4). Epidemics have resulted from the dust produced by massive numbers of this particular moth.

The cutaneous reaction to contact with poison moth hairs can range from an immediate pruritic or burning sensation to a delayed painful eruption developing 2 to 12 hours later and persisting for up to 2 weeks. The skin lesions are most commonly found on exposed areas of the upper extremities and neck, less frequently on the face, and consist of erythematous wheals, papules, vesicles, or pustules. Conjunctivitis can result from contact with the eye. Contaminated clothing may cause widespread lesions associated with systemic symptoms including rhinitis, nausea, vomiting, and low-grade fever. The puss caterpillar can cause a painful hemorrhagic lesion with marked edema and regional lymphangitis and lymphadenopathy. In rare instances, hypotensive shock can develop.

Immediate treatment for contact with poison moth hair consists of stripping the skin with adhesive tape to remove the poison hairs. Cool compresses and oral antihistamines can be tried, and systemic corticosteroids may be useful in more serious cases. Oral analgesics are at times required for the pain.

True Bugs

The order Hemiptera contains the true bugs, two of which commonly bite humans: the bedbug and the kissing bug. The bedbug, *Cimex lectularius,* is a worldwide parasite that feeds nocturnally on human blood.[10] It is a flat, oval, reddish brown insect that varies in length from 3 to 6 mm (Figure 8-5). A pair of mandibular stylets are used to pierce the skin, and a salivary anticoagulant is injected into the wound prior to the blood meal. The bedbug lives within crevices found in walls, floors, and furniture and can be detected by a characteristic pungent odor. The adult can survive more than a year without feeding and travels well in baggage. The initial bite is painless and the first manifestation may be the discovery of blood-stained bed



Fig. 8-3. This moth belongs to the genus *Hylesia*, a common cause of moth dermatitis in Latin America. Photograph: Courtesy of Entomology Department, Walter Reed Army Institute of Research, Washington, D.C.

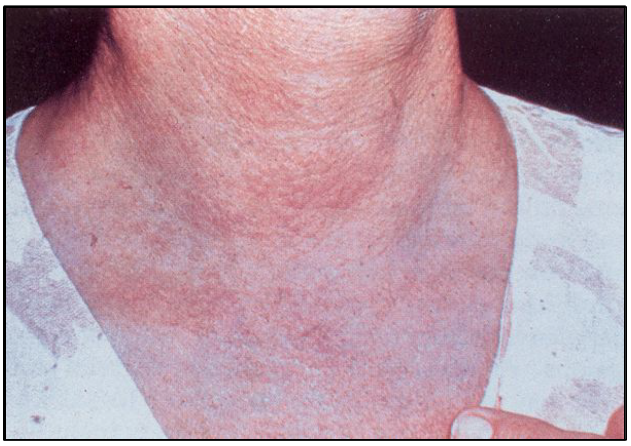

Fig. 8-4. An example of the dermatitis produced by contact with the hair of the *Hylesia* moth. Photograph: Courtesy of Entomology Department, Walter Reed Army Institute of Research, Washington, D.C.

Fig. 8-5. The bedbug, *Cimex lectularius*, is reddish brown and ranges in length from 3 to 6 mm. Photograph: Courtesy of Entomology Department, Walter Reed Army Institute of Research, Washington, D.C.

clothes and linen. Salivary antigens can elicit a hypersensitivity reaction producing urticarial papules with central hemorrhagic puncta. Lesions may be bullous and can become secondarily infected. Systemic hypersensitivity reactions including generalized urticaria, asthma, arthralgia, and even anaphylaxis have been reported. Of particular concern have been laboratory studies[10] showing that transmission of hepatitis B, *Rickettsia*, and *Leishmania* by these bugs is possible. Treatment of the bites includes topical antipruritic lotions, topical corticosteroids, systemic antihistamines, and antibiotic coverage if secondarily infected. Insecticides such as pyrethrins or malathion should be used to treat bedbugs' dwellings.

Kissing bugs comprise 14 genera of the Reduviidae insect family, several species of which are found in the western and southeastern United States.[11] These bugs are 1.5 to 2.5 cm long and brownish black with red or yellow stripes on the abdomen (Figure 8-6). They are nocturnal predators, falling on their prey from trees or the ceiling and feeding on exposed skin. In humans, the bite is often on the face, hence the name "kissing bug." The bites are usually painless and appear as grouped papules with hemorrhagic puncta or vesiculobullous lesions. A localized or generalized urticarial reaction may occur, probably secondary to salivary antigens. A variety of systemic effects including laryngeal edema, bronchospasm, angioedema, hypotension, syncope, generalized pruritus, vomiting, uterine bleeding, headache, and abdominal cramps have been reported.[11] In Latin America, this bug is a vector of *Trypanosoma cruzi*, the etiologic agent of Chagas' disease (discussed in Chapter 12, Tropical Parasitic Infections). Treatment of the bite includes topical corticosteroids, systemic antihistamines, and antibiotics if secondarily infected.

Lice

Three varieties of lice, *Pediculus humanus* var *capitis* (head louse), *Pediculus humanus* var *corporis* (body louse), and *Pthirus pubis* (pubic or crab louse), are obligate parasites of humans.[4] After attaching to human skin, they feed on blood that they suck.[7] These flattened, wingless insects have a tough integument that varies in color from gray to black. The body and head lice vary in length from 2.4 to 3.6 mm (Figures 8-7 and 8-8), while the shorter and wider pubic louse is about 2 mm long (Figure 8-9). The pubic louse is also distinguished by prominent claws on its second and third pair of legs.[12] Lice will die of starvation if kept off the body for more than 10 days. They are also killed by washing in water at 53.5°C for 5 minutes. The life span of a louse is about 30 to 45 days.

Head Lice

Head lice primarily infest children, although adults certainly may be affected. Women are more commonly infested than men. The distribution of the disease is worldwide and tends to be much more



Fig. 8-6. Pictured here are various stages in the development of the kissing bug. The adult grows to 1.5 to 2.5 cm in length and is brownish black with red or yellow stripes in the abdomen. Photograph: Courtesy of Entomology Department, Walter Reed Army Institute of Research, Washington, D.C.

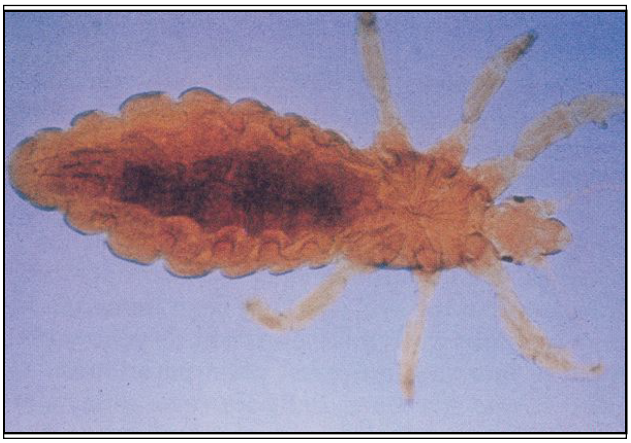

Fig. 8-7. The body louse is a wingless, gray to black insect whose length ranges from 2.4 to 3.6 mm. Photograph: Courtesy of Entomology Department, Walter Reed Army Institute of Research, Washington, D.C.

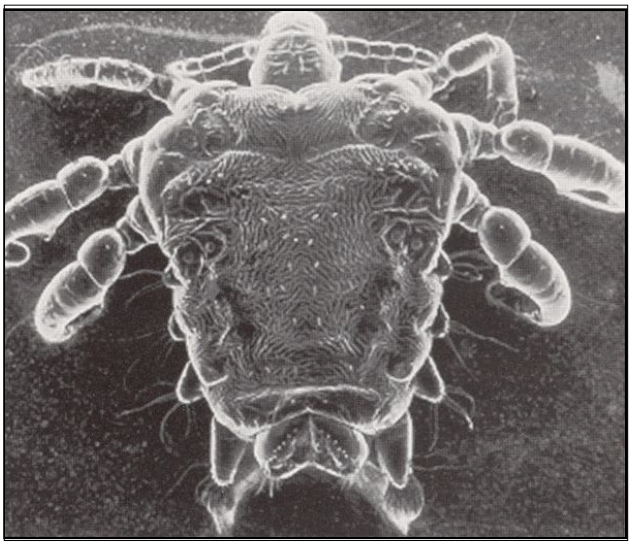

Fig. 8-9. The pubic louse is shorter (about 2 mm long) and wider than body or head lice. It has prominent claws on the second and third pairs of legs to grasp hair. Photograph: Courtesy of Entomology Department, Walter Reed Army Institute of Research, Washington, D.C.

prevalent in crowded urban centers. Once on the scalp, the female louse will lay her eggs (nits) at the base of the hair. The nits are cemented to the side of the hair shaft and move distally with hair growth (Figure 8-10). Often these nits are the only clinical evidence of infestation, as the lice are difficult to find. The nits are usually found in the warm areas of the scalp such as behind the ears and on the posterior neck. Patients generally note an itching or pricking sensation and the hair may appear lusterless and dry. The scalp can become secondarily infected from scratching, presenting as an impetigo or folliculitis. Adequate treatment requires that both the adult lice and the nits be killed. Because

Fig. 8-8. The head louse is similar in size and shape to the body louse. Its clawlike legs allow it to grasp the hair of its host. Photograph: Courtesy of Entomology Department, Walter Reed Army Institute of Research, Washington, D.C.

Fig. 8-10. The oval eggs (nits) of a head louse are cemented onto hair shafts and move distally with hair growth. Photograph: Courtesy of Entomology Department, Walter Reed Army Institute of Research, Washington, D.C.

the nits hatch in 7 days, two treatments a week apart are recommended to ensure complete eradication of the lice. Although lindane (gamma benzene hexachloride, or Kwell [manufactured by Reed & Carnrick, Jersey City, N.J.]) shampoo or lotion is most frequently used, a recent study found malathion lotion to be significantly more effective in killing both adult lice and nits.[13] Natural pyrethrin products (A-200 [manufactured by SmithKline Beecham, Pittsburgh, Pa.], RID [manufactured by Pfizer, Parsippany, N.J.]), and synthetic permethrin (Nix, manufactured by Burroughs Wellcome, Research Triangle Park, N.C.) are also effective. The nits are best removed with a comb after soaking the hair in a vinegar solution. Family members and other personal contacts should also be treated.

Body Lice

Unlike head lice, body lice live and lay eggs in the seams of clothing and contact human skin only to feed. They generally infest individuals with poor hygiene, producing what has been named vagabond's disease. This louse can be a vector for epidemic typhus, louse-borne relapsing fever, and trench fever. Patients present with pyoderma involving areas covered by clothing, most notably the trunk, axillae, and groin. Erythematous macules, papules, and wheals, as well as excoriations may also be seen. The most significant symptom is severe pruritus. In endemic cases, pediculocides are unnecessary and adequate treatment consists of a hot shower and clean clothes. A hot wash will kill the organisms on infested clothing. Antibiotics are necessary if secondary infection is present. For epidemics of body lice, as may be seen in wartime situations, heavy infestation requires the use of insecticides such as dichlorodiphenyltrichloroethane (DDT) powder, lindane 1% powder, or malathion 1% powder. Resistant organisms have emerged from all of these regimens, however.

Pubic Lice

Pubic lice limit their infestation to areas where the hair is short and are found primarily in the pubic hair. They may, however, spread to body hair, axillary hair, beard hair, eyebrows, eyelashes, and occipital scalp hair. Pediculosis pubis is spread most commonly by sexual contact and should prompt a search for other sexually transmitted diseases. Patients can remain asymptomatic for up to a month before pruritus develops. Nits, similar to those in pediculosis capitis, are seen. The lice are found wrapped around a single hair in the case of larvae; adults grasp two adjacent hairs. Blue macules (maculae ceruleae) are often seen on the surrounding skin and are believed to be produced by louse saliva acting on blood products. Pubic lice should be treated with lotions or shampoos containing 1% lindane, 0.3% pyrethrins, or 5% permethrin. These drugs should be applied topically, left on for 10 minutes, then reapplied once 7 to 10 days later. Infestation of the eyelashes has been treated in the past with physostigmine ointment or yellow ointment of mercury; however, plain petrolatum, applied two to five times daily for several days, appears to work as well and is much safer. Clothing should be washed in hot water.

Mosquitoes and Flies

Mosquitoes and flies are two-winged, biting insects belonging to the order Diptera.[7] They all require a blood meal at some time in their development. To acquire this meal, they often attack human skin, causing a bite reaction.[14] These bites can manifest as immediate urticarial papules, delayed erythematous papules, or both, depending on the host's state of immunity, as discussed previously. Fly larvae (maggots) may also invade tissue, producing a condition known as myiasis. If the eggs are deposited on an open wound, the larvae cause wound myiasis; eggs deposited beneath the skin via a puncture cause furuncular myiasis.

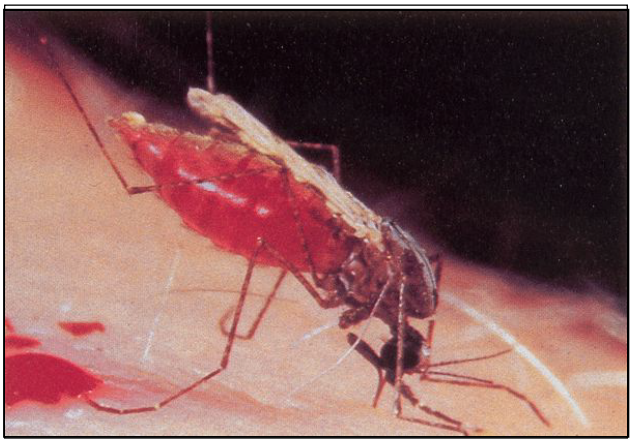

Fig. 8-11. Mosquitoes are characterized by their delicate wings, long, thin legs, and long feeding proboscises. The *Anopheles* mosquito is shown here. Photograph: Courtesy of Entomology Department, Walter Reed Army Institute of Research, Washington, D.C.

TABLE 8-1

MOSQUITOES AND FLIES AS VECTORS OF INFECTIOUS DISEASE

Table 8-1 is not shown because the copyright permission granted to the Borden Institute, TMM, does not allow the Borden Institute to grant permission to other users and/or does not include usage in electronic media. The current user must apply to the publisher named in the figure legend for permission to use this illustration in any type of publication media.

Adapted with permission from Alexander JO. *Arthropods and Human Skin*. Berlin, Germany: Springer-Verlag; 1984: 117.

Mosquitoes

Mosquitoes, belonging to the family Culicidae, are delicate winged insects with long proboscises and long, thin legs (Figure 8-11). They require water to mature through the larval and pupal stages, explaining the presence of mosquitoes near standing water. A number of factors attract mosquitoes to humans including moisture, warmth, carbon dioxide, estrogens, and L-lysine in sweat.[15] Mosquitoes can be the vector for filariasis, yellow fever, dengue fever, and malaria, among other diseases (Table 8-1). Cutaneous reactions to mosquito bites include urticarial wheals, delayed papules, bullous lesions, hemorrhagic necrotic lesions, excoriations, eczematous patches, and granulomatous nodules.[16] Mosquito bites can be treated with topical corticosteroid creams, antipruritic lotions, and/or a dilute solution of meat tenderizer (containing the enzyme papain, which provides rapid relief of pruritus). Bites can be prevented by repellents that contain diethyltoluamide (DEET, marketed as Off!, Sportsmate II cream, or Cutter Laboratories' Insect Repellent) or ethyl hexanediol (6-12 Plus). Interestingly, Avon's Skin-So-Soft moisturizer acts as an excellent repellent. Protective clothing and mosquito netting are both effective for the outdoor setting.

Flies and Maggots

A variety of flies commonly bite humans, including sandflies (*Phlebotomus* and *Lutzomyia* species), black or buffalo flies (*Simulium* species), Ceratopogonidae (biting midges), members of the family Tabanidae (which includes the deerfly and horsefly), and tsetse flies (Figure 8-12). The common housefly does not bite, but rather feeds on the surface of the skin (Figure 8-13). A number of infectious diseases can be transmitted by biting flies (see Table 8-1). The cutaneous reaction to these bites, like those of mosquitoes, may be immediate, delayed, or both. Relief is provided by antipruritic lotions and topical corticosteroids. Repellents applied topically or impregnated in clothing can pre-

Fig. 8-12. The sandfly is a vector of leishmaniasis and bartonellosis. Photograph: Courtesy of Entomology Department, Walter Reed Army Institute of Research, Washington, D.C.



Fig. 8-13. The housefly feeds on the surface of the skin rather than biting. Photograph: Courtesy of Entomology Department, Walter Reed Army Institute of Research, Washington, D.C.

vent fly bites. DEET, ethyl hexanediol, chlorodiethyl benzamide, and Avon's Skin-So-Soft are all good topical repellents. An effective combination repellent is topical DEET and permethrin-impregnated clothing.

Myiasis, or infestation with fly maggots, has an almost worldwide prevalence, although it is more common in the tropics. The disorder is caused by many different species of fly and affects any exposed surface. Cerebral, facial, nasal, aural, oral, ophthalmological, urethral, rectal, and vaginal disease have all been reported.[14] In North America, wound myiasis is probably the most common form. Flies first lay their eggs on the injured surface where the soft larvae or maggots hatch. Some species ingest only necrotic material; others may attack adjacent normal tissue. A variety called screwworms can burrow deeply into living tissue, causing extensive damage. In the past, larvae of the black blowfly were commercially available for wound debridement. Wound myiasis is treated by extraction of the maggots after prior application of 10% chloroform in vegetable oil or ether to the wound. For deep or extensive infestation, repeated chloroform irrigation may be required.[4]

Furuncular myiasis is produced when (*a*) adult flies puncture the skin to lay their eggs, (*b*) flies lay their eggs on the skin surface and hatched larvae burrow into the skin and subcutaneous tissue, or (*c*) fly eggs, which have been attached to the body of a mosquito, tick, or stable fly, are deposited on human skin and enter via the bite wound of these vectors. The human botfly, *Dermatobia hominis*, is the most common cause of furuncular myiasis in Central and South America (Figures 8-14 and 8-15). Infants and young children are the most frequently affected, although patients of all ages are seen.[17]

Clinically, a raised, erythematous papule develops at the site of the bite, most frequently on the distal extremity or scalp. Over the next 3 weeks it gradually enlarges to become an indurated nodule with a central punctum, which is the breathing tube for the larva (Figure 8-16). Serum and pus may be discharged from this highly pruritic and intermittently painful lesion. Regional lymphadenopathy, as well as a papulovesicular hypersensitivity eruption on the surrounding skin and hands, may be seen. In about 7 weeks, the larva will mature and emerge from the nodule, although patients usually seek treatment much earlier because of pain (Figure 8-17). Effective therapy requires surgical incision



Fig. 8-14. The human botfly is the most common cause of furuncular myiasis in Latin America. Photograph: Courtesy of Entomology Department, Walter Reed Army Institute of Research, Washington, D.C.

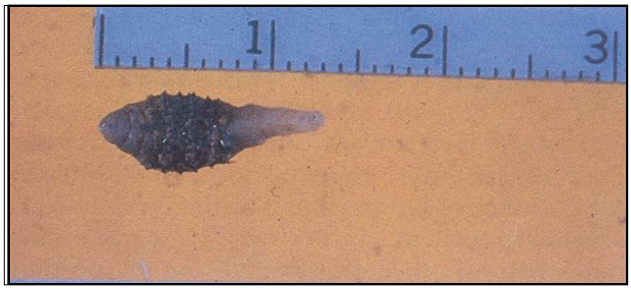

Fig. 8-15. The larval form of the botfly burrows into the skin and subcutaneous tissue, producing a furuncular lesion (ruler in cm). Photograph: Courtesy of Entomology Department, Walter Reed Army Institute of Research, Washington, D.C.

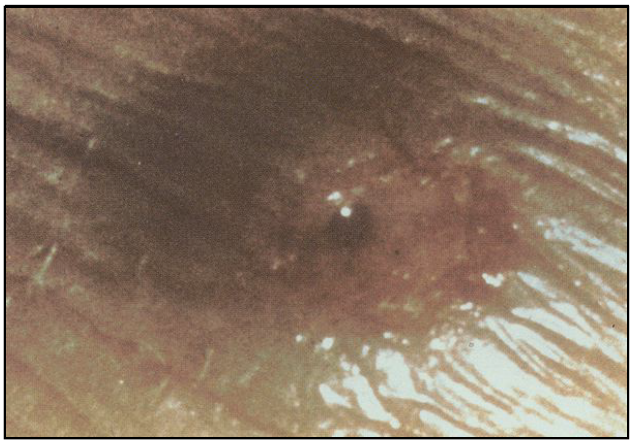

Fig. 8-16. The furuncular lesion of myiasis is an indurated nodule with a central punctum, which serves as the breathing tube for the larva. Photograph: Courtesy of Entomology Department, Walter Reed Army Institute of Research, Washington, D.C.

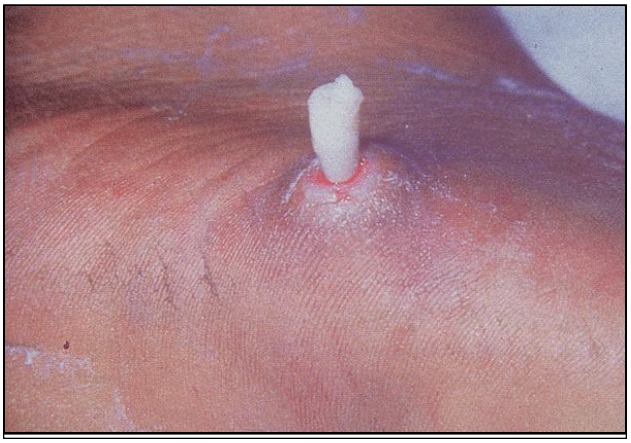

Fig. 8-17. A larva is shown emerging from a furuncular lesion. Patients are often unable to wait for this to occur because of the pain of the lesion. Photograph: Courtesy of Entomology Department, Walter Reed Army Institute of Research, Washington, D.C.

of the nodule and extraction of the larva, after anesthetizing the lesion and larva with lidocaine or chloroform. Natives in endemic areas cover the lesions with a thick layer of pork fat, occluding the breathing tube. Within 24 hours, the larva migrates out and can easily be removed.

Beetles

Blister beetles cause cutaneous injury when a potent vesicating agent, cantharidin, is released from their bodies and contacts human skin. When handled, these insects excrete the vesicant in hemolymph from their knee joints, prothorax, and genitalia.[4] *Lytta vesicatoria*, also known as "Spanish fly," is the source of cantharidin, which is used medicinally for the treatment of warts. Two species, *Epicauta vittata* and *E pennsylvanica*, are found in the southern and southwestern United States.[18] They can be up to 1 in. long and are found in alfalfa fields, along fence rails, and in flower beds. Several minutes after contact with the vesicant, the patient experiences a tingling or burning. Blisters develop within a day, then dry up and desquamate in about a week (Figure 8-18). Extensive contact with cantharidin can cause toxic symptoms including stomatitis, salivation, hematemesis, abdominal pain, diarrhea, and dysuria. The affected skin should be washed immediately with alcohol, acetone, ether, or soap to dissolve or dilute the cantharidin. The blisters are treated with wet compresses and topical corticosteroids.

OK to put on the Web

Fig. 8-18. Resolving lesions induced by the blister beetle desquamate in about 1 week. Photograph: Courtesy of Entomology Department, Walter Reed Army Institute of Research, Washington, D.C.

Stinging Insects

Insects of the order Hymenoptera, including bees, wasps, hornets, and fire ants, are known for producing a painful sting that may, rarely, result in anaphylaxis and death.[19] The venoms of these insects have not been completely characterized, but contain biogenic amines (histamine, norepinephrine, dopamine, serotonin, and acetylcholine), enzymes (phospholipase A and B, hyaluronidase, esterases, and phosphatases), and other peptides (kinins and mast cell degranulation peptide).[20]

The reactions produced by Hymenoptera stings are classified as (*a*) local, (*b*) systemic toxic, (*c*) systemic allergic, and (*d*) other (Table 8-2). The common local reaction is erythema, edema, and pain at the site of the sting, resolving in several hours. The swelling can occasionally extend to involve a large area (eg, an entire limb) and last for several days. Wells' syndrome, consisting of erythematous, edematous plaques composed histologically of eosinophilic granulomatous dermatitis, may be related to stings.[4,21] Systemic toxic reactions are produced by the pharmacological action of a large dose of venom from multiple stings. Constitutional symptoms such as nausea, malaise, fever, and even anaphylactoid reactions may result. Systemic allergic reactions are produced when specific immunoglobulin (Ig) E antibodies fixed to the surface of basophils and mast cells bind to antigens in the venom, causing degranulation and the release of vasoactive substances. Symptoms range from urticaria and angioedema, which may be associated with nausea, vomiting, dizziness, and wheezing, to a fully developed anaphylactic reaction including hypotension, laryngeal edema, and bronchospasm. Every year, insect allergy accounts for approximately 40 fatalities in the United States.[21] Severe allergic reactions are more common in men, especially when stung on the head and neck. Finally, there have been case reports[21] in which serum sickness, acute glomerulonephritis, and Guillain-Barré syndrome have been associated with Hymenoptera stings.

TABLE 8-2

REACTIONS TO HYMENOPTERA STINGS

Type of Reaction	Effects
Local	Immediate erythema and edema, extensive swelling (may include entire extremity), eosinophilic cellulitis (Wells' syndrome)
Systemic toxic	Nausea and vomiting, malaise, fever, anaphylactoid reaction
Systemic allergic	Urticaria or angioedema, or both; nausea, vomiting, dizziness, and wheezing; anaphylaxis (hypotension, laryngeal edema, and bronchospasm)
Other	Serum sickness, acute renal failure, possible Guillain-Barré syndrome

Fig. 8-19. Honeybees are found around flowering plants and are unique among stinging insects, having a barbed stinger that causes it and venom sac to be left on the victim. The bee is eviscerated and dies after stinging. Photograph: Courtesy of Entomology Department, Walter Reed Army Institute of Research, Washington, D.C.

Bees, Wasps, and Hornets

The Apoidea family includes honeybees and bumblebees (Figure 8-19). Honeybees feed on flowering plants and can be encountered in the wild, such as on clover, or in commercial hives. They are unique among the stinging insects in that their stinger contains a barb, causing it to be left on the victim along with the venom sac. This act eviscerates and kills the bee and also allows the sting to be identified as that of a honeybee, for the venom sac is visible. In 1957, swarms of African bees escaped from a laboratory in Brazil, where they were being used in cross-breeding experiments attempting to improve honey production. These African or "killer" bees are known for their aggressive stinging behavior in defense of their colonies. Their steady march northward through Central America and Mexico has been well documented in the press.

Wasps, yellow jackets, and hornets are members of the Vespidae family. Paper wasps build hives under the eaves of buildings; yellow jackets are ground-nesting, and hornets reside in shrubs and trees. These insects are often found around trash containers or discarded food. They may sting multiple times, although usually only when provoked.

After a honeybee sting, care must be taken in removing the stinger and attached venom sac, for pressure will release more venom. Lateral scraping with a knife blade is recommended. The local reactions produced by Hymenoptera stings can be treated with ice packs, elevation, topical corticosteroids, systemic antihistamines, and, if necessary, analgesics. Application of a dilute solution of meat tenderizer will provide rapid pain relief. Systemic corticosteroids are helpful in the more extensive local reactions. Anaphylaxis is a medical emergency requiring airway protection and the maintenance of systemic blood pressure with parenteral epinephrine, intravenous fluids, and, in some cases, vasopressor agents. Individuals who have experienced an anaphylactic reaction should carry a beesting kit, such as Ana-Kit or Epi-Pen, which includes epinephrine and antihistamines. Medic-Alert jewelry should also be worn. Individuals with Hymenoptera allergy, documented by history and skin testing, are candidates for hyposensitization therapy. This treatment involves venom immunotherapy, which generally provides partial protection. Outdoor dining and the wearing of brightly colored clothing should be avoided by these individuals.

Fire Ants

Fire ants, included in the Formicidae family, are unique among the Hymenoptera in several ways. Their venom is composed primarily of nonimmunogenic, low-molecular-weight alkaloids with only a small percentage of the immunogenic proteins found in the venom of bees, wasps, and hornets. They sting by first biting the victim with their powerful set of pincer jaws, then swiveling about their attached head and stinging in a circular pattern. Fire ants may be red or black and live in ground colonies in the southeastern United States. They are aggressive and tend to attack in swarms, with up to 5,000 bites in a single attack being reported.[22] These painful stings are very distinctive clinically: two central hemorrhagic puncta are surrounded by a ring of erythematous papules that first become vesicles, then sterile pustules. Associated seizures and mononeuropathy have been reported.[7] Anaphylaxis may occur, but is less likely than with other Hymenoptera. Local therapy, including meat tenderizer,[22] is generally ineffective for these painful stings, and a specific antivenin is not available.

Fleas

Fleas are wingless insects that, in pursuit of their blood meals, can infest most warm-blooded animals.[7] Humans may be bitten by the human flea (*Pulex irritans*) as well as by the cat, dog, rat, squirrel, mouse, chicken, and sand fleas. Among the various species are found the vectors for bubonic plague, endemic typhus, tularemia, and intestinal tapeworm.[4] Their distribution is cosmopolitan, favoring overcrowded environments. Although wingless, fleas are equipped with powerful legs that allow them to jump from host to host (Figure 8-20). Their bites are probably the most common skin lesions inflicted by arthropods (Figure 8-21).

Fleas often bite at the ankle, wrist, or waistline, where they encounter the edge of clothing. The bites are frequently grouped in twos and threes with a somewhat irregular distribution. The individual lesions are papules, vesicles, or bullae, often with a central hemorrhagic punctum and an erythematous halo. Due to their pruritic nature, they commonly become excoriated and secondarily impetigenized. Chronic reinfestation in a hypersensitive host can produce a variety of hivelike and



Fig. 8-20. Fleas are wingless insects with powerful legs allowing them to jump from host to host. Photograph: Courtesy of Entomology Department, Walter Reed Army Institute of Research, Washington, D.C.

Fig. 8-21. Flea bites are often encountered in areas at the edge of clothing, such as the ankle, wrist, and waistline. The lesions usually have a hemorrhagic central punctum and erythematous halo. Photograph: Courtesy of Entomology Department, Walter Reed Army Institute of Research, Washington, D.C.

persistent papules known as papular urticaria. Antipruritic lotions and topical corticosteroid creams will provide symptomatic relief for the cutaneous lesions. Antibiotics may be required for treatment of secondary infection. Topical repellents effective for fleas include DEET and pyrethrins, and clothes impregnated with benzyl benzoate. Household pets should be treated with a pesticide such as pyrethrin powder. Carpets, floors, furniture, and draperies need to be treated with a pesticide as well. Pyrethrins, malathion, and carbaryl are all effective and should be used monthly for two or three applications.

The sand flea (*Tunga penetrans*) produces a unique clinical lesion in humans. It is found in Central and South America, equatorial Africa, and the southern United States. The gravid female burrows into the skin and enlarges to the size of a pea. If allowed to remain in the skin, she extrudes her eggs through a surface opening after 1 to 2 weeks, then dies. The site of invasion is usually the feet, particularly around the toes, but can also be the thighs, perineum, and genitalia. The cutaneous lesion is a 1- to 2-cm, firm, tender nodule with a black spot in the center. Secondary infection and regional adenopathy may occur. Treatment of sand flea infestation (tungiasis) consists of excision or curettage of the flea, tetanus prophylaxis, and, if infection is present, antibiotic coverage.

ARACHNIDS

The class Arachnida is composed of arthropods whose adult forms have four pairs of legs. They may cause human injury by biting, burrowing in and feeding on skin, stinging, and delivering toxic venom.

Ticks

There are two families of ticks: the hard ticks (Ixodidae), with a hard chitinous dorsal shield, and the soft ticks (Argasidae), which lack this dorsal shield (Figures 8-22 and 8-23). Hard ticks can endure cold, humid weather, while soft ticks prefer drier environments.[23] Both types are frequently found in shrubby or wooded areas. Ticks are natural parasites of many different animals including mammals, birds, reptiles, and amphibians. Varieties from both tick families will occasionally attack humans. Once attached to human skin, they can remain feeding for several days until becoming so engorged with blood that they drop off. Although the cutaneous reaction from a tick bite may be quite symptomatic, ticks are most notorious as vectors for numerous infectious diseases (Exhibit 8-1). The six-legged larvae, the eight-legged nymphs, and adult ticks can all transmit disease.

Fig. 8-22. A soft tick (*Dermacentor* sp). Photograph: Courtesy of Entomology Department, Walter Reed Army Institute of Research, Washington, D.C.

Fig. 8-23. Two hard ticks (*Ixodes scapularis*), the one on the right engorged with a blood meal. *I scapularis* is the vector for Lyme disease. Photograph: Courtesy of Entomology Department, Walter Reed Army Institute of Research, Washington, D.C.

In addition to these infectious diseases, ticks may cause two syndromes, tick-bite alopecia and tick paralysis, both presumably due to secreted toxins.[4] The former is a patchy alopecia at the site of tick attachment that clinically resembles alopecia areata. The hair loss begins about 1 week after the tick is removed and may take up to 2 months to completely regrow. Tick paralysis is an ascending flaccid paralysis resembling Guillain-Barré syndrome. The onset is heralded by leg weakness and can progress to complete flaccid paralysis, resulting in dysarthria, dysphagia, respiratory failure, and death. The paralytic symptoms usually disappear rapidly if the tick is found and removed from the skin. Residual neurological sequelae after removal of the tick are very rare. These two syndromes are also discussed in Chapter 9, Arthropod Infestations and Vectors of Disease.

The initial bite of the tick is usually painless but becomes a pruritic, urticarial lesion in a few hours. If undetected, the tick can remain attached to the skin for over 1 week, becoming completely engorged with blood. While it feeds, the host may develop fever, chills, headache, abdominal pain, and vomiting (tick-bite pyrexia).[7] These symptoms resolve a day or two after the tick is removed. The cutaneous lesion is generally an erythematous papule with a red halo, but may become bullous or ulcerated. Firm, pruritic nodules lasting for months to years have been observed after tick bites. When examined histologically, these nodules can show worrisome features suggestive of cutaneous lymphoma. Patients may also develop persistent gyrate (annular and polycyclic) erythemas after a tick bite.

Initial treatment consists of finding and removing the tick. This should be done with steady, gentle traction so as not to leave any broken-off tick parts in the skin. As with other arthropod bites, the pruritic skin lesion is treated with topical corticosteroids, antipruritic lotions, and systemic antihistamines. Persistent nodular lesions often require intralesional corticosteroid injection or even surgical excision. Protective clothing as well as an insect repellent such as DEET should be used when exposure to ticks is anticipated. The history of a tick bite should heighten the clinician's awareness for early signs and symptoms of associated infectious diseases, allowing for prompt treatment.

EXHIBIT 8-1

INFECTIOUS DISEASES WITH TICKS AS VECTORS

Exhibit 8-1 is not shown because the copyright permission granted to the Borden Institute, TMM, does not allow the Borden Institute to grant permission to other users and/or does not include usage in electronic media. The current user must apply to the publisher named in the figure legend for permission to use this illustration in any type of publication media.

Adapted with permission from Alexander JO. *Arthropods and Human Skin*. Berlin, Germany: Springer-Verlag; 1984: 364.

Scabietic Mites

Scabies is an infestation with the eight-legged human mite known as *Sarcoptes scabiei*. The adult scabietic mite is approximately 0.4 mm in length, barely visible to the naked eye as a black speck. Adult mites copulate on the skin, after which the female will burrow, laying her eggs along the way.[24] Six-legged larvae hatch and pass through several nymphal stages before becoming adults. This life cycle takes 10 to 14 days. Scabietic mites generally will survive off the human body for only 2 to 3 days under normal room conditions. Initial infestation is completely asymptomatic, and it is not until about 30 days later that an immune response develops to the mites or their excrement (scybala). At this point, pruritus and cutaneous inflammation appear. Although widespread skin lesions may be present with this infestation, it has been demonstrated that the average number of mites per patient is 11.[25] Mites are found most frequently on the hands, wrists, elbows, axillae, breasts, umbilicus, and genitalia. Scabies is usually spread by close personal contact with an infested individual. Although sexual intercourse is probably the most frequent mode of transmission among single adults, embracing, sharing a bed, or even shaking hands may also transmit the disease. Fomites (eg, clothing) can also play a role in the spread of scabies.

Two types of cutaneous lesions are seen with scabies: intact or excoriated burrows, which are produced by the adult female mite, and erythematous papules, which are believed to represent the host's immune response to the parasite. The burrows are slightly elevated, linear lesions that are best observed with a hand lens. At one end of the burrow, a black speck, vesicle, or pustule is sometimes observed, indicating the location of the female mite. The burrows are frequently excoriated and may become secondarily infected, resulting in crusting, pustule formation, or furunculosis. Burrows are often found in the digital web spaces, wrists, axillae, nipples, umbilicus, and genitalia. The erythematous papules are usually found on the trunk but may become widespread. Eczematous and urticarial lesions can also be seen as part of the immune response to scabies infestation. In adult patients, the scalp and face are uninvolved, although infants can develop lesions over the entire cutaneous surface.[7] The pruritus of scabies is generally severe and most noticeable at night. Diagnosis of this infestation rests on demonstrating the mites, eggs, larvae, or scybala on microscopical examination of lesional skin scrapings (Figure 8-24). Scraping is best accomplished with a number 15 surgical blade coated with mineral oil. An intact burrow, generally found in the locations listed above, will provide the highest yield for identifying organisms.

Two clinical variants of scabies exist: nodular scabies and Norwegian scabies. In the former, one sees a few erythematous or violaceous, firm nodules that persist for weeks to months after treatment, long after the rest of the eruption has resolved. These nodules are commonly found on the male genitalia and axillary folds. Norwegian scabies is seen in immunocompromised or debilitated patients. Recently, it has been reported[4] in association with acquired immunodeficiency syndrome. These patients present with thick, scaling, crusted plaques that are found most commonly on the hands, feet, and scalp but may be generalized in distribution. Unlike those seen in common scabies, the lesions on these patients are teeming with mites, with one source[4] estimating the total body load of parasites and eggs to be 5 to 10 million! Patients with Norwegian scabies, often found in hospitals or nursing homes, are therefore highly contagious and can be responsible for local epidemics of scabies.

Treatment of scabies requires ridding the body of mites, relieving symptoms, and treating secondary infection. A variety of medications are available as scabicides, the most widely used being lindane cream or lotion. Neurotoxicity has been reported

Fig. 8-24. Microscopical examination of lesional skin scrapings from a patient with scabies reveals a larval mite form (with three pairs of legs) on the left and four ova on the right. The adult mite (not shown) is about 2- to 3-fold larger than the larva and has four pairs of legs. Photograph: Courtesy of Entomology Department, Walter Reed Army Institute of Research, Washington, D.C.

when lindane is applied to the eczematous skin of infants or when excessive amounts have been used inappropriately (eg, ingesting the liquid); however, lindane is generally safe. The drug should be applied to dry skin, covering the entire cutaneous surface from the neck down, and left on for 8 hours. Re-treatment 2 to 7 days later is suggested to kill any newly hatched nymphs. Opinions vary on the safety of lindane when used in children under the age of 2 years.[26] An alternative for this population, as well as pregnant women, is 5% to 10% precipitated sulfur in petrolatum applied nightly for 3 nights. Elimite cream (5% permethrin, manufactured by Herbert Laboratories, Irvine, Calif.) is a recent addition to the scabicides. Elimite (applied topically from the neck down, left on for 8 h, then reapplied in 48 h) is reported to be equal to or better than lindane and safe in infants older than 2 months.[27] Another agent, although less effective, is Eurax cream (25% crotamiton, manufactured by Westwood Pharmaceuticals, Buffalo, N.Y.), which should be applied topically from the neck down with a second application 24 h later. It is important to treat all close contacts and sexual partners of the patient with the chosen scabicide, for reinfection is a frequent problem. Because the mites survive off humans for only 2 to 3 days, it is necessary to wash only recently used bed linen and clothing in hot water.

Although killing the mites usually provides a rather dramatic reduction in pruritus, individuals with scabies may continue to itch for several weeks. Pruritus is controlled with systemic antihistamines as well as topical corticosteroids and antipruritics. Nodular scabies may require a one-time intralesional injection of a corticosteroid such as triamcinolone acetonide, 2.5 to 10 mg/mL. Any secondary skin infection should be treated with the appropriate antibiotic.

Nonscabietic Mites

In general, the reaction caused by nonscabietic mites is due to a combination of secreted toxins and allergic sensitization. The cutaneous primary lesion is typically a red papule with a central hemorrhagic punctum or vesicle. However, due to their pruritic nature, the lesions often become crusted, eczematized, and secondarily infected. Occasionally, widespread eruptions develop, probably as an allergic phenomenon. These conditions include urticaria, angioedema, erythema, eczematous dermatitis, a varicelliform eruption, and an erythema multiforme-like reaction.[28] In most instances, the causative mites cannot be demonstrated on the patients. Unless indicated otherwise, the treatment of bites from all these mites consists of topical corticosteroid creams and antipruritic lotions.

Variants of *Sarcoptes scabiei* can infest and produce cutaneous disease in many different animals including dogs, cats, horses, goats, pigs, sheep, and cattle.[24] Humans are infested after coming in contact with the host animal. These mites are unable to complete their life cycle on human skin and burrow only a short distance into the skin. Cutaneous lesions, consisting of intact and excoriated papules, occur on areas most closely in contact with the animal such as the arms, wrists, and abdomen. Skin scrapings from humans are almost always negative and the causative mite must be demonstrated in the host animal. The disease in humans is self-limited and is treated symptomatically. The infested animal should be treated by a veterinarian to prevent reinfestation.

A variety of mites are blood-feeding parasites (*Sarcoptes scabiei* feed on skin) that can prey on humans. Often the primary host is a bird, mammal, reptile, or even another arthropod, and humans are involved secondarily.[28] The tropical rat mite, *Ornithonyssus bacoti*, which commonly infests the black rat, is found in both tropical and temperate urban centers. When the rodents are exterminated, the mites seek alternative hosts and at this time humans are often bitten. The mites tend to accumulate in warm areas such as near appliances or heating systems. The bite of the tropical rat mite is characteristically painful and pruritic. Lesions appear as small hemorrhagic papules, usually on the arms and legs. These papules can become eczematized and secondarily infected after they have been scratched.

Allodermanyssus sanguineus is a parasite of house mice, rats, and other small rodents, and its distribution is worldwide. This mite is medically important as the vector of *Rickettsia akari*, the agent responsible for rickettsialpox. Within the mites, the rickettsial organisms are transmitted transovarially from adult to the next generation. Adult mites transmit the disease to humans. The first lesion to appear is a crusted papulovesicle at the site of the bite. This lesion is followed in about a week by fever, chills, sweats, headache, backache, and generalized papulovesicular eruption that may resemble varicella.[7] Tetracycline (250 mg orally every 6 h for 14 d) is the drug of choice for rickettsialpox. For a detailed discussion of rickettsialpox, see Chapter 11, Rickettsial Diseases.

Several species of mites infest birds as their primary host. The northern fowl mite, *Ornithonyssus sylviarum*, is found in birds and domestic fowl of the

northern temperate areas. Bird handlers are most commonly bitten. Two mites, *Dermanyssus gallinae* and *Ornithonyssus bursa*, can infest domestic poultry. Consequently, pruritic and painful bites may be seen on individuals working in the poultry industry. These two mites also parasitize a number of wild birds including sparrows, starlings, and pigeons. When these birds leave their nests, as in times of migration, humans may be bitten.

The Pyemotidae family of mites have as their hosts a variety of insects that in turn infest grain, straw, seeds, other stored food products, timber, and furniture. The human victims of these mites include farm workers at harvest time, animal feed handlers, florists, and individuals exposed to infested furniture. Cutaneous lesions can be papular, urticarial, vesicular, or pustular.

Cheyletiellidae are nonburrowing mites that commonly infest domestic animals including dogs, cats, and rabbits. Often the pet appears asymptomatic, but on close inspection has "walking dandruff." Because of this, the pet is often overlooked as a source of the bites. Humans are bitten more commonly during the cold winter months when animals are brought indoors. The skin lesions are found on the forearms, thighs, chest, and abdomen where pets are held. They consist of small papules or pustules, frequently with a characteristic necrotic center. Urticarial lesions and widespread erythema may occur. The eruption will disappear when the pet is treated.

The final group of mites to be discussed are those from the family Trombiculidae, commonly known as chiggers, red bugs, or mower's mites. Only the six-legged larval form parasitizes other animals (Figure 8-25). These red larvae, found on the ground or in grass, will attach to a host, feed for 2 to 3 days, molt to the nymphal stage, and then leave the host. They feed through a tube called the stylostome, which is inserted into the epidermis. Bites are commonly seen between May and October when the larvae are active. As the host walks through infested vegetation, the larvae crawl up the legs and usually stop to feed where the clothing constricts, such as the ankles, thighs, or beltline. The initial bites are not felt and the skin lesions develop 3 to 24 hours later when an allergic reaction to mite saliva develops. These lesions appear as highly pruritic red papules grouped about the waist, thighs, and legs that can persist for several weeks. Prevention of bites includes the use of a repellent such as DEET and tucking long trouser legs into stockings.

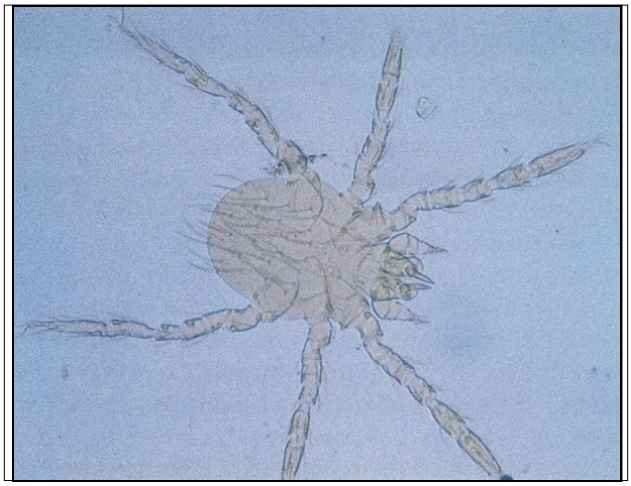

Fig. 8-25. A chigger is the larval form of mites belonging to the family Trombiculidae. It will attach to the host for 2 to 3 days, feeding on blood via a stylostome and producing highly pruritic papules on the legs, thighs, and waist. Some of the Trombiculidae are vectors for tsutsugamushi fever. Photograph: Courtesy of Entomology Department, Walter Reed Army Institute of Research, Washington, D.C.

Some of the Trombiculidae are vectors for scrub typhus or tsutsugamushi fever caused by *Rickettsia tsutsugamushi*. The primary host of these mites are field rats and, although they are probably not a reservoir of infection, the rats serve to maintain the mite population. As with the mite vector of rickettsialpox, *R tsutsugamushi* are passed transovarially to the larvae. The constitutional symptoms of scrub typhus, namely fever, chills, and intense headache, occur about 10 days after the bite. These symptoms are followed by an erythematous macular rash that starts on the trunk and extends peripherally, and a pneumonitis. At the site of the original bite, an indurated papule develops that becomes necrotic. Tetracycline (250 mg orally every 6 h for 14 d) is the treatment of choice.

Scorpions

Scorpions are large arachnids with an elongated abdomen that terminates in a stinger (Figure 8-26).[7] They have a pair of abdominal glands that release both neurotoxic and hemolytic venom into the stinger. The distribution of scorpions is worldwide, especially in the tropics. In the United States, the *Centruroides sculpturatus*, measuring 13 to 75 mm, is the most common stinging scorpion and is found in

Fig. 8-26. Scorpions have pincer claws, four pairs of legs, and an elongated abdomen that terminates in a stinger. In the United States they range in length from 1.5 to 7.5 cm. Photograph: Courtesy of Entomology Department, Walter Reed Army Institute of Research, Washington, D.C.

the Southwest.[29] Scorpions are nocturnal and hide during the daytime in dark places including closets, shoes, and under rocks and logs. They sting in self-defense, as when they are unwittingly stepped on. Immediately after the sting, the affected individual experiences pain and swelling at the site. The hemolytic venom usually produces little else, although in cases of severe envenomation, coagulopathy and cardiovascular symptoms may result. The neurotoxin, on the other hand, can cause a variety of symptoms including localized numbness, fasciculation, lacrimation, salivation, profuse sweating, urinary urgency, nausea, tongue paresthesia, restlessness, convulsions, and an increase in extraocular muscle activity. Anaphylaxis and death from cardiac or respiratory failure may occur, especially in children. Treatment of scorpion stings consists of first removing the stinger, then applying a tourniquet and cooling the site with ice. If available, specific antivenin should be administered. Barbiturates or diazepam can be given to control the central nervous system hyperactivity and convulsions. Atropine may be useful in blocking the cholinergic side effects of the neurotoxin. A variety of pesticides such as malathion and diazinon have been used to eradicate scorpions.

Spiders

Although spiders are notorious among the public as fierce and dangerous creatures and are hence feared (arachnephobia), in fact they are usually shy and tend to avoid contact with humans. Over 30,000 species of spiders have been identified, and yet fewer than 60 are of medical importance in the United States.[30] In this country, only the black widow spider (*Lactrodectus mactans*) and the brown recluse spider (*Loxosceles reclusa*) are known to cause death.[31] Worldwide, other potentially lethal spiders include the Australian funnel-web spider (*Atrax robustus* and *A formidabilis*), the South American banana spider (*Phoneutria fera*), and the South African *Harpactirella*.[4] Although almost all spiders are venomous, the overwhelming majority are unable even to penetrate human skin with their jaws. Those that can penetrate usually cause only minor local injury.

All spiders have a cephalothorax from which extend eight legs and an abdomen. A pair of jaws (chelicerae) are found at the anterior end of the cephalothorax. These jaws terminate in sharp, chitinized fangs from which venom is ejected. This pair of fangs produces the characteristic set of two small puncta found at the site of most spider bites. The venomous glands as well as the spider's multiple eyes (usually eight) are also located in the cephalothorax. On the ventral surface of the abdomen are the spinnerets, which release the web-forming silk. All spiders are carnivores, feeding primarily on insects.

Spiders can adapt to their local environment and live well in man-made structures and refuse. Webs may be found around old tires, garbage cans, outhouses, and lampposts.[32] Spiders are frequently encountered in woodpiles, junkyards, and cluttered attics and closets. They tend to relocate indoors when the weather becomes cold. Simple measures such as cleaning out closets and attics as well as maintaining woodpiles and refuse areas can discourage infestation by and contact with spiders.

Spiders can cause cutaneous and systemic injury in humans through a variety of different mechanisms. Most important is their venom, which can be either neurotoxic or dermonecrotic. These two types of venom are seen in the black widow and brown recluse, respectively, and will be discussed in more

detail below. Many species of tarantulas have hairs that produce urticaria when in contact with skin. Pet owners are the primary recipient of this dermatologic problem. The bite of most spiders, although inconsequential in terms of discomfort or cutaneous damage, may become secondarily infected, producing pustular, impetigenous, or cellulitic lesions. Finally, repeated spider bites can rarely cause allergic reactions including anaphylactic shock.

Brown Recluse Spider

The brown recluse spider (*Loxosceles reclusa*) has a yellow-to-brown cephalothorax and a tan abdomen. The species is identified by a dark brown, violin-shaped marking on the dorsal aspect of the cephalothorax (Figure 8-27). Its body ranges from 1 to 1.5 cm in length, with a leg span of over 2.5 cm. These shy, nocturnal hunting spiders are found throughout the continental United States, and a closely related species, *L laeta,* is found in South America. Within the United States, they are in greatest numbers in the south-central part of the country, preferring a warm, dry climate. They like protected places such as beneath rocks and boards or in animal burrows or caves where they spin small matted webs. In northern areas of the country, they are more frequently found indoors, in closets, attics, and garages. They avoid daylight and are not aggressive toward humans, attacking only when trapped or crushed against the skin.

Fig. 8-27. The brown recluse spider (*Loxosceles reclusa*) is 1 to 1.5 cm in length with a 2.5-cm leg span. Photograph: Courtesy of Entomology Department, Walter Reed Army Institute of Research, Washington, D.C.

Fig. 8-28. The bite of the brown recluse spider may produce full-thickness skin necrosis. This is usually preceded by a central area of blue-gray discoloration, a blanched halo from arterial spasm, and a large surrounding zone of reactive erythema. Photograph: Courtesy of Entomology Department, Walter Reed Army Institute of Research, Washington, D.C.

The venom from the brown recluse is more potent than that of a rattlesnake. Although different analyses of its contents have yielded conflicting results, the primary dermonecrotic factor appears to be a phospholipase, sphingomyelinase D. This interacts with and damages the plasma membrane of many cell types including erythrocytes, endothelial cells, and platelets. Other enzymes have been identified in the venom, such as alkaline phosphatase, hyaluronidase, collagenase, 5'-ribonucleotide phosphohydrolase, deoxyribonuclease, ribonuclease, and other proteases and esterases. These enzymes, as well as host factors including prostaglandins, leukotrienes, and complement, probably all play a role in the neutrophil chemotaxis, platelet aggregation, and tissue necrosis that occur as a result of the bite.

The clinical outcome of brown recluse spider bites varies widely, ranging from minor, inconsequential, cutaneous reactions to full-thickness skin necrosis and, in some instances, death (Figure 8-28). Multiple factors including host susceptibility, amount of venom injected, and location of the bite play a role in determining the extent of the reaction. Only 10% of patients develop a significant necrotic wound. The initial bite is often painless and unnoticed by the patient. Therefore, the spider is usually not seen and a brown recluse bite is suspected only on clinical grounds. Within 12 to 24 hours of the

bite, pain, erythema, violaceous mottling, swelling, induration, and blister or pustule formation may occur. A characteristic trizonal response takes place, with a central blue-gray area due to thrombosis, a blanched halo from arterial spasm, and a large surrounding area of reactive erythema. In the absence of any of these changes, the patient usually will not develop significant tissue necrosis. Once these changes are seen, however, there is often progression to eschar formation, dermal necrosis, and stellate ulceration. Healing is slow, in severe cases taking up to 6 months. Systemic symptoms include headache, fever, malaise, and arthralgias. A generalized maculopapular rash may be associated with the cutaneous changes. A much more severe systemic reaction due to hemolysis is a rare complication seen primarily in children, who may present with disseminated intravascular coagulation, hemoglobinuria with acute renal failure, convulsions, coma, and death. Patients with significant cutaneous necrosis (> 1 cm) should be tested for progressive hemolytic anemia.

The therapy for brown recluse spider bites has evolved but still remains somewhat controversial. Elements of immediate care include immobilization and elevation of the affected site and the application of ice compresses: the enzymes in the venom are rendered less active with a decrease in temperature. Tetanus toxoid should be administered, if indicated, and analgesics may be necessary. Intralesional injection of corticosteroid (triamcinolone, 25 mg) helps to relieve pain and reduce inflammation.[33] Early excision of the bite site was previously recommended, but this procedure may actually extend tissue damage and delay wound healing. Systemic corticosteroids do not seem to prevent or lessen the cutaneous necrosis but may be beneficial for the systemic manifestations. Dapsone (4,4'-diaminodiphenylsulfone), 100 mg daily, is effective in limiting the cutaneous necrosis; however, this drug must be used with care because it causes hemolysis, most notably in patients deficient in glucose-6-phosphate dehydrogenase. Wound excision and skin grafting should be considered only after the eschar has delineated itself and the wound is no longer enlarging. Systemic antibiotics may be necessary to treat secondary wound infection.

Black Widow Spider

Of the five species of *Latrodectus* found in the United States, *L mactans*, or the black widow, is the most common and has the widest distribution. These spiders are found from the South to southern New England. Only the female of the species is capable of envenomating humans. They are jet black with a globose abdomen that has the characteristic red hourglasslike marking on the ventral surface (Figure 8-29). Measuring up to 1.5 cm in length with a 4-cm leg span, black widow spiders prefer a warm, dry environment and can be found both outdoors and inside buildings. The large, strong webs they spin are generally placed close to the ground in protected places like rodent burrows, under stones and logs, in the angles of doors and windows, and in cluttered areas such as dumps, garages, sheds, and outhouses. Although black widows will not aggressively attack humans, they bite when a person inadvertently comes in contact with the web. A notorious and not infrequent scenario is the biting of male genitalia by a black widow spider whose web is located beneath an outhouse seat.



Fig. 8-29. The black widow spider (*Lactrodectus mactans*) has a body measuring up to 1.5 cm long, with a leg span up to 4 cm. Its black abdomen has a red hourglasslike marking on the ventral surface. Photograph: Courtesy of Entomology Department, Walter Reed Army Institute of Research, Washington, D.C.

The black widow's venom is a potent neurotoxin composed of proteins, lipids, and carbohydrates. One or more components of this venom bind to the synaptic membranes of nerve terminals, causing the release of large amounts of acetylcholine, catecholamines, or both at the neuromuscular junctions. Re-uptake of the neurotransmitters is also blocked and they are subsequently depleted. Motor nerves, as well as sympathetic and parasympathetic nerves, are affected by this toxin, explaining most of the signs and symptoms of black widow envenomation. This venom, unlike that of the brown

recluse spider, causes little local damage and no necrosis at the site of the bite.

The actual bite of the black widow is often perceived as a sharp pinprick. Two tiny red puncta are usually visible at the site. Mild erythema and edema then ensue, accompanied by a dull ache and numbness that spread from the inoculation site to the torso and, in some cases, the entire body. The systemic symptoms begin within an hour, peak at 1 to 6 hours, and can last 1 to 2 days. Severe myalgias and muscle cramping develop, first regionally, then in a general distribution. In the majority of victims, the abdominal musculature is involved and may simulate an acute surgical abdomen. Other systemic signs and symptoms include headache, restlessness, anxiety, fatigue, insomnia, diaphoresis, salivation, lacrimation, nausea, vomiting, tremors, fasciculation, paresthesias (burning of the plantar surface is characteristic), respiratory distress, shock, and coma. Patients have a characteristic facies that is grimaced, flushed, and diaphoretic, with accompanying blepharoconjunctivitis.[34] Although death from a black widow bite is extremely rare in an adult, it can occur in up to 50% of young children if left untreated.[31]

In the treatment of black widow spider bites, hospitalization should be considered for children, the elderly, those with underlying cardiac or pulmonary disease, or victims displaying severe systemic signs and symptoms. If the patient has no history of sensitivity to horse serum and exhibits severe systemic involvement, *L mactans* antivenin can be given. One ampule containing 2.5 mL, given intravenously or intramuscularly, will relieve most symptoms within 1 to 2 hours. Analgesia can sometimes be obtained with aspirin or acetaminophen, but in severe cases requires narcotics. Muscle relaxants and intravenous calcium gluconate have also been advocated.

Tarantulas

Tarantulas are the largest of all spiders and belong to the family Theraphosidae (Figure 8-30). The name "tarantula" is actually a misnomer and properly belongs to the much smaller but equally hairy wolf spider found in Europe. In the United States, tarantulas are found throughout the Southwest, where they live in burrows during the day and hunt at night. Their leg span can reach 15 to 18 cm. Although the appearance of these large, hairy spiders is formidable, they are usually not harmful to humans. They will bite only after significant provocation. Even then, their bite produces only temporary pain without accompanying tissue damage. However, when threatened, tarantulas may flick some of their hair toward an aggressor. These hairs can penetrate the skin and cause a pruritic urticarial dermatitis that lasts several days. This reaction can be treated with topical corticosteroids and oral antihistamines or, if severe, with a brief course of systemic corticosteroids.

Fig. 8-30. Tarantulas are hairy spiders whose leg spans can measure up to 18 cm. Despite their intimidating appearance, they are usually not harmful to humans, biting only after significant provocation. Photograph: Courtesy of Entomology Department, Walter Reed Army Institute of Research, Washington, D.C.

Chiracanthium

The genus *Chiracanthium* includes the common garden spider and the common house spider. These spiders are green to brown and vary in length from 7 to 10 mm. They possess a venom that is similar to that of the brown recluse but inject a much smaller volume and, therefore, produce much less tissue damage. Bites occur most frequently at night on exposed parts of the body. The initial bite is usually painful, and a crusted, necrotic lesion can develop within several days. Surrounding erythema and induration are often seen. Occasionally, pain extends far beyond the site of the bite, suggesting a neurotoxin. Treatment includes immobilization and elevation of the site, tetanus prophylaxis, and analgesics. Antibiotics may be necessary for secondary infection.

REPTILES

A number of reptiles are capable of inflicting significant bite wounds if provoked, and some species pose the additional threat of envenomation. Among the dangerous reptiles that humans may encounter are poisonous snakes and Gila monsters.

Snakes

Venomous snakes can be encountered throughout the world. In the United States, the rattlesnake, cottonmouth moccasin, and copperhead, all belonging to the family Crotalidae, or pit vipers, account for the vast majority of bites. These pit vipers are found most frequently in the Southeast and Southwest. Other dangerous vipers found in Europe, North Africa, the Middle East, and Asia include the Leventine viper, the puff adder, and a variety of horned desert vipers and carpet vipers. Coral snakes, found in the southern United States, are members of the family Elapidae (including cobras, mambas, and kraits), and are responsible for less than 2% of all poisonous snake bites.[35] Although an estimated 45,000 people are bitten by snakes each year in this country, only 20% of these bites involve venomous snakes and fewer than 12 result in death.[35] Most fatalities are caused by rattlesnakes.

All the pit vipers bite with hollow fangs through which their venom is discharged.[36] Snake venom contains nearly 30 enzymes, most of which are hydrolases. An anticoagulant in the venom causes hemolysis and capillary leakage. Other components include neurotoxic, myotoxic, and cardiotoxic substances.

A wide variety of signs and symptoms may result from a snake bite and accompanying envenomation. Pain, edema, ecchymosis, vesiculation, petechiae, and tissue necrosis can develop at the site of the bite. Systemic manifestations include weakness, diaphoresis, nausea, vomiting, diarrhea, abdominal pain, dysesthesias, headache, fasciculation, hemorrhage, myonecrosis, and shock. Rarely, allergic reactions may be seen in individuals who handle and are repeatedly bitten by snakes.

Therapy for a venomous snake bite should initially consist of the first-aid measures of immobilization, maintenance of vital signs, and prompt transportation to a medical treatment facility. A tourniquet tightened only enough to impede superficial venous and lymphatic flow can be applied proximally to the fang marks. The use of local ice packs should be avoided, for unlike brown recluse spider bites, tissue damage can actually be increased by this maneuver. Incising the wound and attempting to remove venom by suction is also discouraged because it does little more than delay prompt transportation. Every attempt should be made to identify the snake involved.

Once the snake-bitten patient is hospitalized, an evaluation for hemolysis and myonecrosis should include blood and platelet counts, coagulation studies, and urinalysis. If there is symptomatology or laboratory evidence of envenomation, Antivenin Polyvalent (manufactured by Wyeth-Ayerst Laboratories, Philadelphia, Pa.) should be administered via intravenous drip. Antivenin is available for both pit viper and coral snake bites. Antivenins for some other species of poisonous snakes can be obtained from the Oklahoma City Poison Control Center (405-271-5454). Prior to initiation of therapy, the patient should be skin-tested for hypersensitivity to horse serum because anaphylaxis may occur. Other adverse reactions include fever and serum sickness. Tetanus prophylaxis, analgesics, and appropriate antibiotic coverage for secondary infection are all often indicated. Surgical debridement of necrotic tissue should be done only after the patient is stabilized with normal coagulation parameters.

Gila Monsters

Gila monsters are venomous lizards found in the southwestern United States.[35,37] They are large, sluggish creatures that will bite humans only when attempts are made to capture or handle them. Once provoked, however, their bite can be both strong and tenacious. Their venom contains phospholipase A, protease, hyaluronidase, and a kinin-releasing factor. If envenomation occurs, the victim may experience sharp local pain and accompanying edema. Other symptoms include weakness, dizziness, tinnitis, fasciculation, nausea, vomiting, and hypotensive shock. Therapy consists, foremost, of removing the lizard from the victim. The Gila monster's jaws are powerful, and a chisel or crowbar may be required to pry them open. The wound

is then irrigated with lidocaine and probed for broken tooth fragments. Tetanus prophylaxis, analgesics, and antibiotic coverage may all be necessary. The victim should be monitored for hypotension and treated accordingly with intravenous fluids. No antivenin is available.

CATS AND DOGS

Every year, an estimated 1 to 2 million dog bites and 400,000 cat bites are reported in the United States.[38] These injuries account for about 1% of all emergency room visits. Although most wounds are trivial, requiring little or no medical care, serious complications such as cellulitis, osteomyelitis, septic arthritis, and sepsis can occur. The hands and face are frequent sites for bites. The wound inflicted can be a scratch or puncture, but more severe injuries such as avulsions or crush injuries with tissue necrosis may be seen. The risk of wound infection increases with (*a*) victims older than 50 years of age, (*b*) immunosuppressed victims, (*c*) puncture wounds or crush injury, (*d*) bites to dependent areas, and (*e*) wounds that have not been promptly irrigated. Although approximately 85% of bite wounds will contain pathogenic bacteria, only 2% to 30% of patients with bites will develop wound infections. A wide variety of bacteria can be involved in wound infections, including both aerobic and anaerobic organisms. *Pasteurella multocida* is found in 20% to 25% of dog-bite wounds and 50% of cat-bite wounds.

Initially, a dog or cat bite should be promptly cleansed, liberally irrigated, and debrided of any devitalized tissue,[39] and tetanus toxoid should be administered. The affected area should be bandaged, elevated, and immobilized. Culturing the initial wound is generally not helpful either in predicting subsequent infection or in identifying the causative organism if infection should develop. Rather, aerobic and anaerobic cultures should be taken only after evidence of infection is present, with definitive antibiotic therapy guided by in vitro sensitivity assays. Initial empirical therapy should provide coverage against *P multocida*, *Staphylococcus aureus*, streptococci, Centers for Disease Control alphanumeric bacteria (eg, DF-2, EF-4), and anaerobic bacteria. Although penicillin (250 mg orally every 6 h for 10 d) has been the standard treatment, it provides poor coverage of *S aureus*, and a broader-spectrum agent such as amoxicillin-clavulanic acid (250 mg orally every 8 h for 10 d) should be considered. Doxycycline and minocycline (each at 100 mg orally every 12 h for 10 d) are good alternatives for penicillin-allergic individuals. In the absence of clinical infection, consideration should be given for empirical antibiotic therapy of severe wounds, crush injuries, puncture wounds, and wounds involving the hands, joints, or bones. Suturing of laceration wounds is controversial and is probably best reserved for clinically uninfected wounds treated less than 12 hours after the bite. Some authorities recommend initial approximation with adhesive strips and delayed closure.[38] Rabies vaccine (prophylactic, not therapeutic) should be considered if the bite is produced by an unknown domestic animal or a wild animal in which rabies is endemic.

SUMMARY

Arthropods compose the largest phylum and have a worldwide distribution. Bites and stings inflicted by arthropods may cause significant morbidity in the military operational environment. Any break in the skin may serve as a portal of infection, especially in a humid tropical setting. The scratching that follows many arthropod bites further compromises the skin integrity; cutaneous pyodermas have been a significant cause of hospitalization during past military conflicts. Severe systemic reactions including anaphylaxis may result from a bite or sting. Arthropods also serve as the vectors for a number of infectious diseases, a topic covered in Chapter 9, Arthropod Infestations and Vectors of Disease, and Chapter 11, Rickettsial Diseases. It therefore behooves the medical officer to become familiar with the arthropods found in his or her geographical setting.

Specific therapy exists for those arthropods taking up residence on the human skin such as scabies and lice. Topically applied insecticides such as 1% lindane and 5% permethrin will eradicate the organisms. In the majority of cases where the arthropod is only in contact with the skin long enough to bite or sting, the treatment is symptomatic, aimed at relieving pain and pruritus. A variety of methods exist for preventing arthropod bites.

General public health measures include separating livestock, wood piles, and latrine and garbage sites from living quarters. Doors and windows may be fitted with mesh netting and the floors elevated from the ground. Protective clothing reduces exposed skin. Insecticides such as malathion and the pyrethroids may be sprayed or powdered in living quarters and on furniture. Finally, a number of repellents are available for both topical application and impregnation in clothing. One of the best repellent combinations appears to be topically applied DEET and permethrin-impregnated clothing.

Although most cat and dog bites are minor and require little or no medical care, they are a frequent cause of visits to the emergency room, and infection can arise without prompt wound cleaning and administration of antibiotics. Wounds inflicted by poisonous reptiles, although less common than cat and dog bites, can have serious consequences and require immediate first-aid treatment. Gila monsters have powerful jaws, and sometimes a crowbar is required to pry them from the victim; patients should then be monitored for hypotension. In the event of a poisonous snake bite, it is important to identify the variety of snake so that the proper antivenin can be administered.

REFERENCES

1. MacPherson WG, Horrocks WH, Beveridge WWO. *History of the Great War, Medical Services, Hygiene of the War.* Vol 2. London, England: His Majesty's Stationery Office, 1923: 327–340.

2. Pillsbury DM, Livingood CS. Dermatology. In: Havens WP, ed. *Infectious Diseases and General Medicine*. In: Havens WP, Anderson RS, eds. *Internal Medicine in World War II*. Vol 3. Washington, DC: Medical Department, US Army, Office of The Surgeon General; 1968: 543–673.

3. Allen AM. *Skin Diseases in Vietnam, 1965–72*. In: Ognibene AJ, ed. *Internal Medicine in Vietnam.* Vol 1. Washington, DC: Medical Department, US Army, Office of The Surgeon General and Center of Military History; 1977: 59–139.

4. Alexander JO. *Arthropods and Human Skin*. Berlin, Germany: Springer-Verlag; 1984: 3–9, 117, 364, 399–408.

5. Mellanby K. Man's reaction to mosquito bites. *Nature.* 1946;158:554.

6. Burnett JW, Calton GJ, Morgan RJ. Centipedes. *Cutis*. 1986;37:241.

7. Arnold HL, Odom RB, James WD. *Andrew's Diseases of the Skin*. Philadelphia, Pa: WB Saunders Company; 1990: 486–533.

8. Burnett JW, Calton GJ, Morgan RJ. Caterpillar and moth dermatitis. *Cutis*. 1986;37:320.

9. Rosen T. Caterpillar dermatitis. *Dermatol Clinics.* 1990; 8:245–252.

10. Burnett JW, Calton GJ, Morgan RJ. Bedbugs. *Cutis.* 1986;38:20.

11. Burnett JW, Calton GJ, Morgan RJ. *Triatoma*: The "kissing bug." *Cutis*. 1987;39:399.

12. Elgart ML. Pediculosis. *Dermatol Clinics*. 1990;8:219–228.

13. Meinking TL, Taplin D, Kalter DC, et al. Comparative efficacy of treatments for pediculosis capitis infestations. *Arch Dermatol*. 1986;122:267–271.

14. Elgart ML. Flies and myiasis. *Dermatol Clinics*. 1990;8:237–244.

15. Brown AWA. The attraction of mosquitoes to hosts. *JAMA*. 1966;196:159–162.

16. Kurgansky D, Burnett JW. Diptera mosquitoes. *Cutis*. 1988;41:317–318.

17. Burnett JW. Myiasis. *Cutis*. 1990;46:51–52.

18. Burnett JW, Calton GJ, Morgan RJ. Blister beetles: "Spanish fly." *Cutis*. 1987;40:22.

19. Gayer KD, Burnett JW. Hymenoptera stings. *Cutis*. 1988;41:93–94.

20. Elgart GW. Ant, bee, and wasp stings. *Dermatol Clinics*. 1990;8:229–236.

21. Schorr WF, Tauscheck AL, Dickson KB, Melski JW. Eosinophilic cellulitis (Wells' syndrome): Histological and clinical features of arthropod bite reactions. *J Am Acad Dermatol*. 1984;11:1043–1049.

22. Ross EV, Badame AJ, Dale SE. Meat tenderizer in the acute treatment of imported fire ant stings. *J Am Acad Dermatol*. 1987;16:1189–1192.

23. Modly CE, Burnett JW. Tick-borne dermatologic diseases. *Cutis*. 1988;41:244–246.

24. Elgart ML. Scabies. *Dermatol Clinics*. 1990;8:253–263.

25. Mellanby K. Biology of the parasite. In: Orkin M, Maibach HI, Parish LC, Schwartzman RM, eds. *Scabies and Pediculosis*. Philadelphia, Pa: JB Lippincott, 1977.

26. Lindane, a prudent approach. *Arch Dermatol*. 1987;123:1008–1010. Editorial.

27. Taplin D, Meinking TL, Porcelain SL, et al. Permethrin 5% dermal cream: A new treatment for scabies. *J Am Acad Dermatol*. 1986;15:995–1001.

28. Blankenship ML. Mite dermatitis other than scabies. *Dermatol Clinics*. 1990;8:265–275.

29. Burnett JW, Calton GJ, Morgan RJ. Scorpions. *Cutis*. 1986;36:393.

30. Wilson DC, King LE. Spiders and spider bites. *Dermatol Clinics*. 1990;8:277–286.

31. Wong RC, Hughes SE, Voorhees JJ. Spider bites. *Arch Dermatol*. 1987;123:98–104.

32. Spider bites. *Arch Dermatol*. 1987;123:41–43. Editorial.

33. Burnett JW, Calton GJ, Morgan RJ. Brown recluse spider. *Cutis*. 1985;36:197–198.

34. Burnett JW, Calton GJ, Morgan RJ. Lactrodectism: Black widow spider bites. *Cutis*. 1985;36:121.

35. McKoy KC, Moschella SL. Parasites, arthropods, hazardous animals, and tropical dermatology. In: Moschella SL, Hurley HJ, eds. *Dermatology*. Philadelphia, Pa: WB Saunders Company; 1985: 1731–1820.

36. Burnett JW, Calton GJ, Morgan RJ. Venomous snakebites. *Cutis*. 1986;38:299–300.

37. Burnett JW, Calton GJ, Morgan RJ. Gila monster bites. *Cutis*. 1985;35:323.

38. Goldstein EJC. Management of human and animal bite wounds. *J Am Acad Dermatol*. 1989:21:1275–1279.

39. Burnett JW. Bite wounds. *Cutis*. 1990;45:287.